Bioarchaeological Reports on Human Skeletal Remains from Iowa and Other Proveniences

Edited by
Jennifer E. Mack
Bioarchaeologist
and
Lara K. Noldner
Bioarchaeology Program Director

Research Papers

Volume 47 Number 1
Office of the State Archaeologist
The University of Iowa

Iowa City
2022

Research Papers

The Office of the State Archaeologist is headquartered at The University of Iowa, Iowa City, Iowa 52242. The Office issues three professional series, each having a separate function. Complete listings can be obtained by contacting the State Archaeologist.

Reports, books and monographs issued at intervals in printed or digital form, are considered to be complete studies of permanent value.

Contract Completion Reports provide permanent documentation for highway surveys and other cultural resource investigations.

Research Papers provide permanent access to osteological and archaeological studies which are not intended for publication in regional or national anthropological journals. It is anticipated that these reports will provide the data base for various publications in future years. The series can be consulted at the following institutions which serve as permanent repositories.

Iowa:	University of Iowa Library, Government Documents, Iowa City
	Iowa State University, Department of Anthropology, Ames
	Luther College, Department of Anthropology, Decorah
	Effigy Mounds National Monument, Harpers Ferry
	State Historical Society, Historic Preservation, Des Moines
	State Historical Society, Library and Archives, Des Moines
	State Historical Society, Library, Iowa City
	Depository Library Center, State Library of Iowa, Des Moines
	University of Northern Iowa Library, Cedar Falls
Illinois:	Illinois Historic Preservation Agency, Springfield
	Illinois State Museum Research and Collections Center Library, Springfield
	Illinois Transportation Archaeological Research Program, Urbana
	Western Illinois University, Archaeological Research Lab, Macomb
Minnesota:	Minnesota Historical Society, Library, St. Paul
	State Archaeologist's Office, St. Paul
Missouri:	University of Missouri, Missouri Archeological Society, Columbia
	State Archaeologist, Office of Historic Preservation, Jefferson City
Nebraska:	University of Nebraska State Museum, Lincoln
	Midwest Archeological Center, National Park Service, Lincoln
South Dakota:	South Dakota State Historical Society, Pierre
	South Dakota Archaeological Research Center, Rapid City
	University of South Dakota, Department of Anthropology, Vermillion
Wisconsin:	State Historical Society of Wisconsin, Library, Madison
	State Historical Society of Wisconsin, State Archaeologist, Madison

Research Papers serve as an outlet for the preservation of archival information on Iowa archaeology and related studies. Authors wishing to submit reports for possible inclusion should contact the State Archaeologist

Table of Contents

Osteological Methods 1

Osteological References 2

A Human Mandible Recovered from a Sandbar (13CA79) in the East Nishnabotna River, Cass County, Iowa. 7
Jennifer E. Mack

A Human Tooth from the Phipps Site (13CK21), Cherokee County, Iowa 11
Jennifer E. Mack

Human Skeletal Remains Recovered from 13CK98, Cherokee County, Iowa 13
Jennifer E. Mack

Human Skeletal Remains Excavated from 13DB40 and 13DB1140, Dubuque County, Iowa, and Richards Mound Group in Grant County, Wisconsin 23
Jennifer E. Mack

Human Remains Recovered from 13DK96, a Woodland Occupation Site in Dickinson County, Iowa 49
Jennifer E. Mack

Amputated Lower Leg Recovered from an Old City Dump, Battle Creek, Ida County, Iowa 51
Jennifer E. Mack

Human Remains Exposed by Rodent Burrowing at the Sayers/Athey Cemetery (13IW367), Iowa County, Iowa 57
Lara K. Noldner

Summary Report of Human Remains Recovered from Woodpecker Cave, 13JH202, in Johnson County, Iowa, during Archaeological Field School Excavations, 2012–2017 65
Jennifer E. Mack

Human Remains Disturbed During Derecho Tree Damage Clean-up in Oak Hill Cemetery, Cedar Rapids, Linn County, Iowa 71
Jennifer E. Mack

Additional Human Remains Collected from an Eroding Landform at Blood Run National Historic Landmark (13LO2), Lyon County, Iowa 75
Jennifer E. Mack

A Deciduous Human Tooth Discovered with Faunal Remains from 13ML139 in Mills County, Iowa 79
Jennifer E. Mack

A Partial Cranium Found in the Cedar River (13MC350) in Muscatine County, Iowa 81
Jennifer E. Mack

Disturbed Human Skeletal Remains Recovered from an Earthen Dam in Muscatine, Iowa 85
Jennifer E. Mack

Isolated Skeletal Remains from The Wittrock Site (13OB4), O'Brien County, Iowa 93
Jennifer E. Mack

A Human Cranium Found on a Sandbar in the East Nishnabotna River, Page County, Iowa (13PA124). 97
Jennifer E. Mack

Maxillary Molar Recovered from Historic Trash Deposit (13PA126) in Page County, Iowa 101
Jennifer E. Mack

A Human Tooth Recovered from 13PK38 in Polk County, Iowa. 103
Jennifer E. Mack

Commingled Human Remains Recovered from a Flood-damaged Mill Creek Village (13PM7) in Plymouth County, Iowa 105
Jennifer E. Mack and Lara Noldner

A Human Molar Recovered from 13PM62, a Great Oasis Village in Plymouth County, Iowa 123
Jennifer E. Mack

Human Skeletal Remains Disturbed in Lewis Township Cemetery, Pottawattamie County, Iowa . . . 125
Jennifer E. Mack

Human Cranium Discovered During Road Construction near Fairview Cemetery, Council Bluffs, Pottawattamie County, Iowa 129
Jennifer E. Mack

Human Cranial Fragment Recovered ca. 1957 from the Correctionville Site (13WD6), Woodbury County, Iowa 137
Jennifer E. Mack

Human Cranial Remains Discovered in the Little Sioux River (13WD232) in Woodbury County, Iowa. 139
Jennifer E. Mack

Human Remains of Unknown Provenience Transferred to Bioarchaeology Program in 2016 141
Jennifer E. Mack

A Human Tooth Discovered at the Sanford Museum in Cherokee County, Iowa 147
Jennifer E. Mack

Probable Native American Cranium from an Anatomical Collection, University of Iowa, Office of the State Archaeologist. 149
Jennifer E. Mack

Human Skeletal Remains from Iowa, Formerly in Kansas State University Collections 155
Jennifer E. Mack

A Human Cranium from the Library Archives of Des Moines University, Polk County, Iowa. 165
Jennifer E. Mack

Human Skeletal Remains from Unknown Archaeological Context, Donated by Sidney High School, Fremont County, Iowa 171
Jennifer E. Mack

Fragmentary Human Skeletal Remains from Richardson and Nance Counties, Nebraska 173
Jennifer E. Mack

A Human Femoral Fragment from St. Augustine, Florida 175
Jennifer E. Mack

Two Anatomical Specimens from Norway, Benton County, Iowa. 177
Jennifer E. Mack

Cranial Remains of a Purported Homicide Victim from Newton, Jasper County, Iowa 181
Jennifer E. Mack

Osteological Methods

The osteological analyses follow the guidelines developed by the Paleopathology Association (PA) (Buikstra and Ubelaker 1994). Complete, partial, and commingled remains are inventoried in the Office of the State Archaeologist Bioarchaeology Program's osteodatabase, which utilizes the Access database developed by staff at the Maxwell Museum of Anthropology, University of New Mexico. Cranial metrics are collected utilizing methods in Moore-Jansen et al. (1994). Cranial nonmetric observations are recorded based on definitions in Finnegan (1972), El-Najjar and McWilliams (1978), and Hauser and De Stefano (1989), using coding provided in the osteodatabase. Postcranial metrics are taken following Moore-Jansen et al. (1994). Postcranial nonmetric traits are scored using the definitions in Finnegan (1978) and Saunders (1978).

Sex is estimated based on morphological characteristics of the cranium (Acsadi and Nemeskeri 1970) and os coxae (Buikstra and Ubelaker 1994; Milner 1992; Phenice 1969), as well as sexually dimorphic postcranial metrics defined in Bass (1995) and Steele (1976). Age estimates are based on one or more of the following methods: relative dental attrition (for broad age ranges); dental development (AlQahtani et al. 2010); cranial suture closure (Buikstra and Ubelaker 1994); palatal suture closure (Mann et al. 1991); changes in sternal rib ends (Işçan and Loth 1986); changes in the face of the pubic symphysis (Suchey and Katz 1986; Brooks and Suchey 1990); changes in the auricular surface of the os coxa (Lovejoy et al. 1985; Meindl and Lovejoy 1989); skeletal maturation (Cunningham et al. 2016; White et al. 2012); skeletal epiphyseal closure (Cunningham et al. 2016; Schaefer et al. 2009); subadult diaphyseal length and ilium breadth (Cunningham et al. 2016; Schaefer et al. 2009; Ubelaker 1989); the presence or absence of age-related osteological changes (White et al. 2012); and comparison with confidently-aged subadult remains in the OSA comparative collection.

Biological affinity is evaluated through examination of nonmetric cranial and dental characteristics (Byers 2008; Edgar 2015; Irish 2105; White et al. 2012). When possible, analysis of metric data using FORDISC 3.1 (Jantz and Ousley 2005) provides estimations of both biological affinity and sex.

Dental remains are inventoried, and dental pathologies are recorded according to the system in Buikstra and Ubelaker (1994). Dental attrition is scored using the coding method developed by Scott (1979) and Smith (1984). Dental metrics are taken using the guidelines and landmarks defined by Hillson et al. (2005), Mayhall (1992), and Moorees (1957). Dental morphology is scored using the Arizona State University Dental Anthropology System (Edgar 2017; Turner et al. 1991). Enamel hypoplastic defects are measured using the procedures outlined by Goodman and Rose (1990) and Goodman (1991).

Descriptions and interpretations of pathological conditions utilize Buikstra (2019), Ortner (2003), and Mann and Murphy (1990), as well as sources specified in individual reports. Stature is estimated using long bone length formulae developed by Trotter (1970) for non-Native American remains. Prehistoric Native American stature is estimated using Auerbach and Ruff (2010) for lower limb bones and Sciulli and Hetland (2007) for upper limb bones or combinations of elements. When applicable, stature is reconstructed for complete remains following Raxter et al. (2006). Some descriptions of cranial deformation utilize categories defined by Neumann (1942). For commingled remains, the Minimum Number of Individuals is calculated by landmark coding using the procedures outlined in Mack et al. (2016).

Osteological References

Acsádi, Gyorgy and Janos Nemeskéri
1970 History of Human Life Span and Mortality. Akadémiai Kiadó, Budapest.

AlQahtani, Sakher J., Mark P. Hector, and Helen M. Liversidge
2010 Brief Communication: The London Atlas of Human Tooth Development and Eruption. *American Journal of Physical Anthropology* 142:481–490.

Auerbach, Benjamin M. and Christopher B. Ruff
2010 Stature Estimation Formulae for Indigenous North American Populations. *American Journal of Physical Anthropology* 141:190–207.

Bass, William M.
1995 *Human Osteology: A Laboratory and Field Manual*. 4th ed. Special Publication No. 2. The Missouri Archaeological Society, Columbia.

Brooks, Sheilagh T. and Judy M. Suchey
1990 Skeletal Age Determination Based on the Os Pubis: A Comparison of the Acsadi-Nemeskeri and Suchey-Brooks Methods. *Human Evolution* 5:227–238.

Buikstra, Jane E., editor
2019 *Ortner's Identification of Pathological Conditions in Human Skeletal Remains*, Third Edition. Academic Press, London.

Buikstra, Jane E. and Douglas H. Ubelaker
1994 *Standards for Data Collection from Human Skeletal Remains*. Arkansas Archeological Survey Research Series No. 44, Fayetteville.

Byers, Steven, N.
2008 *Introduction to Forensic Anthropology*. 3rd edition, Pearson Education, Inc., Boston, Massachusetts.

Cunningham, Craig, Louise Scheuer, and Sue Black
2016 *Developmental Juvenile Osteology*. Academic Press, London.

Edgar, Heather J.H.
2015 Dental Morphological Estimation of Ancestry in Forensic Context. In *Biological Affinity in Forensic Identification of Human Skeletal Remains: Beyond Black and White*, edited by Gregory E. Berg and Sabrina C. Ta'ala, pp. 191-207. CRC Press, Boca Raton, Florida.
2017 *Dental Morphology for Anthropology: An Illustrated Manual.* Routledge, New York.

El-Najjar, Mahmoud Y. and K. Richard McWilliams
1978 *Forensic Anthropology*. Charles C. Thomas, Springfield, Illinois.

Finnegan, Michael
1972 Population Definition on the Northwest Coast by Analysis of Discrete Character Variation. Ph.D. dissertation. University of Colorado.

Finnegan, Michael
1978 Non-metric Variation of the Infracranial Skeleton. *Journal of Anatomy* 125:23–37.

Goodman, Alan H.
1991 Stress, Adaptation, and Enamel Developmental Defects. In *Human Paleopathology: Current Syntheses and Future Options*, edited by D.J. Ortner and A.C. Aufderheide, pp. 280–287. Smithsonian Institution Press, Washington, D.C.
Goodman, Alan H. and Jerome C. Rose
1990 Assessment of Systemic Physiological Perturbations From Dental Enamel Hypoplasias and Associated Histological Structures. *Yearbook of Physical Anthropology* 33:59–110.
Hauser, Gertrud and Gain Franco De Stefano
1989 Epigenetic Variants of the Human Skull. Schweizerburt, Stuttgart.
Hillson, Simon, Charles FitzGerald, and Helen Flinn
2005 Alternative Dental Measurements: Proposals and Relationships with Other Measurements. *American Journal of Physical Anthropology* 126:413–426.
Irish, Joel D.
2015 Dental Nonmetric Variation around the World: Using Key Traits in Populations to Estimate Ancestry in Individuals. In *Biological Affinity in Forensic Identification of Human Skeletal Remains: Beyond Black and White*, edited by Gregory E. Berg and Sabrina C. Ta'ala, pp. 165-190. CRC Press, Boca Raton, Florida.
Işcan, Mehmet Y. and Susan R. Loth
1986 Estimation of Age and Determination of Sex from the Sternal Rib. In *Forensic Osteology: Advances in the Identification of Human Remains,* edited by Kathy Reichs, pp. 68–89. Charles C. Thomas, Springfield, Illinois.
Jantz, Richard and Steve Ousley
2005 FORDISC 3.1 Personal Computer Forensic Discriminant Functions.
Lewis, M.E.
2004 Endocranial Lesions in Non-adult Skeletons: Understanding their Aetiology. *International Journal of Osteoarchaeology* 14:82–97.
Lovejoy, C. Owen, Richard S. Meindl, T. R. Pryzbeck, and Robert P. Mensforth
1985 Chronological Metamorphosis of the Auricular Surface of the Ilium: A New Method for the Determination of Adult Skeletal Age at Death. *American Journal of Physical Anthropology* 68:15–28.
Mack, Jennifer E., Anna J. Waterman, Ana-Monica Racila, Joseph A. Artz, and Katina T. Lillios
2016 Applying Zooarchaeological Methods to Interpret Mortuary Behavior and Taphonomy in Commingled Burials: The Case Study of the Late Neolithic Site of Bolores, Portugal. *International Journal of Osteoarchaeology* 26:524–536.
Mann, Robert W. and David R. Hunt
2005 *Photographic Regional Atlas of Bone Disease*. 2nd edition. Charles C. Thomas, Springfield, Illinois.
Mann, Robert W., Richard L. Jantz, William M. Bass, and Patrick S. Willey
1991 Maxillary Suture Obliteration: A Visual Method for Estimating Skeletal Age. *Journal of Forensic Sciences* 36: 781–791.
Mayhall, John T.
1992 Techniques for the Study of Dental Morphology. In *Skeletal Biology of Past Peoples: Research Methods,* edited by Shelley Saunders and M. A. Katzenberg, pp. 59–78. Wiley-Liss, New York.

Meindl, Richard S. and C. Owen Lovejoy
1985 Ectocranial Suture Closure: A Revised Method for the Determination of Skeletal Age at Death and Blind Tests of Its Accuracy. *American Journal of Physical Anthropology* 68:57–66.
1989 Age Changed in the Pelvis: Implications for Paleodemography. In *Age Markers in the Human Skeleton,* edited by Mehmet Y. Işcan, pp. 137–168. Charles C. Thomas, Springfield, Illinois.
Milner, George R.
1992 Determination of Skeletal Age and Sex: A Manual Prepared for the Dickson Mounds Reburial Team. Manuscript on file, Dickson Mounds Museum, Lewiston, Illinois.
Moore-Jansen, Peer H., Stephen D. Ousley, and Richard L. Jantz
1994 *Data Collection Procedures for Forensic Skeletal Material*. Report of Investigations No. 48, Department of Anthropology, The University of Tennessee, Knoxville.
Moorees, Coenraad F. A.
1957 The Aleut Dentition: A Correlative Study of Dental Characteristics in an Eskimoid People. Harvard University Press, Cambridge, Massachusetts.
Neumann, Georg K.
1942 Types of Artificial Cranial Deformation in the Eastern United States. *American Antiquity* 7:306–310.
Ortner, Donald J.
2003 Identification of Pathological Conditions in Human Skeletal Remains. Academic Press, San Diego, California.
Phenice, Terrell W.
1969 A Newly Developed Visual Method of Sexing the Os Pubis. *American Journal of Physical Anthropology* 30:297–302.
Raxter, Michelle H., Benjamin M. Auerbach, and Christopher B. Ruff
2006 Revision of the Fully Technique for Estimating Statures. *American Journal of Physical Anthropology* 130:374–384.
Saunders, Shelley
1978 *The Development and Distribution of Discontinuous Morphological Variation of the Human Infracranial Skeleton.* National Museum of Man Mercury Series, Archaeological Survey of Canada, Paper No. 81. National Museums of Canada, Ottawa.
Schaefer, Maureen, Sue Black, and Louise Scheuer
2009 *Juvenile Osteology: A Laboratory and Field Manual*. Academic Press, San Diego, California.
Sciulli, Paul W. and Brenda M. Hetland
2007 Stature Estimation for Prehistoric Ohio Valley Native American Populations Based on Revisions of the Fully Technique. *Archaeology of Eastern North America* 35:105–113.
Scott, Eugenie C.
1979 Dental Wear Scoring Technique. *American Journal of Physical Anthropology* 51:213–218.
Smith, B. Holly
1984 Patterns of Molar Wear in Hunter-Gatherers and Agriculturalists. *American Journal of Physical Anthropology* 63:39–56.

Steele, D. Gentry
1976 The Estimation of Sex on the Basis of the Talus and Calcaneus. *American Journal of Physical Anthropology* 45:581–588.
Suchey, Judy Meyers and Darryl Katz
1986 *Skeletal Age Standards Derived from an Extensive Multiracial Sample of Modern Americans*. Instructional materials accompanying male pubic symphyseal models of the Suchey-Brooks system. Distributed by France Casting, Fort Collins, Colorado. Copy on file, Office of the State Archaeologist, University of Iowa, Iowa City.
Trotter, Mildred
1970 Estimation of Stature from Intact Long Limb Bones. In *Personal Identification in Mass Disasters*, edited by T.D. Stewart, pp. 71–83. Smithsonian Institution, Washington, D.C.
Turner, Christy G. II
1971 Three-rooted mandibular first permanent molars and the question of American Indian origins. *American Journal of Physical Anthropology* 34:229–242.
Turner, Christy G. II, Christian R. Nichol, and G. Richard Scott
1991 Scoring Procedures for Key Morphological Traits of the Permanent Dentition: The Arizona State University Dental Anthropology System. In *Advances in Dental Anthropology*, edited by Marc A. Kelley and Clark Spencer Larsen. Wiley-Liss, New York.
Ubelaker, Douglas H.
1989 Human Skeletal Remains: Excavation, Analysis, Interpretation. 2nd ed. Taraxacum, Washington, D.C.
Warwick, Roger and Peter L. Williams (editors)
1973 *Gray's Anatomy*. 35th British edition. W.B. Saunders, Philadelphia.
White, Tim D., Michael T. Black, and Pieter A. Folkens
2012 *Human Osteology*. 3rd ed. Academic Press, San Diego.

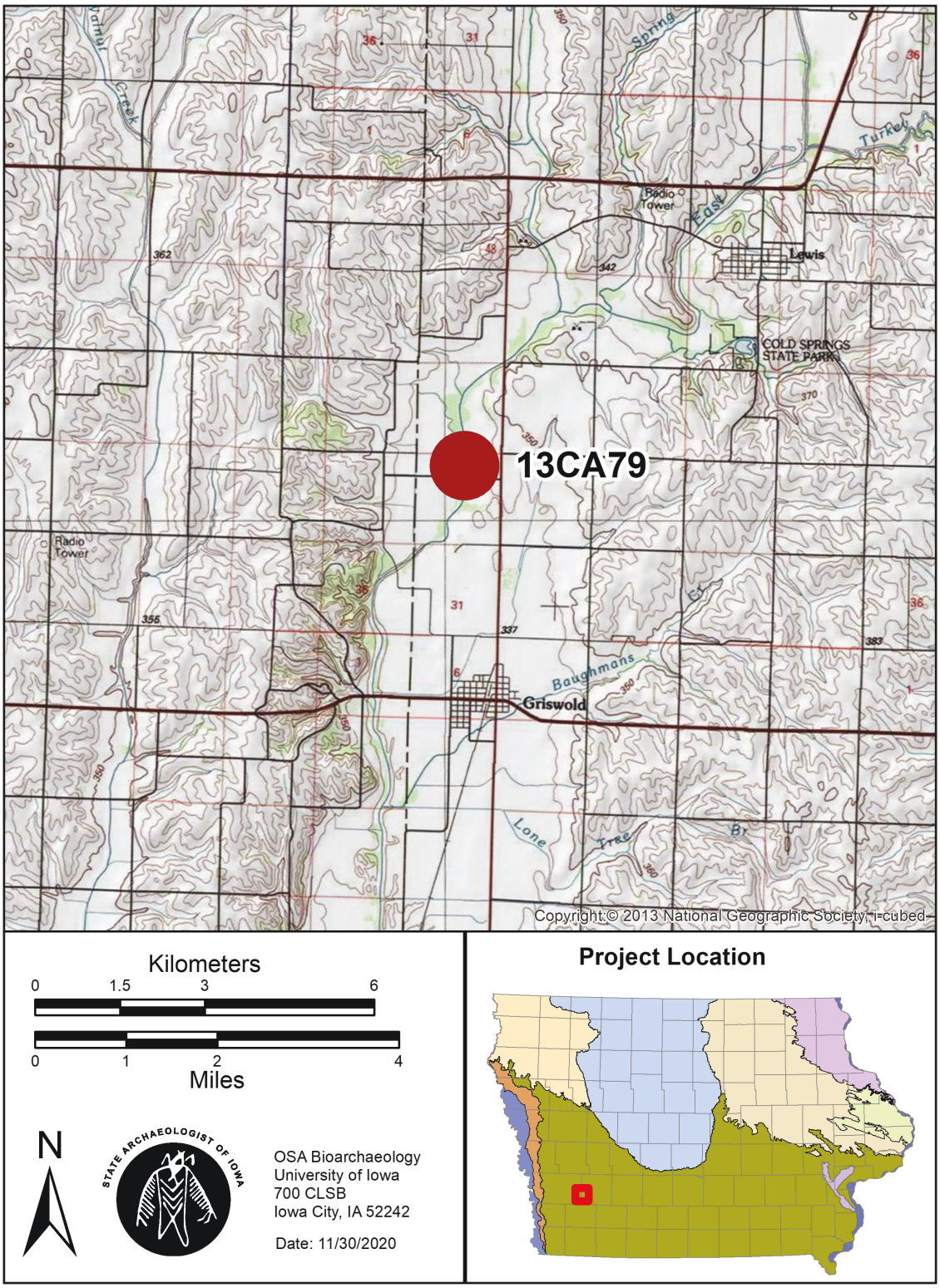

Figure 1. Findspot of human remains, 13CA79.
From USGS Atlantic SW, Cass County, Iowa (1971), 7.5'series quadrangle map. Scale 1:100,000.

A Human Mandible Recovered from a Sandbar (13CA79) in the East Nishnabotna River, Cass County, Iowa

Jennifer E. Mack

A human mandible recovered from a sandbar in the East Nishnabotna River in Cass County represents an adult of unknown age, possibly female. Though the original provenience of the human remains could not be identified, the context of the find and the condition of the bone suggests the remains represent an ancient Native American.

Introduction

On August 3, 2018, a private citizen discovered a partial human mandible on a sandbar in the East Nishnabotna River a few miles downstream from the town of Lewis in Cass County, Iowa (Figure 1). Once confirmed as human, the remains were transferred to the Office of the State Archaeologist Bioarchaeology Program. The sandbar findspot was designated 13CA79, but the original context of the human remains is unknown (UI, OSA 2018). Two potential Native American burial sites are known to exist in the general vicinity of Lewis. 13CA4 is the location of a Pottawattamie village, and 13CA5 was identified as a secondary burial site of unknown date. However, neither site is located directly on the river. No other known burial sites are located closer upstream from the findspot. In 2016, human cranial remains were recovered from a sandbar approximately 3.7 miles upstream from 13CA79, at a location designated 13CA75 (UI, OSA 2016). It is possible that both sets of remains originated from a single unknown burial site that is eroding into the river.

Osteological Analysis

This individual is represented by the right half of a mandible with two teeth still present (Tables 1 and 2). The broken edges and the anterior alveolar sockets are eroded, consistent with the element having been tumbled in the river. The cortical surfaces and the dentin of the two teeth are darkly stained, also consistent with bones recovered from a riverine environment. Part of the dark cortical surface has flaked off, revealing lighter colored bone beneath. Based on photographs taken immediately after discovery, it appears that most of this flaking is recent. At the time of recovery, small pebbles were deeply embedded in the empty alveolar sockets.

Age and sex cannot be determined with certainty based on the remains present. The mandible appears small and gracile, and the mental eminence is not prominent on the portion present, suggesting a possible female. The second molar cusps have been worn flat but with very little dentin exposure, suggesting the individual was an adult and likely not an old adult. Ancestry cannot be evaluated as dental morphology is not observable.

The portion of the mandible present should include sockets for the right third molar through left central incisor. However, the sockets for the central incisors have been eroded away by taphonomic processes, making it impossible to determine whether those teeth were lost antemortem or postmortem. Enough of the right lateral incisor socket remains to indicate that the tooth was lost postmortem, with no resorption.

The two adjacent teeth, the right canine and first premolar, were also lost postmortem. Between the first and second premolar sockets is a 5.8 mm diastema. The second premolar was also lost postmortem. The first molar is present, but nearly all of the crown enamel was broken off postmortem, leaving only the dark dentin in the center. The second molar is present and undamaged. The third molar appears to be congenitally absent, as there is no room in the arcade for the tooth.

Carious lesions were observed in both teeth present. The remaining dentin of the first molar has a large occlusal carious lesion which destroyed the distolingual quadrant of the tooth, affecting the lingual surface as well as the distal interproximal surface. Two pinpoint carious lesions are present on the distal half of the occlusal surface of the second molar in the natural crevices near the center of the tooth. The second molar has 5.2 mm of root length exposed on the buccal surface from alveolar resorption.

Summary

The mandible recovered out of context on a sandbar in the East Nishnabotna River represents a possible female adult. Carious lesions on the two remaining molars are the only pathology observed. Though ancestry cannot be determined osteologically, the location of the find and the apparent antiquity of the remains suggests the individual was Native American.

References Cited

University of Iowa, Office of the State Archaeologist (UI, OSA)
2016 Burial Project 3197. On file, Office of the State Archaeologist, University of Iowa, Iowa City.
2018 Burial Project 3375. On file, Office of the State Archaeologist, University of Iowa, Iowa City.

Table 1. Dental Inventory, Mandible from 13CA79, Burial Project 3375

Tooth	Presence	Attrition:	Attrition- molars:			
		I, C, P	Mes-buc	Mes-ling	Dis-ling	Dis-buc
MANDIBLE:						
LI1	9	9				
RM3	6		0	0	0	0
RM2	2		5	5	3	4
RM1	7		0	0	0	0
RP2	5	9				
RP1	5	9				
RC	5	9				
RI2	5	9				
RI1	9	9				

Dental Inventory Key:

Presence

1 Present but not in occlusion
2 Present, development completed, in occlusion
3 Missing, with no associated alveolar bone
4 Missing, with alveolus resorbing or fully resorbed: antemortem loss
5 Missing, with no alveolar resorption: postmortem loss
6 Missing, congenital absence
7 Present, damage renders measurements impossible
8 Present but unobservable (e.g. teeth in crypts)
9 Unobservable

Attrition (molars)

0 Unobservable
1 Wear facets invisible or very small
2 Wear facets large, but cusps and surface features still evident
3 Any cusp in quadrant is rounded, but not flat
4 Quadrant is worn flat, but no dentin is exposed (except pinprick-sized)
5 Quadrant is flat, dentin exposed on ¼ of quadrant
6 More than ¼ of dentin is exposed, with enamel ring still complete
7 Enamel is found on only two sides of quadrant
8 Enamel on only one side of quadrant, but enamel is still thick
9 Enamel on only one side of quadrant and it is very thin
10 No enamel remaining. Wear extends below the cervicoenamel junction onto the root

Table 2. Dental Pathologies, Mandible from 13CA79, Burial Project 3375

Tooth	Calculus:		Caries:		Abscess:
	Presence	Location	Number	Type	Type
MANDIBLE:					
RM1	absent		1	occlusal, large	none
RM2	absent		2	occlusal, pin-point	none

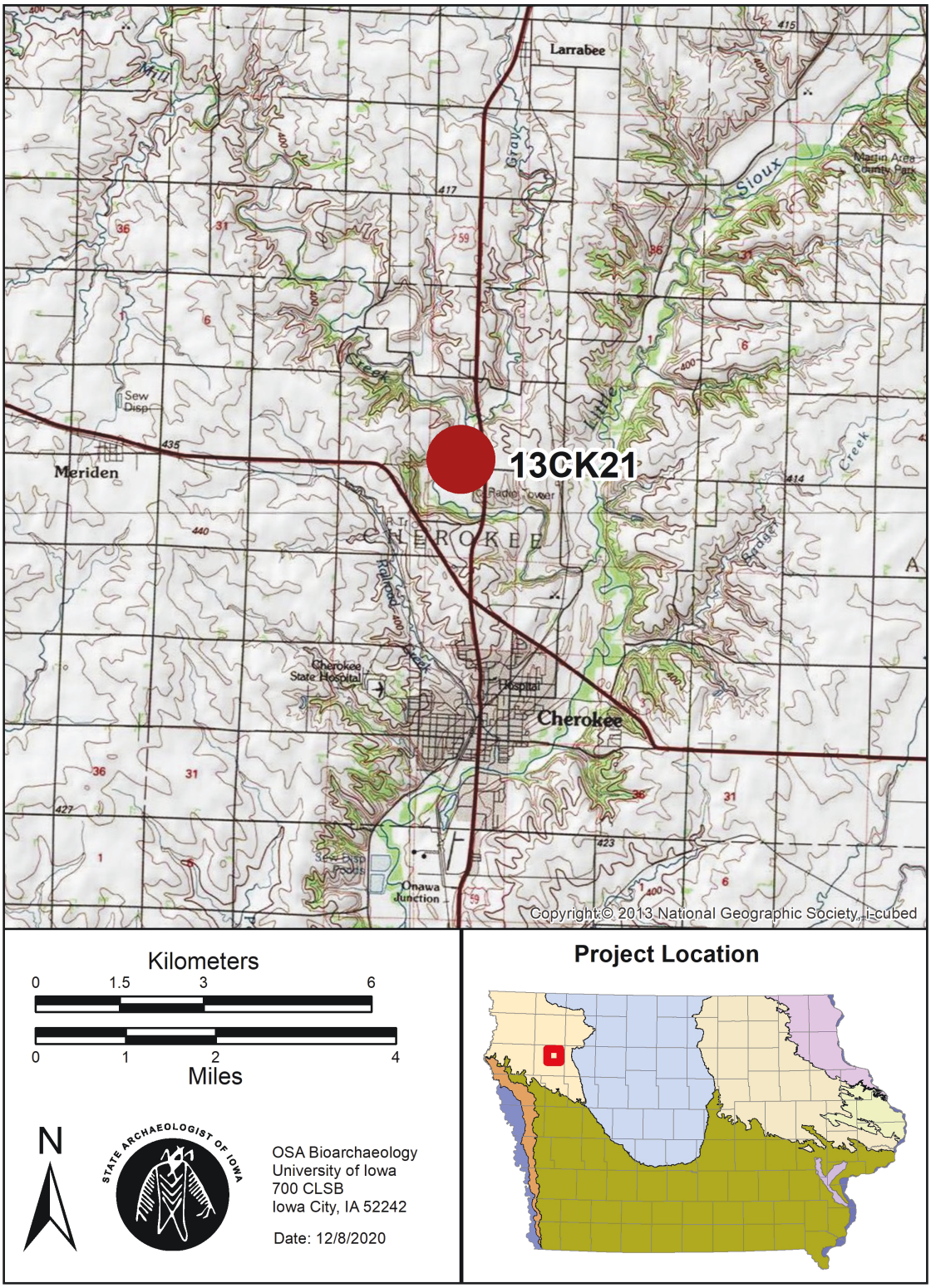

Figure 1. Location of the Phipps Site, 13CK21.
From USGS Cherokee North, Cherokee County, Iowa (1971), 7.5' series quadrangle map. Scale 1:100,000.

A Human Tooth from the Phipps Site (13CK21), Cherokee County, Iowa

Jennifer E. Mack

A single human tooth discovered among the faunal remains excavated from the Phipps Site (13CK21) in 1955 represents an old adult of unknown sex. The context of recovery, a Mill Creek village site, indicates that the remains represent a pre-contact Native American.

Introduction

The Phipps Site (13CK21, Figure 1) is a Mill Creek village which has been the subject of multiple excavations. Ellison Orr's work in 1934 was followed by excavations from 1952-1956 directed by Reynold Ruppé and jointly sponsored by the Northwest Chapter of the Iowa Archaeological Society, the Sanford Museum, and the University of Iowa. Additional excavation projects were conducted by the University of Wisconsin-Madison in 1963 and the Office of the State Archaeologist in 1994. Numerous surface collections have also been performed at the site. Only one intact burial, discovered during the 1950s excavations, was identified at 13CK21, though isolated human remains from the site have previously been identified in archaeological collections, reported, and reburied (Lillie 2014; UI, OSA 1977, 1990, 1994, 2002, 2007, 2014).

The subject of the current report is a human tooth which was found in 2018 among faunal materials from Ruppé's 1955 excavation. The accession number, 12614, indicates that the faunal materials were originally housed in the Sanford Museum collections before being transferred to the Office of the State Archaeologist in 2018. The tooth was previously assigned catalog number CK4042, and the provenience is recorded as SE7A, 54-60 inches.

Osteological Analysis

The tooth discovered among the faunal materials in 2018 is represented only by a root with a polished occlusal surface. Based on the shape and size of the root, the tooth appears to be a maxillary left central incisor. Age is estimated as old adult, as the crown has been completely worn down. There is no trace of enamel and the crown surface has taken on the shape of the root (wear score=8). Sex is indeterminate.

Provenience and severe dental wear indicate that this tooth represents an ancient Native American. This discovery of human remains increases the MNI for the site, as no old adults were identified among the previously reported remains.

References Cited

Lillie, Robin M.

2014 Human Skeletal Remains from the Sanford Museum Collections: 13BV2, Buena Vista County; 13CK1 and 13CK21, Cherokee County; 13DK23, Dickinson County; and 13PM8 and 13PM50, Plymouth County, Iowa. *In* Reports on Burial Projects Osteology and Archaeology. Research Papers Vol. 38, No. 1. Office of the State Archaeologist, University of Iowa, Iowa City.

University of Iowa, Office of the State Archaeologist (UI, OSA)

1977 Burial Project 21. On file, Office of the State Archaeologist, University of Iowa, Iowa City.

1990 Burial Project 393. On file, Office of the State Archaeologist, University of Iowa, Iowa City.

1994 Burial Project 797. On file, Office of the State Archaeologist, University of Iowa, Iowa City.

2002 Burial Project 1587. On file, Office of the State Archaeologist, University of Iowa, Iowa City.

2007 Burial Project 2160. On file, Office of the State Archaeologist, University of Iowa, Iowa City.

2014 Burial Project 3060. On file, Office of the State Archaeologist, University of Iowa, Iowa City.

2018 Burial Project 3394. On file, Office of the State Archaeologist, University of Iowa, Iowa City.

Human Skeletal Remains Recovered from 13CK98, Cherokee County, Iowa

Jennifer E. Mack

Human cranial remains transferred to the University of Iowa Office of the State Archaeologist (OSA) in 2017 represent two of the three individuals discovered at 13CK98 during ground disturbance in 1939. An old adult male and middle adult female are represented by the remains. A copper object included in the collection may have been interred with the female. X-ray fluorescence analysis suggests the object dates to the postcontact period.

Introduction

In the autumn of 1939, a Civilian Conservation Corps crew recovered three human skeletons while excavating a gravel pit near the town of Cherokee, Iowa (Figure 1). The remains were encountered approximately four feet below the ground surface on the property of a local farmer. One of the individuals, likely a primary interment was reportedly buried with the legs flexed and knees up (*Bee* 1939; *Sentinel* 1939). The find was reported to early Iowa archaeologist Charles Keyes, who noted that a copper "knife" was recovered with the remains (Keyes 1940). No other artifacts are mentioned in the newspaper articles or Keyes' notes. A state site form was later completed for the discovery, with the site designated 13CK98, but for decades, the whereabouts of the remains and copper object were unknown.

In August 2016, the University of Iowa was contacted by a private citizen about human remains that had previously been in the possession of her deceased grandfather. Though her grandfather's collection included only two skulls, the presence of a knife-shaped copper object, the reported location of the discovery, and the dates on newspapers lining the storage box all indicate that these are the human remains recovered from 13CK98 in 1939. The skeletal remains and the artifact were transferred to the OSA Bioarchaeology Program in February 2017 (UI, OSA 2016).

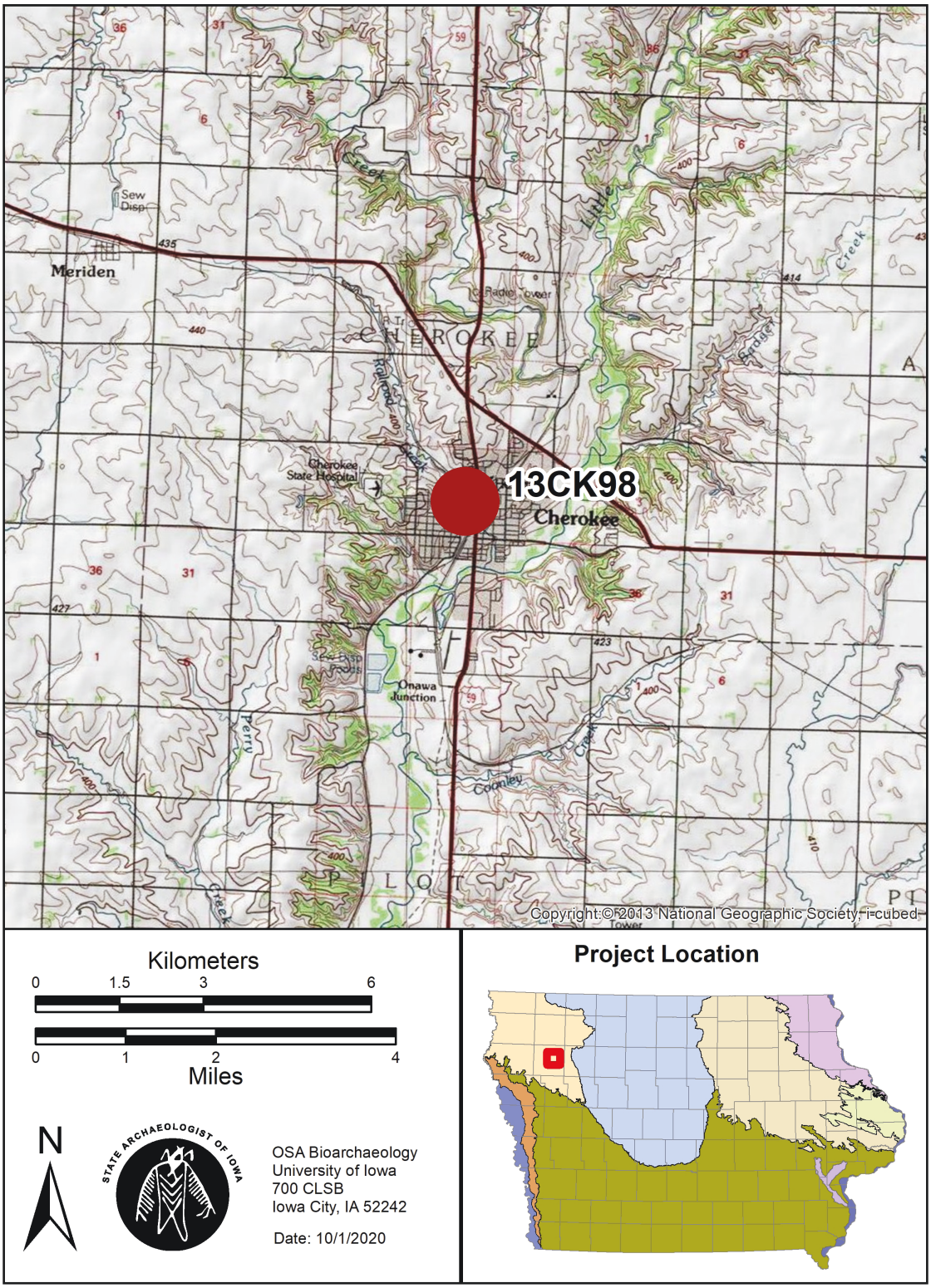

Figure 1. Location of 13CK98.
From USGS Cherokee North, Cherokee County, Iowa (1971), 7.5' series quadrangle map. Scale 1:100,000.

Osteological Analysis

The skeletal collection consists of two crania with matching mandibles. No postcranial elements are present, and the third individual reportedly excavated is not represented by the remains.

INDIVIDUAL 1

Individual 1 is represented by the complete cranial vault, separated facial skeleton, and left half of the mandible, all with substantial root etching. At some point in the past, perhaps at the time of recovery, a dark, shellac-like substance was applied thickly to the entire left half of the cranium and mandible. This material, which was painted over adhering soil in places, obscures some details on the ectocranial surface.

The sexually dimorphic features of the skull indicate that the individual was male. The cranium has very prominent brow ridges, blunt orbital margins, a prominent and rugged nuchal crest, and medium-to-large mastoid processes. Age was estimated by cranial suture closure and dental wear. The cranial sutures suggest the individual was 35-60 years old at the time of death. The older end of this estimate is supported by wear on the teeth. All of the teeth present are worn down to the roots, with only small remnants of the crown enamel, suggesting the individual was an old adult (>50 years). See Table 1 for cranial metrics.

Twelve maxillary teeth and two mandibular teeth are present (see Tables 2 and 3 for dental inventory and pathology). Of the four missing upper teeth, two were lost postmortem (the third molars), while the right second molar may have been lost antemortem with no resorption and the left second molar was almost certainly lost antemortem. Both second molar sockets have bone alteration indicating infection. The left second molar socket has a resorbed buccal margin which would have exposed a significant length of tooth root. Superior to the buccal socket margin is a depression which appears to be the perforation of a periapical abscess. Thick shellac application makes it difficult to determine, but it appears that the perforation was largely healed at the time of death. Since the individual internal sockets for the three roots of the tooth are still discernible, the tooth likely remained in the alveolus despite the abscess or was removed shortly before death. However, the right second molar socket has a buccal perforation indicating an abscess was active perimortem. There is also a small perforation on the lingual surface of the socket, though this may be postmortem damage. The coalescence of two internal root sockets suggests that this tooth was lost due to the abscess.

The left portion of mandible present should hold six teeth. The canine was lost postmortem, while the third molar was either congenitally absent or had been lost antemortem with full resorption. The other two missing mandibular molars appear to have been lost antemortem. The second molar socket was almost obliterated by infection, and the alveolar height at this socket is extremely low compared with the rest of the mandible. The remaining portion of the socket is a depression without clear margins, which was filling in with woven bone at the time of death. The first molar socket was damaged postmortem, but it appears to have had a buccal perforation. Also, the internal division between the mesial and distal roots was resorbed antemortem, suggesting the tooth was lost shortly before death. Other than the dental abscesses, no pathology was observed on the remains. The teeth have no carious lesions or dental calculus.

The rounded shape of the palate and the projection of the zygomatics indicate that the individual was Native American, a finding which is consistent with the burial context and the level of dental wear. When cranial metrics were entered into FORDISC and compared with those of American Indian and White males in the Forensic Data Bank, this individual was found to be closest to American Indian males, with a cross-validation rate of 82.9% and posterior probability of 0.879.

This individual has two morphological features of note. The right foramen spinosum is enclosed by a bridge of bone, forming a short tunnel running from the foramen towards the angular spine. Also, the temporal lines are prominent. The posterior halves of the temporal lines on the frontal are rugose. Where the temporal lines cross the coronal suture, they become more rugose, with a linear, wrinkled/pleated appearance. On both the left and right parietals, the inferior temporal lines angle sharply medially and almost join with the

raised ridges representing the superior temporal lines. These features appear to be particularly pronounced attachments for the temporalis muscle and the temporal fascia rather than pathological bone.

INDIVIDUAL 2

The complete skull representing Individual 2 is well preserved except for extensive root etching, though shellac applied to the ectocranial surface makes some observations difficult. Green staining is present on most of the lingual surface of the mandibular alveolus, likely from proximity to the copper object associated with these burials. The buccal surface of the right alveolus has fainter green staining, and the exposed dentin of the mandibular right first molar has a slight green tint. No other portions of the cranium have green staining, suggesting the copper object may have been resting under the lower jaw of the individual in the original burial context.

Most of the sexually dimorphic features of the skull indicate that the individual was female. The cranium exhibits a smooth brow, sharp orbital margins, a small nuchal crest, small-to-medium mastoid processes, and a moderate mental eminence. Age was estimated based on cranial suture closure and dental wear. The cranial sutures suggest the individual was 30-45 years old at the time of death. The younger end of this estimate is supported by wear on the teeth, which was significantly less severe in this individual than Individual 1.

All 32 teeth are present with no calculus, cavities, or abscesses present. Significant dentin exposure was observed only on the central incisors and first molars. The third molar crowns are not yet worn flat. See Tables 4 and 5 for dental inventory and metrics.

Though this individual has an elongated palate, which is more typical of Euroamericans, the winging and shovel morphology of the maxillary incisors suggest Native American ancestry, as do the slight projection of the zygomatics and the burial context. The cranial metrics (see Table 1) were entered into FORDISC and compared with those of American Indian and White females in the Forensic Data Bank. This individual's measurements were found to be closest to American Indian females, with a cross-validation rate of 96.0% and a posterior probability of 0.798. When the measurements were compared against those of Arikara females and nineteenth-century White females in Howells' database, the individual was found to be closest to Arikara females, with a cross-validation rate of 98.0% and a posterior probability of 0.895.

Expansion and lipping of the occipital condyles suggest past trauma or pathology. The articular surface of the left condyle has expanded posteriorly and medially, so that the margin of the foramen magnum is now part of the articular surface. On the right condyle, the expansion occurred anterolaterally, with pronounced lipping. The overall appearance suggests some type of trauma or gradual pathological instability which caused the atlas to shift slightly counterclockwise (as viewed superiorly). Simple degenerative joint disease could also explain the alterations to the condyle margins.

Associated Artifact

The copper object that was described to Charles Keyes as a knife more closely resembles a pendant. The object is thin, flat and roughly rectangular, measuring 171 mm long. The object is narrowest at the end with the perforation, measuring 31 mm. The perforation itself is approximately 10 mm in diameter and is irregular, likely due to breakage and corrosion. The other end of the object measures 44 mm wide. The wider end of the object is thinner, measuring 1.9 mm, while the narrower end has a maximum thickness of 2.9 mm. The object is extensively corroded (green, brown, and red) and many of the edges have crumbled. Based on the object's current appearance, one archaeologist opined that it was likely made by beating native copper (Marlon Ingalls, personal communication 2017). However, when the object was subjected to x-ray fluorescence analysis, the purity of the copper (99%) indicated that it was manufactured from extracted copper, and therefore dates to the postcontact period (Andrew Sommerville, personal communication 2019).

Summary

An old adult male and a young-to-middle adult female are represented by cranial remains recovered from 13CK98 in 1939. Both individuals are Native American, based on context, cranial and dental morphology, and discriminant function analysis of cranial metrics. The male suffered from multiple dental abscesses not long before death. The female may have sustained antemortem trauma to the neck, based on irregularities of the articular surfaces of the occipital condyles. The postcranial elements associated with these individuals and the remains of the third individual reportedly discovered at the site are not present in the collection. The perforation in the flat copper object found with the burials (likely with Individual 2) suggests it was a pendant rather than a knife. The purity of the copper (99%) indicates the object—and therefore the burial—dates to the postcontact period.

References Cited

Bee
1939 "Skeletons Found in Cherokee Gravel Pit." 30 November. Ossian, Iowa.
Keyes, Charles R.
1940 "From N. L. Stiles." County Notes, Cherokee County. 5 April. On file, Office of the State Archaeologist, University of Iowa, Iowa City.
Sentinel
1939 "Hundreds Flock to See Skeletons of Indians." 16 November. Hartley, Iowa.
University of Iowa, Office of the State Archaeologist (UI, OSA)
2016 Burial Project 3214. On file, Office of the State Archaeologist, University of Iowa, Iowa City.

Table 1. Cranial Metrics (mm), Individuals 1 and 2, 13CK98, Burial Project 3214

Cranial metric	Individual 1	Individual 2
Maximum cranial length	188	176
Maximum cranial breadth	143	138
Bizygomatic diameter		130
Basion-bregma height		132
Cranial base length		98
Basion-prosthion length		99
Maxillo-Alveolar breadth		63
Maxillo-Alveolar length	60	54
Biauricular breadth	127	123
Upper facial height		68
Minimum frontal breadth	89	91
Upper facial breadth	106	102.5
Nasal height		49
Nasal breadth	22	24
Orbital breadth L		37
Orbital breadth R		37.5
Orbital height L		34
Orbital height R		33.5
Biorbital breadth		94
Interorbital breadth		22
Frontal chord	108	105
Parietal chord	111	107
Occipital chord	97	95.5
Foramen magnum length		34
Foramen magnum breadth		27
Mastoid length L	27	31
Mastoid length R	27	31
Chin height		32
Mandibular height L		29
Mandibular height R		29.5
Bigonial width		90.5
Bicondylar breadth		116
Minimum ramus breadth L	36	32.5
Minimum ramus breadth R		34.5
Maximum ramus breadth L		42
Maximum ramus breadth R		43
Ramus height L		59.5
Ramus height R		59.5
Mandibular length		77
Mandibular angle		121

Table 2. Dental Inventory, Individual 1, 13CK98

Tooth	Presence	Attrition:	Attrition- molars:			
		I, C, P	Mes-buc	Mes-ling	Dis-ling	Dis-buc
MAXILLA:						
RM3	5		0	0	0	0
RM2	4		0	0	0	0
RM1	2		10	10	10	10
RP2	2	6				
RP1	2	7				
RC	2	7				
RI2	2	8				
RI1	2	7				
LM3	5		0	0	0	0
LM2	5		0	0	0	0
LM1	2		10	9	9	10
LP2	2	8				
LP1	2	8				
LC	2	7				
LI2	2	8				
LI1	2	7				
MANDIBLE:						
LM3	9		0	0	0	0
LM2	4		0	0	0	0
LM1	5		0	0	0	0
LP2	2	7				
LP1	2	7				
LC	5	9				
LI2	3	9				
LI1	3	9				

Dental Inventory Key:
Presence
1 Present but not in occlusion
2 Present, development completed, in occlusion
3 Missing, with no associated alveolar bone
4 Missing, with alveolus resorbing or fully resorbed: antemortem loss
5 Missing, with no alveolar resorption: postmortem loss
6 Missing, congenital absence
7 Present, damage renders measurements impossible
8 Present but unobservable (e.g. teeth in crypts)
9 Unobservable
Attrition (I, C, PM)
1 Unworn or small facets
2 Point or hairline of dentin
3 Dentin line of distinct thickness
4 Moderate dentin exposure, not resembling a line
5 Large dentin area with rim complete (two areas on premolars)
6 Large dentin area with enamel rim lost on one side (two areas coalesced on premolars)
7 Enamel rim lost on two sides (at least one side lost on premolars)
8 Complete loss of crown, no enamel remaining
9 Unobservable
Attrition (molars)
0 Unobservable
1 Wear facets invisible or very small
2 Wear facets large, but cusps and surface features still evident
3 Any cusp in quadrant is rounded, but not flat
4 Quadrant is worn flat, but no dentin is exposed (except pinprick-sized)
5 Quadrant is flat, dentin exposed on ¼ of quadrant
6 More than ¼ of dentin is exposed, with enamel ring still complete
7 Enamel is found on only two sides of quadrant
8 Enamel on only one side of quadrant, but enamel is still thick
9 Enamel on only one side of quadrant and it is very thin
10 No enamel remaining. Wear extends below the cervicoenamel junction onto the root

Table 3. Dental Pathologies, Individual 1, 13CK98.

Tooth	Calculus:		Caries:		Abscess:
	Presence	Location	Number	Type	Type
MAXILLA:					
RM2	absent		0		buccal and lingual perforation
LM2	absent		0		buccal perforation
MANDIBLE:					
LM2	absent		0		buccal perforation
LM1	absent		0		buccal perforation

Table 4. Dental Inventory, Individual 2, 13CK98

Tooth	Presence	Attrition:	Attrition- molars:			
		I, C, P	Mes-buc	Mes-ling	Dis-ling	Dis-buc
MAXILLA:						
RM3	2		4	3	3	4
RM2	2		3	5	4	3
RM1	2		0	7	7	0
RP2	2	3				
RP1	2	3				
RC	2	3				
RI2	2	2				
RI1	2	3				
LM3	2		4	3	3	4
LM2	2		4	5	4	4
LM1	2		0	7	7	5
LP2	2	3				
LP1	2	3				
LC	2	3				
LI2	2	3				
LI1	2	3				
MANDIBLE:						
LM3	2		3	4	4	3
LM2	2		4	4	4	4
LM1	2		7	6	6	7
LP2	2	2				
LP1	2	3				
LC	2	3				
LI2	2	2				
LI1	2	3				
RM3	2		4	3	3	4
RM2	2		4	4	4	4
RM1	2		0	7	6	0
RP2	2	2				
RP1	2	3				
RC	2	3				
RI2	2	2				
RI1	2	3				

Dental Inventory Key:
Presence
1 Present but not in occlusion
2 Present, development completed, in occlusion
3 Missing, with no associated alveolar bone
4 Missing, with alveolus resorbing or fully resorbed: antemortem loss
5 Missing, with no alveolar resorption: postmortem loss
6 Missing, congenital absence
7 Present, damage renders measurements impossible
8 Present but unobservable (e.g. teeth in crypts)
9 Unobservable
Attrition (I, C, PM)
1 Unworn or small facets
2 Point or hairline of dentin
3 Dentin line of distinct thickness
4 Moderate dentin exposure, not resembling a line
5 Large dentin area with rim complete (two areas on premolars)
6 Large dentin area with enamel rim lost on one side (two areas coalesced on premolars)
7 Enamel rim lost on two sides (at least one side lost on premolars)
8 Complete loss of crown, no enamel remaining
9 Unobservable
Attrition (molars)
0 Unobservable
1 Wear facets invisible or very small
2 Wear facets large, but cusps and surface features still evident
3 Any cusp in quadrant is rounded, but not flat
4 Quadrant is worn flat, but no dentin is exposed (except pinprick-sized)
5 Quadrant is flat, dentin exposed on ¼ of quadrant
6 More than ¼ of dentin is exposed, with enamel ring still complete
7 Enamel is found on only two sides of quadrant
8 Enamel on only one side of quadrant, but enamel is still thick
9 Enamel on only one side of quadrant and it is very thin
10 No enamel remaining. Wear extends below the cervicoenamel junction onto the root

Table 5. Dental Metrics (mm), Individual 2, 13CK98

Tooth	Mesiodistal	Buccolingual	CEJ mesiodistal	CEJ buccolingual
MAXILLA:				
RM3	8.8	10.7		9.7
RM2	10.0	11.8		
RM1				
RP2				
RP1	6.1	9.4		
RC		8.7	6.4	
RI2		6.9	4.8	
RI1		7.2	6.4	
LM3	8.5	11.1		10.2
LM2	9.6	11.6		
LM1				
LP2	5.9	8.5		
LP1	6.5	9.5		
LC		8.5	6.5	
LI2		6.7	5.0	
LI1		7.3	6.6	
MANDIBLE:				
LM3	9.8	10.1		
LM2	10.3	10.4	9.2	
LM1			9.0	
LP2	6.3	7.6	5.2	
LP1	6.1	7.8	4.9	7.4
LC		7.0	5.3	6.9
LI2		5.9		
LI1		5.7		
RM3	9.7	11.5		
RM2	10.2	10.8		
RM1				
RP2	6.1	7.3		
RP1	6.6	7.8	4.8	
RC		7.0	5.2	
RI2		5.9	4.3	
RI1		5.6	3.3	

Human Skeletal Remains Excavated from 13DB40 and 13DB1140, Dubuque County, Iowa, and Richards Mound Group in Grant County, Wisconsin

Jennifer E. Mack

Human remains transferred to the Bioarchaeology Program of the Office of the State Archaeologist in 2016 include elements from three separate proveniences: 13DB40 (mound site), 13DB1140 (an undescribed site with isolated human remains), and Richard Mound Group (unknown location in Grant County, Wisconsin). The skeletal fragments had become commingled in the decades after excavation, and precise provenience for individual elements is unknown. The Minimum Number of Individuals (MNI) for the entire collection is 16, including seven adults, eight subadults, and one possible subadult. Sex could not be determined for most of the adult individuals. Pathology includes slight degenerative joint disease observed on a number of elements, and osteomyelitis on a right third metacarpal.

Introduction

In May 2016, a private citizen approached the University of Iowa Office of the State Archaeologist Bioarchaeology Program (OSA-BP) about commingled human remains from three archaeological proveniences, including 13DB40 and 13DB1140, in Dubuque County, Iowa, and an unknown mound site, referred to as Richards Mounds, in Grant County, Wisconsin. These human remains had been excavated by amateurs in the 1950s and 1960s. After one of the excavators passed away, a relative retrieved the human remains from California and transferred them to the OSA-BP (UI, OSA 2016).

13DB40, WAUPETON MOUNDS

The majority of the remains in the collection originated from Waupeton Mounds (13DB40, Figure 1), a group of five conical mounds and one linear mound located on a narrow ridge overlooking the Mississippi River near Waupeton, Dubuque County, Iowa. In the mid-twentieth century, the landowner's plan to build cottages along the ridge prompted locals to partially excavate three of the conical mounds and to dig an exploratory hole into in one end of the linear mound. These amateur excavations took place in August 1962. No maps or formal excavation records exist, but three pages of typed notes and musings and 30 black and white photographs from the project survive. Additionally, the citizen who transferred the remains to the OSA-BP provided his own recollections, having participated in the dig as a young teenager. At the time of excavation, all mounds in the group were reported as being approximately three feet high.

Mound 1, the mound closest to the edge of the bluff, yielded most of the reported discoveries, including an extended adult burial with a ceremonial blade, the burial of an adult (presumed female) with an infant, a cluster of eleven or twelve crania, and the skeletons of three dogs placed with a human burial. Additional burials which were shallower are not described, as the excavator attributed them to "modern Indians" rather than the builders of the mounds. The excavator's notes also mention "…one baby skull and many arm and leg bones, and also many teeth. We found a skull we believe to be that of a teenage Indian (UI, OSA 2016)." Freshwater shells and baked clay were reportedly found around the burials. Seven freshwater shell

fragments, four small faunal bones, two pieces of baked clay, and one small piece of limestone are still present in the collection.

In Mound 2, at a depth of about 2 ½ feet, excavators discovered the extended burial of an adult almost six feet tall. No grave goods were recovered. In Mound 4 they found evidence of cremation, including pieces of ash, charcoal, and bone along with reddened soil. A hammerstone and chert flakes were found closer to the surface (not present in the collection). The linear mound also yielded cremated remains (UI, OSA 2016). No further details of the excavation are available. No fire-altered skeletal remains are present in the collection donated to the OSA-BP.

13DB1140

One skull in the collection was reportedly recovered from the current location of Wahlert High School in the city of Dubuque (13DB1140, Figure 2). The remains were uncovered during construction of the school, which occurred sometime between 1955 and 1959 (UI, OSA 2016). The exact circumstances of the discovery and details about the site are unknown; a search of local newspapers from the 1950s found no mention of the event. Unfortunately, the tag indicating which cranium in the collection originated from 13DB1140 became detached. At the time of analysis, the tag was stored with the cranium designated Adult 4. However, since this cranium appears in the series of photos showing the cleaning of materials and restoration of crania from the Waupeton Mound site, it is likely that Adult 4 originated from 13DB40, not 13DB1140.

RICHARDS MOUND GROUP (WISCONSIN)

The collection donated to the OSA-BP reportedly includes a few long bones from a mound group across the Mississippi River from Dubuque in Wisconsin, likely Grant County. The site, known locally as the Richards Mound Group, was also excavated by amateurs in 1962. The mounds are described as a divided group, with some located on the bluff overlooking the Mississippi and some at a lower elevation, close to the river. One of the mounds on the bluff was reported to contain the burials of seven adults buried with two projectile points, part of a bear skull, and a necklace made from split bear teeth. Excavation of one of the mounds near the river uncovered burials, projectile points, pottery, and a “very well shaped” human effigy (UI, OSA 2016). These artifacts are not present in the collection donated to the OSA-BP, and it is not possible to determine which long bones originated from this mound group rather than 13DB40. A search of the Wisconsin site file failed to identify the location of the Richards Mound Group.

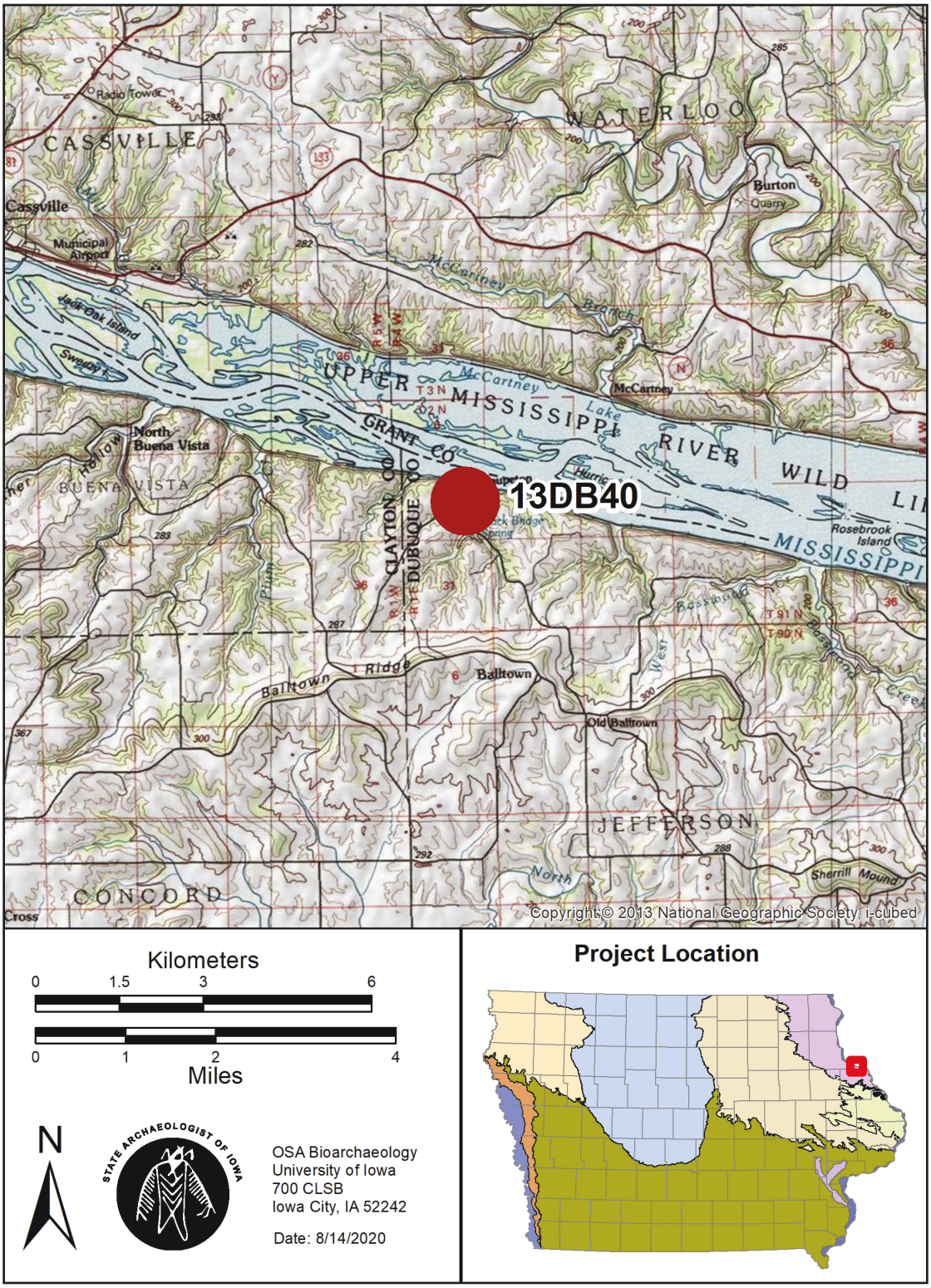

Figure 1. Location of Waupeton Mounds, 13DB40.
From USGS Cassville, Dubuque County, Iowa, 7.5' series quadrangle map. Scale 1:100,000.

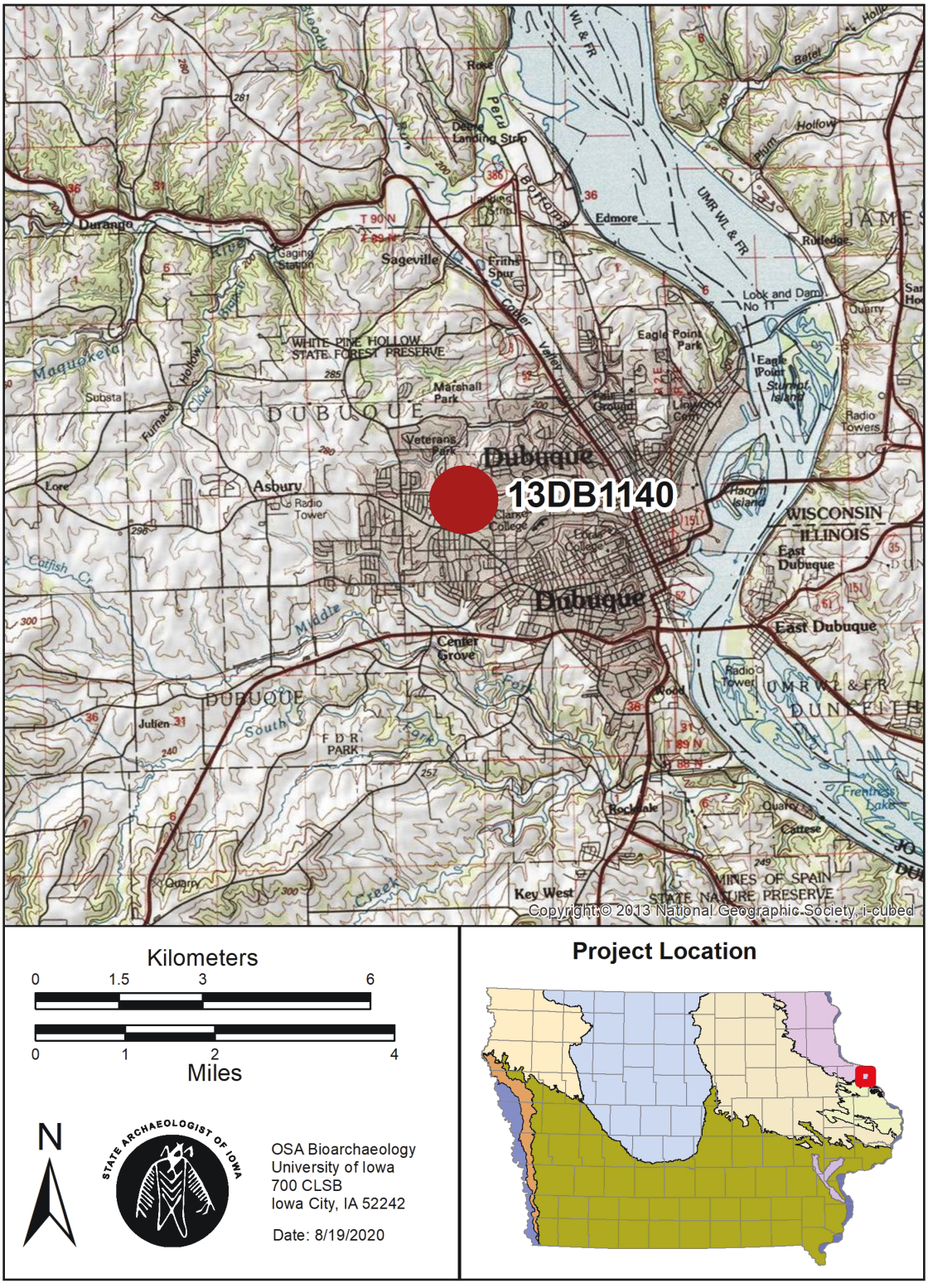

Figure 2. Location of 13DB1140.
From USGS Dubuque North, Dubuque County, Iowa, 7.5' series quadrangle map. Scale 1:100,000.

Osteological Analysis

The Minimum Number of Individuals (MNI) for this collection was determined by dental arcades. Most of the 16 individuals are represented by the right mandibular alveolus and associated dentition, but a few additional individuals were differentiated by marked differences in dental development or tooth wear observed on left mandibular or maxillary portions.

CRANIAL AND MANDIBULAR REMAINS

Adult 1

Adult 1 consists of a nearly complete cranium, the facial skeleton of which was partially reconstructed with an orange epoxy-like substance. The cranium is well-preserved and intact but was covered with some type of lacquer that has yellowed over time. The lacquer was applied on top of adhering soil, preventing cleaning during analysis and obscuring details. This cranium does not appear to match the remains shown in either of the photographed extended burials from Mounds 1 or 2 at 13DB40. Adult 1 may have originated from the ossuary feature described in Mound 1 or from one the unphotographed burials. It is also possible that Adult 1 is the cranium discovered during the construction of Wahlert High School. See Table 1 for cranial metrics.

The mandible that was previously glued to the cranium (Mandible 2) does not belong with this individual, as the condyles are set too wide and the level of dental attrition is inconsistent with that of the maxillary teeth. The dental attrition of Mandible 1 (described separately in the mandible section below) is consistent with that seen on the maxillary teeth of Adult 1, but the dentition and condyles are too incomplete to confirm or eliminate a match. Because of this uncertainty, Adult 1 does not contribute to the MNI for the site; instead, Mandible 1 is counted.

Adult 1 was likely male, based on the size and robusticity of the skull and all observable sexually dimorphic features. The individual is presumed Native American, based on provenience and slightly projecting zygomatics. Cranial suture closure indicates the individual was a middle or old adult at the time of death. Severe dental attrition with complete loss of crown enamel on the anterior teeth suggests the older end of the range. The individual was likely an old adult (>50 years).

The dental remains were incomplete, represented by only half of the maxillary teeth, including the left canine and the right lateral incisor through third molar, all heavily worn (Table 2). Damage to the maxilla and lacquered-on soil made it difficult to determine how several teeth were lost, but no clear evidence of antemortem tooth loss was observed. Dental measurements were not possible due to crown loss and adhering lacquer-fixed soil. No carious lesions were observed in the teeth present.

No pathology was observed on the cranium.

Adult 2

Adult 2 consists of the reconstructed left half of a cranium (nearly complete and well-preserved) and the portions of the right parietal, frontal, maxilla, and mandible immediately lateral to midline. Unlike Adult 1, the Adult 2 cranium was cleaned fairly well before application of the lacquer-like substance. A reddish-orange epoxy-like material was used for the reconstruction. The entire cranial vault exhibits root etching and post-mortem erosion. The erosion is most severe on the right parietal and left occipital. This cranium does not match the remains photographed in the extended burials in Mounds 1 and 2 at 13DB40. However, the skull does appear in photographs of the cleaning and processing work that followed the amateur excavations at 13DB40, so it is likely Adult 2 originated from that mound site. See Table 1 for cranial metrics.

Though not all sexually dimorphic cranial features are observable, this individual is probably female, based on the complete absence of any supraorbital tori and the pointy shape of the chin. The left orbital

margin is fairly sharp, and the left mastoid process is intermediate. Age is estimated as young adult, based on a few observable open sutures and the relatively moderate dental wear. The anterior teeth range from hairline dentin exposure to a narrow dentin line of distinct thickness. Posterior tooth wear could not be observed, as the mandible was glued to the maxilla.

Ancestry observations confirm expectations based on likely provenience. The maxillary incisors all exhibit shoveling, with the central incisors being double-shoveled. The mandibular teeth have a less pronounced expression of shoveling, but slight shoveling of the labial surfaces was also observed.

The dental remains are in good condition and indicate excellent dental health, with no carious lesions or antemortem tooth loss observed on the alveolar portions present. The margins of the alveolar sockets for the maxillary central incisors have a serrated appearance--perhaps related to slight recession of the gums--and have withdrawn to expose just about 1.5 mm of root. Three enamel hypoplastic lines (EHL), all taking the form of horizontal grooves, were observed. The EHLs on both mandibular canines indicate a growth disruption around 4.6 years. The hypoplasia on the mandibular left first incisor suggests a growth disruption around 2.3 years, but without a matching hypoplasia, this cannot be confirmed. See Tables 3 and 4 for dental inventory and metrics.

No pathology was observed on the cranium.

Table 1. Cranial Metrics (mm), Adults 1, 2, and 4, Dubuque County, Burial Project 3189

Cranial metric	Adult 1	Adult 2	Adult 4
Maximum cranial length	192		
Maximum cranial breadth	145		
Bizygomatic diameter			
Basion-bregma height	141		
Cranial base length	108		
Basion-prosthion length			
Maxillo-Alveolar breadth			
Maxillo-Alveolar length			
Biauricular breadth	133.5		127
Upper facial height			
Minimum frontal breadth	98		97
Upper facial breadth	111		111
Nasal height	54		
Nasal breadth	26		
Orbital breadth L			
Orbital breadth R	44		
Orbital height L			
Orbital height R	39		
Biorbital breadth			
Interorbital breadth			
Frontal chord	115	112	
Parietal chord	110	106	116
Occipital chord	109		100
Foramen magnum length	38		38.5
Foramen magnum breadth	30		34
Mastoid length L	33		
Mastoid length R			
Chin height		34	
Mandibular height L		36	

Table 2. Dental Inventory, Adult 1, Dubuque County, Burial Project 3189

Tooth	Presence	Attrition:	Attrition- molars:			
		I, C, P	Mes-buc	Mes-ling	Dis-ling	Dis-buc
MAXILLA:						
RM3	2		7	7	7	7
RM2	2		7	0	7	7
RM1	2		9	10	10	9
RP2	2	7				
RP1	2	8				
RC	2	8				
RI2	2	8				
RI1	5	9				
LM3	3		0	0	0	0
LM2	3		0	0	0	0
LM1	9		0	0	0	0
LP2	5	9				
LP1	9	9				
LC	2	8				
LI2	5	9				
LI1	9	9				

Dental Inventory Key:

Presence

1 Present but not in occlusion
2 Present, development completed, in occlusion
3 Missing, with no associated alveolar bone
4 Missing, with alveolus resorbing or fully resorbed: antemortem loss
5 Missing, with no alveolar resorption: postmortem loss
6 Missing, congenital absence
7 Present, damage renders measurements impossible
8 Present but unobservable (e.g. teeth in crypts)
9 Unobservable

Attrition (I, C, PM)

1 Unworn or small facets
2 Point or hairline of dentin
3 Dentin line of distinct thickness
4 Moderate dentin exposure, not resembling a line
5 Large dentin area with rim complete (two areas on premolars)
6 Large dentin area with enamel rim lost on one side (two areas coalesced on premolars)
7 Enamel rim lost on two sides (at least one side lost on premolars)
8 Complete loss of crown, no enamel remaining
9 Unobservable

Attrition (molars)

0 Unobservable
1 Wear facets invisible or very small
2 Wear facets large, but cusps and surface features still evident
3 Any cusp in quadrant is rounded, but not flat
4 Quadrant is worn flat, but no dentin is exposed (except pinprick-sized)
5 Quadrant is flat, dentin exposed on ¼ of quadrant
6 More than ¼ of dentin is exposed, with enamel ring still complete
7 Enamel is found on only two sides of quadrant
8 Enamel on only one side of quadrant, but enamel is still thick
9 Enamel on only one side of quadrant and it is very thin
10 No enamel remaining. Wear extends below the cervicoenamel junction onto the root

Table 3. Dental Inventory, Adult 2, 13DB40, Burial Project 3189

Tooth	Presence	Attrition:	Attrition- molars:			
		I, C, P	Mes-buc	Mes-ling	Dis-ling	Dis-buc
MAXILLA:						
RM3	3		0	0	0	0
RM2	3		0	0	0	0
RM1	3		0	0	0	0
RP2	3	9				
RP1	3	9				
RC	2	2				
RI2	2	3				
RI1	2	3				
LM3	6	0	0	0	0	0
LM2	2		0	0	0	0
LM1	2		0	0	0	0
LP2	2		9			
LP1	2		9			
LC	2		3			
LI2	2		2			
LI1	2		3			
MANDIBLE:						
LM3	2		0	0	0	0
LM2	2		0	0	0	0
LM1	2		0	0	0	0
LP2	2	9				
LP1	2	9				
LC	2	3				
LI2	2	2				
LI1	2	2				
RM3	3		0	0	0	0
RM2	3		0	0	0	0
RM1	3		0	0	0	0
RP2	3	9				
RP1	2	3				
RC	2	2				
RI2	2	2				
RI1	2	2				

Dental Inventory Key:
Presence
1 Present but not in occlusion
2 Present, development completed, in occlusion
3 Missing, with no associated alveolar bone
4 Missing, with alveolus resorbing or fully resorbed: antemortem loss
5 Missing, with no alveolar resorption: postmortem loss
6 Missing, congenital absence
7 Present, damage renders measurements impossible
8 Present but unobservable (e.g. teeth in crypts)
9 Unobservable
Attrition (I, C, PM)
1 Unworn or small facets
2 Point or hairline of dentin
3 Dentin line of distinct thickness
4 Moderate dentin exposure, not resembling a line
5 Large dentin area with rim complete (two areas on premolars)
6 Large dentin area with enamel rim lost on one side (two areas coalesced on premolars)
7 Enamel rim lost on two sides (at least one side lost on premolars)
8 Complete loss of crown, no enamel remaining
9 Unobservable
Attrition (molars)
0 Unobservable
1 Wear facets invisible or very small
2 Wear facets large, but cusps and surface features still evident
3 Any cusp in quadrant is rounded, but not flat
4 Quadrant is worn flat, but no dentin is exposed (except pinprick-sized)
5 Quadrant is flat, dentin exposed on ¼ of quadrant
6 More than ¼ of dentin is exposed, with enamel ring still complete
7 Enamel is found on only two sides of quadrant
8 Enamel on only one side of quadrant, but enamel is still thick
9 Enamel on only one side of quadrant and it is very thin
10 No enamel remaining. Wear extends below the cervicoenamel junction onto the root

Table 3. Dental Metrics (mm), Adult 2, 13DB40, Burial Project 3189

Tooth	Mesiodistal	Buccolingual	CEJ mesiodistal	CEJ buccolingual
MAXILLA:				
RM3				
RM2				
RM1				
RP2				
RP1				
RC	8.1	8.0	5.8	7.0
RI2	6.5		5.0	
RI1	7.7		5.9	
LM3				
LM2				
LM1				
LP2			4.5	
LP1			4.8	
LC	7.9		6.0	
LI2	6.5		5.0	
LI1	7.9			
MANDIBLE:				
LM3				
LM2				
LM1				
LP2			5.0	
LP1			4.6	
LC	6.7		5.0	
LI2	5.6		4.5	
LI1			3.8	
RM3				
RM2				
RM1				
RP2				
RP1	6.1		4.5	
RC	7.2		5.2	
RI2	5.9		4.5	
RI1	4.5		3.8	

Individual 3

The incomplete cranial remains of the subadult designated Individual 3 do not include a mandible, so this individual does not contribute to the MNI for the collection. Mandible 6 (recorded separately below) exhibits the same stage of dental development as the maxilla from Individual 3 and may represent the same individual. Two crania which are consistent in appearance with Individual 3 are visible in a photograph of the cluster of crania from Mound 1 at 13DB40, so this site is considered the likely provenience for the remains.

Young age is evident from the thin cross-section of the cranial vault bones. All of the vault sutures are open ectocranially, with some closure endocranially, particularly of the sagittal suture. A precise age estimate was determined from dental development. The permanent maxillary left canine and left first premolar appear to have been fully erupted at the time of death, while the left second premolar was unerupted, and the left second molar was just starting to erupt. This eruption pattern suggests an age of around 11.5 years. The permanent maxillary left second premolar crown is complete (though not fully observable), the root apices of the left first molar are ½ closed, and the left third molar crown is ½ to ¾ complete, suggesting an age of 10.5-11.5 years.

Given the individual's young age and limited remains, sex could not be determined. No indications of ancestry are observable, but context indicates the individual was Native American.

Individual 3 presents with two very shallow depressions on the vault, which appear to be well-healed depression fractures. The larger depression is found on the right half of the frontal, 45 mm superior to the margin of the right orbit. The depression is "eye shaped," oval with pointed ends oriented medially and laterally. Though the depression is extremely shallow (<1 mm) it is very well defined and measures 12.8 mm sagittally and 24 mm mediolaterally. The surface at the base of the depression appears slightly irregular when compared to the very smooth surrounding ectocranial surface, but there is no evidence of periosteal reaction surrounding the depression. This fracture is very well-healed and is almost invisible without oblique lighting. On the endocranial surface, the fracture is visible as a 13 mm linear defect oriented anteromedially to posterolaterally. This narrow linear depression has small vessel impressions radiating from the medial end; a bony spicule has grown over the depression on the lateral end.

The second, smaller depression is located on the ectocranial surface of the right parietal, 35 mm superior to the temporal suture. The defect is also extremely shallow but well-defined, with a slightly irregular texture on the floor of the depression. The depression is oval shaped and oriented antero-inferiorly to posterosuperiorly, measuring 15.7 mm on this axis and 11 mm perpendicularly. No abnormality is present on the endocranial surface at this location.

No dental pathology was observed on the few teeth present (see Table 5 for dental inventory). Only the maxillary left first molar provided dental metrics, measuring 11.3 mm mesiodistally and 12.1 mm buccolingually, with CEJ measurements of 8.8 mm and 12.1 mm.

Table 5. Dental Inventory, Individual 3, Dubuque County, Burial Project 3189.

Tooth	Presence	Development	Attrition:	Attrition- molars:			
			I, C, PM	Mes-buc	Mes-ling	Dis-ling	Dis-buc
MAXILLA:							
LM3	1	Cr 1/2-3/4		0	0	0	0
LM2	5			0	0	0	0
LM1	2	A 1/2		1	2	1	1
Ldm2	2	Ac		3	4	4	3
Ldm1	4			0	0	0	0
LP2	1	CrC+	1				
LP1	5		9				
Ldc	4		9				
LC	5		9				
LI2	5		9				
LI1	9		9				

Dental Inventory Key:

Presence

1 Present but not in occlusion
2 Present, development completed, in occlusion
3 Missing, with no associated alveolar bone
4 Missing, with alveolus resorbing or fully resorbed: antemortem loss
5 Missing, with no alveolar resorption: postmortem loss
6 Missing, congenital absence
7 Present, damage renders measurements impossible
8 Present but unobservable (e.g. teeth in crypts)
9 Unobservable

Development

Ci	Initial cusp formation
Cco	Coalescence of cusps
Coc	Cusp outline complete
Cr1/2	Crown ½ complete
Cr3/4	Crown ¾ complete
Crc	Crown complete
Ri	Initial root formation
Cli	Initial cleft formation
R1/4	Root length ¼
R1/2	Root length ½
R3/4	Root length ¾
Rc	Root length complete
A1/2	Apex ½ closed
Ac	Apical closure complete

Attrition (I, C, PM)

1 Unworn or small facets
2 Point or hairline of dentin
3 Dentin line of distinct thickness
4 Moderate dentin exposure, not resembling a line
5 Large dentin area with rim complete (two areas on premolars)
6 Large dentin area with enamel rim lost on one side (two areas coalesced on premolars)
7 Enamel rim lost on two sides (at least one side lost on premolars)
8 Complete loss of crown, no enamel remaining
9 Unobservable

Attrition (molars)

0 Unobservable
1 Wear facets invisible or very small
2 Wear facets large, but cusps and surface features still evident
3 Any cusp in quadrant is rounded, but not flat
4 Quadrant is worn flat, but no dentin is exposed (except pinprick-sized)
5 Quadrant is flat, dentin exposed on ¼ of quadrant
6 More than ¼ of dentin is exposed, with enamel ring still complete
7 Enamel is found on only two sides of quadrant
8 Enamel on only one side of quadrant, but enamel is still thick
9 Enamel on only one side of quadrant and it is very thin
10 No enamel remaining. Wear extends below the cervicoenamel junction onto the root

Adult 4

A tag found near the cranial remains designated Adult 4 indicates that the skull was found at the location of Wahlert High School, but this information is probably incorrect. The Adult 4 cranium is clearly shown in photographs of the cleaning and restoration of skulls subsequent to the amateur excavation of 13DB40, and therefore likely originated from the mounds.

The cranium has been reconstructed using a cream-colored substance which may be the "plastic wood" mentioned in notes about the amateur project. The reconstruction repaired shovel damage (large fractures with fresh edges found throughout the cranial vault) and also served to hold cranial elements together along open sutures. Some cranial metrics were still possible, and are found in Table 1.

This individual was a young adult. Though many sutures are completely open, including the temporal, sphenofrontal, and masto-occipital sutures, the maxillary right third molar is fully erupted and exhibits a wear facet on the lingual cusp, indicating that the individual was not an adolescent. The morphology of the nuchal crest, mastoid processes, and glabella all suggest the individual was male. An apparently projecting right zygomatic suggests Native American ancestry, but this projection may be enhanced by the reconstruction. Context supports a presumption of Native American ancestry.

Though the possibility that this cranium and maxillary remains originated from the same individual as Mandible 12 (a left mandible portion described in the mandible section below) was considered, this match was ruled out. Though both sets of dentition exhibit very slight wear, large facets are present on Adult 4's premolars while Mandible 12's premolars exhibit only very slight rounding of cusps. The age of Mandible 12 cannot be established any more specifically than >14.5-15.5 years, and the individual may be female, based on gracility of the alveolus. Mandible 13, though, cannot be excluded as a match for Adult 4. The only tooth present in Mandible 13, the left first molar, exhibits a level of wear similar to that of the maxillary right first molar of Adult 4. These two portions did not necessarily originate from the same individual, but are considered possible matches for the purpose of calculating the MNI; Mandible 13 (described below in the mandible section) is counted, but Adult 4 is not.

The right maxillary dental remains are well preserved and indicate excellent dental health (Tables 6 and 7). Wear is slight, no dental caries are present, and only a thin layer of calculus was observed (on all teeth).

No pathology was observed on the cranium. The unusually broad and deep vessel impressions observed on the endocranial surface of the left parietal, 11 mm posterior to the coronal suture, fall within the range of normal human variation. There is no defect on the ectocranial surface at this location.

Table 6. Dental Inventory, Adult 4, 13DB40, Burial Project 3189

Tooth	Presence	Attrition:	Attrition- molars:			
		I, C, P	Mes-buc	Mes-ling	Dis-ling	Dis-buc
MAXILLA:						
RM3	2		1	2	1	1
RM2	2		1	3	2	1
RM1	2		1	5	5	1
RP2	2	2				
RP1	2	3				
RC	2	3				
RI2	5	9				
RI1	5	9				

Dental Inventory Key:

Presence

1 Present but not in occlusion
2 Present, development completed, in occlusion
3 Missing, with no associated alveolar bone
4 Missing, with alveolus resorbing or fully resorbed: antemortem loss
5 Missing, with no alveolar resorption: postmortem loss
6 Missing, congenital absence
7 Present, damage renders measurements impossible
8 Present but unobservable (e.g. teeth in crypts)
9 Unobservable

Attrition (I, C, PM)

1 Unworn or small facets
2 Point or hairline of dentin
3 Dentin line of distinct thickness
4 Moderate dentin exposure, not resembling a line
5 Large dentin area with rim complete (two areas on premolars)
6 Large dentin area with enamel rim lost on one side (two areas coalesced on premolars)
7 Enamel rim lost on two sides (at least one side lost on premolars)
8 Complete loss of crown, no enamel remaining
9 Unobservable

Attrition (molars)

0 Unobservable
1 Wear facets invisible or very small
2 Wear facets large, but cusps and surface features still evident
3 Any cusp in quadrant is rounded, but not flat
4 Quadrant is worn flat, but no dentin is exposed (except pinprick-sized)
5 Quadrant is flat, dentin exposed on ¼ of quadrant
6 More than ¼ of dentin is exposed, with enamel ring still complete
7 Enamel is found on only two sides of quadrant
8 Enamel on only one side of quadrant, but enamel is still thick
9 Enamel on only one side of quadrant and it is very thin
10 No enamel remaining. Wear extends below the cervicoenamel junction onto the root

Table 7. Dental Metrics (mm) Adult 4, 13DB40, Burial Project 3189

Tooth	Mesiodistal	Buccolingual	CEJ mesiodistal	CEJ buccolingual
MAXILLA:				
RM3	9.9	11.7	7.2	11.4
RM2	11.2	12.0		
RM1	11.3	11.6		
RP2	6.2	8.8		
RP1	6.9	9.0		
RC		8.0		

Mandible 1

Mandible 1 is largely complete, with only the left ramus missing. The level of dental wear seen on the teeth present (n=10) is consistent with that of the maxillary teeth of Adult 1. Postmortem tooth loss and missing sections of maxillary alveolus make it impossible to confirm the match between the cranium and the mandible. Only the mandible is considered a contributor to the MNI. See Table 8 for dental inventory and Table 9 for dental metrics.

Dental wear is severe, with the loss of the enamel ring on many teeth. Several teeth were lost postmortem, but only one, the mandibular right second premolar, was lost antemortem and is fully resorbed. No carious lesions are present. A small amount of calculus is present on the left third molar, the only tooth with a substantial portion of the crown remaining.

Based on dental wear, the individual was likely an old adult. The mandible is robust but the mental eminence is not prominent. Sex is indeterminate.

Mandible 2

This mandible is almost complete, with only the left condyle absent. Mandible 2 was originally glued to the cranium designated Adult 1. However, attrition of the mandibular teeth is markedly less severe than that of the maxillary teeth of Adult 1. Therefore Mandible 2 represents a distinct individual.

Mandible 2 is coated with the same shellac-like substance as Adult 1, and the same orange epoxy-like material was used for repairs to the alveolus and left mandibular condyle. Glue obscures the occlusal surfaces of some teeth and prevented some dental measurements.

The mandible is fairly large and robust, with a squared chin and a somewhat prominent mental eminence, suggesting the individual is male. Age is likely older young adult to middle adult, as the anterior teeth have significant dentin exposure but the third molars are only worn flat.

Dental health was excellent. All teeth are present, and the individual had no carious lesions. Slight calculus was observed on all teeth. See Tables 8 and 9 for dental inventory and metrics.

Mandible 3

Mandible 3 consists of a portion of the right mandibular ramus with alveolar sockets for the first premolar through third molar. The vertical ramus is absent. The first premolar and third molar were lost postmortem and the sockets are incomplete. The third molar socket is angled anteriorly, and there is a contact facet extending onto the distal root surface of the second molar. See Tables 8 and 9 for dental inventory and metrics.

Sex is indeterminate. Since the two molar crowns are worn down almost to the roots, with a thin enamel rim remaining in places, the individual was likely an old adult (>50 years). No caries present. Slight calculus was observed on the right second molar.

Mandible 4

Mandible 4 consists of the posterior portion of the right mandibular ramus including the alveolar sockets for the second premolar through second molar. The third molar appears to be congenitally absent, as there is no space in the alveolus for the tooth. The second premolar was lost postmortem.

Sex is indeterminate based on the small portion of mandible present. Age is indeterminate, as glue obscures details of the occlusal surfaces of the two molars and prevents observation of dental wear. The individual is likely an adult, as the M1 surface appears to have been worn flat. The individual was probably not an old adult, as both molars retain substantial crown height. No carious lesions are present. See Tables 8 and 9 for dental inventory and metrics.

Mandible 5

Mandible 5 consists of a portion of the right mandibular ramus including most of the vertical ramus and alveolar sockets for the canine through third molar. The small portion of the second incisor socket that remains indicates the tooth was lost postmortem. All the other sockets have teeth in situ.

Age is estimated as middle adult. All teeth besides the third molar show substantial dentin exposure, indicating the individual is not a young adult. Only the canine and first molar have lost substantial crown height (approximately ½ original height) while the other teeth exhibit more moderate wear, so the individual is probably not an old adult. Sex is indeterminate; the mandibular eminence is not present and the mandibular angle could not be measured.

No carious lesions or other pathology were noted. Calculus accumulation on the molars, particularly the lingual surfaces, is greater than that observed on other dental remains in this collection. See Tables 8 and 9 for dental inventory and metrics.

Mandible 6

Mandible 6 consists of a portion of the right mandibular ramus and the chin. The alveolar portion present has several sockets for teeth lost postmortem, including the permanent left and right canines and all four incisors. The permanent right first premolar and first molar are in situ. The roots of the deciduous right second molar, still in situ, were beginning to resorb at the time of death, and the right second premolar crown is just visible in the crypt below. This eruption pattern suggests an age of around 11.5 years, while the development of the first premolar (root ¾) indicates an age of 10.5-12.5 years. Based on dental development, Mandible 6 may represent the same subadult as the cranium and maxillary dentition designated Individual 3. See Tables 10 and 12 for dental inventory and metrics.

No caries, calculus, or other pathology observed.

Mandible 7

Mandible 7 consists of part of the right mandibular ramus and chin. Partial alveolar sockets are present from the left canine to the right first molar, but no teeth are in situ. All sockets were filled with dirt when the collection was examined, suggesting the teeth were lost postmortem but prior to excavation. The superior portion of the alveolus is absent, leaving only the most inferior portions of the sockets. The generally small size of the remainder of the ramus—as judged by the short distance between the mental foramen and the inferior margin of the mandible—suggests the individual may be a subadult. Additionally, there is normal, dense bone where the right second premolar socket should be, either because the premolar remains unerupted in a crypt or was lost antemortem and resorbed.

Age cannot be determined more specifically than possibly subadult. Sex is indeterminate. No pathology is evident.

Mandible 8

Mandible 8 consists of the posterior-most portion of the right mandibular ramus of a subadult and the coronoid process. Only two alveolar sockets are present, that of the unerupted right first molar and the crypt that would have held the absent second molar crown. The first molar roots are ¼ complete, indicating an age of 4.5-6.5 years. The size of the second molar crypt suggests the crown was not complete, which supports this age estimate. For dental metrics, see Table 12.

Mandible 9

Mandible 9 consists of a nearly complete left mandibular ramus and partial right mandibular ramus. All of the erupted dentition is deciduous, and unerupted permanent crowns are visible where just beginning to erupt (first molars) and where the alveolus is broken (right incisors and canine). It does not appear that any deciduous teeth were shed prior to death, which suggests an age of less than 6.5 years. The permanent first molar roots are ¼ complete (4.5-6.5 years), the canine crown is complete (5.5-6.5 years), and the root of the

second incisor was just beginning to form (4.5-5.5 years), indicating the individual was around 5.5 years old at death. See Tables 10 and 12 for dental inventory and metrics.

No calculus, carious lesions, or enamel defects were observed on the erupted teeth. The individual exhibits a deflecting wrinkle on each erupting first molar.

Mandible 10

Mandible 10 consists of a partial right mandibular ramus and vertical ramus with the condyle intact. Alveolar sockets for the right deciduous second molar through permanent second molar are present. The deciduous second molar is fully erupted, while the permanent first molar crown is partially concealed in its crypt. The first molar crown appears to be ½ complete or greater. The small empty crypt for the second molar indicates the crown was forming at the time of death. The first premolar crown is difficult to visualize in the crypt but appears to be between ½ complete and complete. Based on these characteristics, the individual was likely between 2.5 and 4.5 years at the time of death. The deciduous second molar has little wear and no caries or calculus. See Tables 10 and 12 for dental inventory and metric.

Though there are no duplicated alveolar sockets between Mandible 10 and Mandible 11, and though they are similar in age, the lack of refit and differences in the morphology of the deciduous second molars indicate these mandibular portions represent distinct individuals. Also, Mandible 11 appears to represent a slightly younger individual.

Mandible 11

Mandible 11 consists of a nearly complete left mandibular ramus including the vertical ramus with the coronoid process and part of the condyle and a refitting chin fragment. The portion present has alveolar sockets for the deciduous left first and second molars, left first incisor, and right incisors, canine, and first molar. Both deciduous first molars and the left first incisor were lost postmortem.

The permanent left first molar is just visible in the crypt, and the crown outline is complete (and possibly more developed). The deciduous second molar is fully erupted, the deciduous canine root is ¾ complete, and the apex of the deciduous first incisor root is ½ closed. This development suggests an age of 1.5-2.5 years. No carious lesions, calculus, or enamel defects were observed. Dental inventory and metrics are found in Tables 10 and 12.

Mandible 12

Mandible 12 consists of a partial left mandibular ramus including the chin portion. Alveolar sockets for permanent left second molar through right canine are present, all with teeth in situ except the left second molar and right canine, which were lost postmortem. See Tables 10 and 12 for dental inventory and metrics.

The dental remains exhibit very slight wear. The roots of the left canine and second premolar have closed apices, indicating the individual was older than 14.5-15.5 years. It is uncertain whether the individual was an older adolescent or young adult. The shape of the incomplete chin suggests the individual may have been female.

The teeth exhibit excellent health, with no caries or alveolar resorption. Calculus is present on the buccal and lingual surfaces of all teeth. Pink staining on the labial calculus of the incisors and canine suggests that ochre was applied to the remains.

Mandible 13

Mandible 13 consists of a small portion of the left mandibular ramus, including the alveolar sockets from the permanent left canine through the left second molar. All of these teeth were lost postmortem except for the left first molar, which exhibits slight wear and no caries or calculus. The empty tooth sockets were filled with soil, suggesting the teeth were lost prior to excavation. See Tables 8 and 9 for dental inventory and metrics.

The sex of this individual is unknown. Age is estimated as young adult based on the slight wear of the first molar. This wear is consistent with that of the maxillary first molar of Adult 4, a young adult whose age was determined by cranial suture closure and more complete dental remains. Due to the similarity in dental wear and the lack of duplicated portions, Mandible 13 is considered a possible match for the cranium designated Adult 4.

Mandible 14

Mandible 14 consists of a portion of the left mandibular ramus and part of the coronoid process. The alveolar sockets for the permanent left second premolar through left second molar are present, with the premolar lost postmortem. In the distal alveolus, an opening that was enlarged by postmortem damage reveals the crypt for the third molar. Whatever portion of the third molar crown was completed at the time of death was lost postmortem.

An age estimate of 11.5-13.5 years is based on the nearly complete eruption and ¾ root completion of the second molar. Additionally, the second premolar appears to have erupted, based on the shape of the partial empty socket. Sex is unknown. No pathology was observed. See Tables 10 and 12 for dental inventory and metrics.

Though the age estimate for Mandible 14 overlaps that of Mandible 6 (10.5-12.5 years) and though there are no duplicated portions, these two mandibular fragments represent distinct individuals. The dental development of Mandible 14 is slightly more advanced, and the size and morphology of the first molars from the two mandibular specimens does not match.

Maxilla 1

Maxilla 1 consists of most of the right maxillary alveolus and the right half of the nasal aperture. Alveolar sockets for the permanent right central incisor through second molar are present. Most of the permanent dentition is unerupted, but the crowns are visible in the damaged alveolus. The deciduous teeth are absent, but it is not possible to determine which were shed naturally and which were lost postmortem. See Tables 11 and 12 for dental inventory and metrics.

The right central incisor and first molar appear to have been fully erupted at the time of death, though the lateral incisor and second molar were just beginning to emerge from the alveolus. Age is estimated to be approximately 7.5-9.5 years, based on this eruption pattern.

Though the collection MNI is primarily based on mandibles, this maxilla represents an additional individual, as it belongs to a subadult of an age not represented by any of the mandibles.

There appears to be a very small amount of calculus on the mesial interproximal surface of the first molar. No carious lesions were observed on this erupted tooth, and no enamel defects are present on any of the observable crowns (second incisor, first premolar, first molar).

Table 8. Dental Inventory, Adult Mandibles, 13DB40, Burial Project 3189

Tooth	Presence	Attrition:	Attrition- molars:			
		I, C, P	Mes-buc	Mes-ling	Dis-ling	Dis-buc
MANDIBLE 1:						
LM3	2		7	8	9	7
LM2	2		10	10	10	10
LM1	2		10	10	10	10
LP2	2	7				
LP1	2	8				
LC	2	7				
LI2	5	9				
LI1	2	7				
RM3	5		0	0	0	0
RM2	5		0	0	0	0
RM1	5		0	0	0	0
RP2	4	9				
RP1	2	7				
RC	2	8				
RI2	2	7				
RI1	5	9				
MANDIBLE 2:						
LM3	2		4	4	4	4
LM2	2		5	5	5	5
LM1	2		6	6	6	5
LP2	2	3				
LP1	2	3				
LC	2	4				
LI2	2	3				
LI1	2	3				
RM3	2		0	0	0	0
RM2	2		5	4	5	5
RM1	2		6	6	5	0
RP2	2	4				
RP1	2	3				
RC	2	4				
RI2	2	3				
RI1	3	3				
MANDIBLE 3:						
RM3	5		0	0	0	0
RM2	2		7	7	8	10
RM1	2		9	8	9	7
RP2	2	6				
RP1	5	9				
RC	3	9				
RI2	3	9				
RI1	3	9				
MANDIBLE 4:						
RM3	6		0	0	0	0
RM2	2		0	0	0	0
RM1	2		0	0	0	0
RP2	5	9				
RP1	3	9				
RC	3	9				
RI2	3	9				
RI1	3	9				

Table 8. Dental Inventory, Adult Mandibles, 13DB40, Burial Project 3189, cont.

Tooth	Presence	Attrition:	Attrition-molars:			
		I, C, P	Mes-buc	Mes-ling	Dis-ling	Dis-buc
MANDIBLE 5:						
RM3	2		4	5	6	5
RM2	2		7	7	7	7
RM1	2		8	8	8	7
RP2	2	6				
RP1	2	6				
RC	2	6				
RI2	5	9				
RI1	3	9				
MANDIBLE 13:						
LM3	3		0	0	0	0
LM2	5		0	0	0	0
LM1	2		4	2	2	4
LP2	5	9				
LP1	5	9				
LC	5	9				
LI2	3	9				
LI1	3	9				

Dental Inventory Key:
Presence
1 Present but not in occlusion
2 Present, development completed, in occlusion
3 Missing, with no associated alveolar bone
4 Missing, with alveolus resorbing or fully resorbed: antemortem loss
5 Missing, with no alveolar resorption: postmortem loss
6 Missing, congenital absence
7 Present, damage renders measurements impossible
8 Present but unobservable (e.g. teeth in crypts)
9 Unobservable
Attrition (I, C, PM)
1 Unworn or small facets
2 Point or hairline of dentin
3 Dentin line of distinct thickness
4 Moderate dentin exposure, not resembling a line
5 Large dentin area with rim complete (two areas on premolars)
6 Large dentin area with enamel rim lost on one side (two areas coalesced on premolars)
7 Enamel rim lost on two sides (at least one side lost on premolars)
8 Complete loss of crown, no enamel remaining
9 Unobservable
Attrition (molars)
0 Unobservable
1 Wear facets invisible or very small
2 Wear facets large, but cusps and surface features still evident
3 Any cusp in quadrant is rounded, but not flat
4 Quadrant is worn flat, but no dentin is exposed (except pinprick-sized)
5 Quadrant is flat, dentin exposed on ¼ of quadrant
6 More than ¼ of dentin is exposed, with enamel ring still complete
7 Enamel is found on only two sides of quadrant
8 Enamel on only one side of quadrant, but enamel is still thick
9 Enamel on only one side of quadrant and it is very thin
10 No enamel remaining. Wear extends below the cervicoenamel junction onto the root

Table 9. Dental Metrics (mm) Adult mandibular dental metrics, 13DB40, Burial Project 3189

Tooth	Mesiodistal	Buccolingual	CEJ mesiodistal	CEJ buccolingual
MANDIBLE 1:				
LC			5.9	7.5
MANDIBLE 2:				
LM3	11.0	10.6		
LP2	7.0	9.5		
LP1	7.3	8.8	5.9	7.5
LC	8.2	8.6	6.2	8.8
LI2	6.6	6.7	4.5	6.7
LI1	6.1	6.2		5.9
RM3	10.9	10.7		
RP2	7.5	9.2		
RP1	6.7	8.8	6.5	
RC	7.5	8.7	6.3	8.6
MANDIBLE 3:				
RP2			5.6	8.6
MANDIBLE 4:				
RM2	11.7	11.1	9.6	8.6
RM1			9.5	8.8
MANDIBLE 5:				
RM3			9.5	
RM2			9.8	
RM1			9.2	
RP2			5.0	7.9
RP1			4.9	7.7
RC			5.5	7.9
MANDIBLE 13:				
LM1	11.0	10.5	9.8	9.1

Table 10. Dental Inventory, Subadult mandibles, 13DB40, Burial Project 3189

Tooth	Presence	Development	Attrition:	Attrition- molars:			
			I, C, PM	Mes-buc	Mes-ling	Dis-ling	Dis-buc
MANDIBLE 6:							
Ldc	4						
LC	5			0	0	0	0
Ldi2	4						
Ldi1	4						
LI2	5		9				
LI1	5		9				
RM3	3			0	0	0	0
RM2	5			0	0	0	0
RM1	2			3	2	1	1
Rdm2	2	Ac		8	7	8	7
Rdm1	4						
RP2	8		9				
RP1	2	R3/4	1				
Rdc	4						
RC	5		9				
Rdi2	4						
Rdi1	4						
RI2	5		9				
RI1	5		9				

Table 10. Dental Inventory, Subadult mandibles, 13DB40, Burial Project 3189, cont.

Tooth	Presence	Development	Attrition:	Attrition-molars:			
			I, C, PM	Mes-buc	Mes-ling	Dis-ling	Dis-buc
MANDIBLE 7:							
LC	5		9				
LI2	5		9				
LI1	5		9				
RM1	5			0	0	0	0
RP2	9						
RP1	5		9				
RC	5		9				
RI2	5		9				
RI1	5		9				
MANDIBLE 8:							
RM2	5			0	0	0	0
RM1	1	R1/4		1	1	1	1
MANDIBLE 9:							
LM3	9						
LM2	8			0	0	0	0
LM1	1	9		1	1	1	1
Ldm2	2			1	2	2	1
Ldm1	2			2	2	2	1
LP2	9						
LP1	9						
Ldc	2		2				
LC	9						
Ldi2	2		1				
Ldi1	5		9				
LI2	9						
LI1	8		9				
RM3	9						
RM2	9						
RM1	1	R1/4		1	1	1	1
Rdm2	2			2	1	1	2
Rdm1	2			2	2	2	2
RP2	9						
RP1	9						
Rdc	3		9				
RC	1	Crc	1				
Rdi2	3		9				
Rdi1	5		9				
RI2	1	Ri	1				
RI1	8		9				
MANDIBLE 10:							
LP1	1	Cr3/4					
RM2	5			0	0	0	0
RM1	1						
Rdm2	2			1	1	1	1
RP2	9						
MANDIBLE 11:							
LM1	1	Coc					
Ldm2	2			1	1	1	1
Ldm1	5			0	0	0	0
LP2	9						
LP1	9						

Table 10. Dental Inventory, Subadult mandibles, 13DB40, Burial Project 3189, cont.

Tooth	Presence	Development	Attrition:	Attrition-molars:			
			I, C, PM	Mes-buc	Mes-ling	Dis-ling	Dis-buc
LC	5		9				
Ldi2	3		9				
Ldi1	5		9				
LI2	8		9				
LI1	9						
Rdm2	3			0	0	0	0
Rdm1	5			0	0	0	0
Rdc	2		2				
RC	5		9				
Rdi2	2		5				
Rdi1	2		3				
MANDIBLE 12:							
LM3	3			0	0	0	0
LM2	5			0	0	0	0
LM1	2			3	3	2	3
LP2	2	Ac	1				
LP1	2	Ac	1				
LC	2	Ac	2				
LI2	2	Ac	2				
LI1	2	Ac	2				
RC	5		9				
RI2	2	Ac	2				
RI1	2	Ac	2				
MANDIBLE 14:							
LM3	5			0	0	0	0
LM2	1	R3/4		1	1	1	1
LM1	2			2	1	1	2
LP2	5			0	0	0	0

Dental Inventory Key:

Presence

1 Present but not in occlusion
2 Present, development completed, in occlusion
3 Missing, with no associated alveolar bone
4 Missing, with alveolus resorbing or fully resorbed: antemortem loss
5 Missing, with no alveolar resorption: postmortem loss
6 Missing, congenital absence
7 Present, damage renders measurements impossible
8 Present but unobservable (e.g. teeth in crypts)
9 Unobservable

Development

Ci Initial cusp formation
Cco Coalescence of cusps
Coc Cusp outline complete
Cr1/2 Crown ½ complete
Cr3/4 Crown ¾ complete
Crc Crown complete
Ri Initial root formation
Cli Initial cleft formation
R1/4 Root length ¼
R1/2 Root length ½
R3/4 Root length ¾
Rc Root length complete
A1/2 Apex ½ closed
Ac Apical closure complete

Attrition (I, C, PM)

1 Unworn or small facets
2 Point or hairline of dentin
3 Dentin line of distinct thickness
4 Moderate dentin exposure, not resembling a line
5 Large dentin area with rim complete (two areas on premolars)
6 Large dentin area with enamel rim lost on one side (two areas coalesced on premolars)
7 Enamel rim lost on two sides (at least one side lost on premolars)
8 Complete loss of crown, no enamel remaining
9 Unobservable

Attrition (molars)

0 Unobservable
1 Wear facets invisible or very small
2 Wear facets large, but cusps and surface features still evident
3 Any cusp in quadrant is rounded, but not flat
4 Quadrant is worn flat, but no dentin is exposed (except pinprick-sized)
5 Quadrant is flat, dentin exposed on ¼ of quadrant
6 More than ¼ of dentin is exposed, with enamel ring still complete
7 Enamel is found on only two sides of quadrant
8 Enamel on only one side of quadrant, but enamel is still thick
9 Enamel on only one side of quadrant and it is very thin
10 No enamel remaining. Wear extends below the cervicoenamel junction onto the root

Table 11. Dental Inventory, Maxilla 1, 13DB40, Burial Project 3189

Tooth	Presence	Development	Attrition:	Attrition- molars:			
			I, C, PM	Mes-buc	Mes-ling	Dis-ling	Dis-buc
MAXILLA:							
RM3	9						
RM2	1			0	0	0	0
RM1	2			1	1	1	1
RP2	8		9				
RP1	1		1				
RC	8		9				
RI2	1		1				
RI1	5		9				

Table 12. Subadult Dental Metrics (mm), 13DB40, Burial Project 3189

Tooth	Mesiodistal	Buccolingual	CEJ mesiodistal	CEJ buccolingual
MAXILLA 1:				
LM1	10.9	11.5	8.7	10.9
MANDIBLE 6:				
RM1	13.0	11.8	10.8	11.3
RP1	7.2	7.7	5.2	7.0
MANDIBLE 8:				
RM1	11.5			
MANDIBLE 9:				
Ldm2	10.8	9.0	9.2	7.4
Ldm1	8.4	7.4	7.2	
Ldc	6.0	5.5	5.2	4.5
Ldi2	4.2	4.2	3.5	4.0
Rdm2	10.2	9.6	8.6	7.6
Rdm1	8.5	7.5	6.9	6.0
MANDIBLE 10:				
Rdm2	10.4	9.8	8.4	8.0
MANDIBLE 11:				
Ldm2	11.2	9.2	8.7	7.3
Rdc	6.3	4.9	4.9	4.7
Rdi2	4.9	4.6	4.4	4.6
Rdi1	4.6	4.1	4.3	3.8
MANDIBLE 12:				
LM1	11.4	11.0	9.6	9.3
LP2	7.6	8.7	5.6	7.8
LP1	7.2	8.0	5.2	7.0
LC	7.7	7.9	6.4	8.0
LI2	6.6	6.7	5.2	6.7
LI1	5.6	5.8	4.1	6.0
RI2	6.6	6.7	4.9	6.8
RI1	5.3	5.9	3.9	5.9
MANDIBLE 14:				
LM2	12.8	10.9	10.4	9.6
LM1	12.4	11.2	10.0	9.2

UNASSOCIATED DENTAL REMAINS

Fifteen loose teeth present in the collection could not be associated with any of the maxillary or mandibular portions (Table 13). Five teeth are fully formed and likely represent adults. Ten teeth originated from subadults, potentially ranging in age from 2.5 to 13.5 years. A group of three anterior mandibular teeth—right incisors and left central incisor—represent a single adult (Articulating Unit 1), based on size, morphology, coloring, and wear. These unassociated dental remains do not duplicate any teeth listed with the individuals above, nor do they represent subadults of ages not already represented by the individuals above. Therefore, these loose teeth do not contribute any additional numbers to the MNI.

POSTCRANIAL REMAINS

Commingled postcranial remains from this collection include 209 whole elements and identifiable fragments. In all, 140 fragments represent adult elements and 69 fragments represent subadult elements (Tables 14 and 15). The MNI for adult postcranial remains is four, based on left femora and left tali. The MNI for subadults is also four, including one individual newborn-three years, one 3.0-6.0 years, and two adolescents approximately 12-18 years. However, these postcranial remains do not contribute to the MNI for the collection, as individuals of these ages are represented by the cranial and mandibular remains enumerated above.

In addition to the group of articulating teeth, five sets of articulating postcranial elements were identified in the collection, all of which represented adults. Articulating Unit (AU) 2 consists of a gracile right talus and calcaneus, possibly representing a female. AU 3 includes right intermediate and lateral cuneiforms. Right second and third metatarsals make up AU 4. AU 5 consists of three upper thoracic vertebrae (likely T1-T3) with moderately severe degenerative lipping on the superior articular facets of the uppermost vertebra. AU 6 includes four articulating lower vertebrae, three of which were glued together in the past.

Five Bilateral Units (BU) were also identified in the collection. A pair of adult humeri make up BU 1. BU 2 consists of an adolescent right tibia with a partially fused proximal epiphysis and a left proximal tibial epiphysis that was in the process of fusing at the time of death. The distal epiphysis was mostly fused, suggesting an age of 14-18 years. A pair of adult tibiae are designated BU 3. BU 4 consists of left and right unfused distal femoral epiphyses, which represent an individual between the ages of 12 and 18 years. BU 5 consists of a matching pair of tali, including the right talus of AU 2. The complete reconstructed unit, then, includes the left talus, right talus, and right calcaneus of an adult, possibly female.

Summary

Commingled cranial, dental, and postcranial remains from three proveniences—13DB40 (mound site), 13DB1140 (isolated cranial remains), and Richards Mound Group in Wisconsin—represent a minimum of 16 individuals, including seven adults, eight subadults, and one possible subadult. Sex could not be determined for most of the adult individuals, though at least one female and three males are represented. The ages of the subadults, based on dental eruption and tooth development stages, are 1.5-2.5 years, 2.5-4.5 years, 4.5-6.5 years, around 5.5 years, 7.5-9.5 years, 10.5-11.5 years, 11.5-13.5 years, and >14.5-15.5 years. Pathology includes slight degenerative joint disease observed on few elements, and osteomyelitis on a right third metacarpal. All remains are presumed to be Native American based on provenience, though little is known about the recovery of the isolated cranium from the location of Wahlert High School. Projecting zygomatics observed on Adults 1 and 4, as well as the shoveled incisors see in the dentition of Adult 2, support the presumption of Native American ancestry.

References Cited

University of Iowa, Office of the State Archaeologist (UI, OSA)
2016 Burial Project 3189. On file, Office of the State Archaeologist, University of Iowa, Iowa City.

Table 13. Commingled Dental Remains, Dubuque County, Burial Project 3189

	# Left	# Right	# Unsided	Age Range
MAXILLA:				
M1		1		Adult
M1	1			3.5-6.5 yr
dm2		1		2.5-11.5 yr
MANDIBLE:				
M1 or M2	1	1		6.5-13.5 yr
M1 or M2		1		5.5-12.5 yr
M1 or M2		1		2.5-8.5 yr
P2		1		10.5-13.5 yr
P1	1			Adult
dm2		2		2.5-8.5 yr
C		1		8.5-12.5 yr
I2		1		Adult
I1	1	1		Adult

Table 14. Adult Commingled Remains, Dubuque County and Wisconsin, Burial Project 3189

Element	Number of Fragments/ Specimens	MNE Left	MNE Right	MNE Midline	MNE Unsided
Cranium/mandible	19			2	
Axis	1			1	
Thoracic vertebrae	8			7	
Lumbar vertebrae	3			1	
Ribs 2-12	10	3	5		1
Clavicle	2		2		
Scapula	2	1	1		
Humerus	5	1	2		
Carpals	6	3	3		
Metacarpals	17	5	11		1
Hand phalanges	24	3	3		18
Femur	5	4			
Patella	2	2			
Tibia	4	2	2		
Fibula	5	3			
Talus	5	4	1		
Calcaneus	2	1	1		
Tarsals	10	2	8		1
Metatarsals	7	1	5		1
Foot phalanges	3	1	1		1

Table 15. Subadult Commingled Remains, Dubuque County and Wisconsin, Burial Project 3189

Element	Number of Fragments/ Specimens	MNE Left	MNE Right	MNE Midline	MNE Unsided	Age Range
Cranium/mandible	47			4		subadult
Cranium/mandible	1			1		subadult?
Atlas	2			1		3-6 yr
Lumbar vertebrae	2			2		3-7 yr
Radius	1				1	0-3 yr
Hand phalanges	2				2	subadult
Femur	2	1	1			12-18 yr
Tibia	2	1	1			14-18 yr
Tibia	1		1			<18 yr
Fibula	5	1	1			14-20 yr
Fibula	3				2	subadult?
Fibula	1	1				10-18 yr

Human Remains Recovered from 13DK96, a Woodland Occupation Site in Dickinson County, Iowa

Jennifer E. Mack

Three human bone fragments recovered from 13DK96 during field school excavations in 2015 and 2016 represent a minimum of one individual, a child approximately 10 to 12 years old.

Background

During the summers of 2014, 2015, and 2016, the Iowa Lakeside Laboratory conducted a field school, sponsored by the University of Iowa Department of Anthropology and Office of the State Archaeologist (OSA), at the location of 13DK96, a Middle to Late Woodland occupation site in Dickinson County, Iowa (Figure 1). During laboratory processing of materials recovered from these excavations, three small human bone fragments were identified and transferred to the OSA-BP for analysis and repatriation (UI, OSA 2016). These fragments were not recovered from burial contexts or other archaeological features.

Osteological Analysis

A deciduous maxillary right first molar was recovered from Test Unit 8, level 5, in 2015. The crown is heavily worn, with dentin exposure on ¼ to more than ¼ of each quadrant. The mesial portion of the root is resorbed to the CEJ. Approximately 1.5 mm length of root is still present on the distal margin of the crown, and the appearance of the remaining edges suggests a mixture of resorption and postmortem damage. This tooth may have been shed naturally, which generally occurs around the age of 10 to 12 years. It is also possible that the individual died just before the tooth loss would have occurred.

A cranial fragment was also recovered from Test Unit 8 in 2015, from level 4. This fragment was identified as a possible temporal fragment primarily consisting of the external auditory meatus. The small diameter of the meatus (8 mm) would be consistent with that of a subadult or gracile adult.

The third human element is the distal portion of a hand phalanx recovered from the northwest quadrant of Test Unit 20 (10-15 cmbs) in 2016. This location is approximately two to three meters southeast of the unit from which the deciduous tooth and cranial fragment were recovered. The gracile fragment may be from a proximal or intermediate phalanx. The level of development cannot be determined without the proximal portion. Based on the overall size, the possibility that the phalanx originated from a subadult of the same age as the tooth cannot be ruled out. Therefore, the minimum number of individuals represented by the remains from 13DK96 is one. No pathological conditions were observed on the remains.

References Cited

University of Iowa, Office of the State Archaeologist (UI, OSA)
2016 Burial Project 3205. On file, Office of the State Archaeologist, University of Iowa, Iowa City.

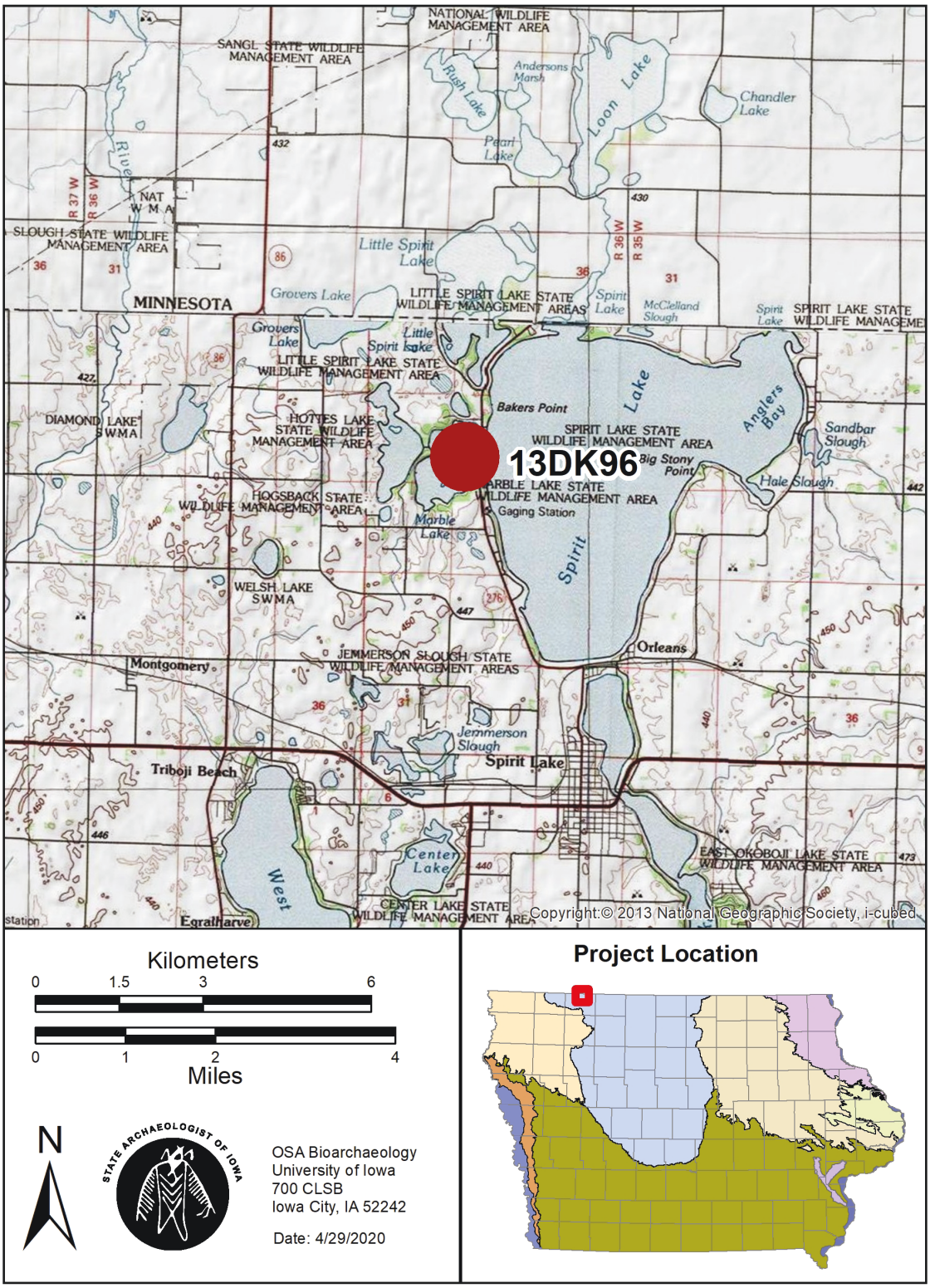

Figure 1. Location of 13DK96.
From USGS Okoboji, Dickinson County, Iowa (1982), 7.5' series quadrangle map. Scale 1:100,000.

Amputated Lower Leg Recovered from an Old City Dump, Battle Creek, Ida County, Iowa

Jennifer E. Mack

Articulated elements of a lower left leg were discovered in historic trash deposits associated with a city dump just south of Battle Creek, Iowa. Pathological bone alterations and the previous recovery of medical waste items from the dump site indicate that the bones represent an amputated lower limb. The dump was active from around 1890-1940, and a possible identification of the affected individual dates the amputation to 1927.

Background

On April 21, 2020, a private citizen conducting an excavation in the refuse deposits of the historic Battle Creek city dump (Figure 1) reported to the Ida County Sheriff's Department the discovery of a human tibia. Deputies inspected the general area where the bone was discovered in a pile of slumped soil. Seeing no additional human remains, they took possession of the tibia and sent it to the Iowa Office of the State Medical Examiner. A forensic anthropologist determined that the remains were too old to be of forensic significance (IOSME Case # 20-02299). The remains were subsequently transferred to the OSA Bioarchaeology Program (UI, OSA 2020).

On May 1, 2020, Bioarchaeology Program staff visited the site of the discovery to determine the original context of the human remains and to collect any additional remains that might be present. The site was found to be an active excavation, as the landowner had been using heavy equipment for the last five years to expose rubbish layers for the collection of bottles and other historic objects. In some places, the trash deposits were over five feet deep. A search of the slumped soil at the location of the tibia discovery uncovered no additional human remains. However, the styloid process of a fibula was observed in the profile of intact dump deposits. Excavation revealed an attached, articulated foot. No other elements were found in the profile. Pronounced pathology was visible on the recovered elements even in situ. This evidence, in conjunction with the landowner's report of finding numerous glass syringes, vials, and other types of medical waste likely discarded by the former Battle Creek hospital, suggests that the remains represent an amputated limb.

The landowner stated that he had found no documents confirming the use of this property as a dump by the city of Battle Creek. A complaint published in the local paper around 1890 appears to reference the dump but gives no further details. An examination of this area (Section 27, Township 87 North, Range 41 West) on maps from 1906, 1920, and 1930 does not show any indication of the type of land use. An aerial photograph from around 1938 clearly shows disturbance in the area and a half-circle drive. According to locals, the re-routing of the Maple River would have ended use of the dump, and a new one was established in an adjacent field. The landowner believes all datable artifacts recovered from the dump are consistent with a use period from 1890-1940.

The articulated elements were found lying in contact with a layer of dense ash which the landowner claims was dumped from the plant that once produced both electricity and municipal steam heating for downtown Battle Creek. A historical context study of this steam system dates usage of the plant, which was located about 500 m to the northwest of the dump, from 1914 to around 1940 (Rogers and Price 2011). As ash layers were observed both above and below the articulated skeletal remains, the amputation is believed to date to sometime between 1914 and 1940.

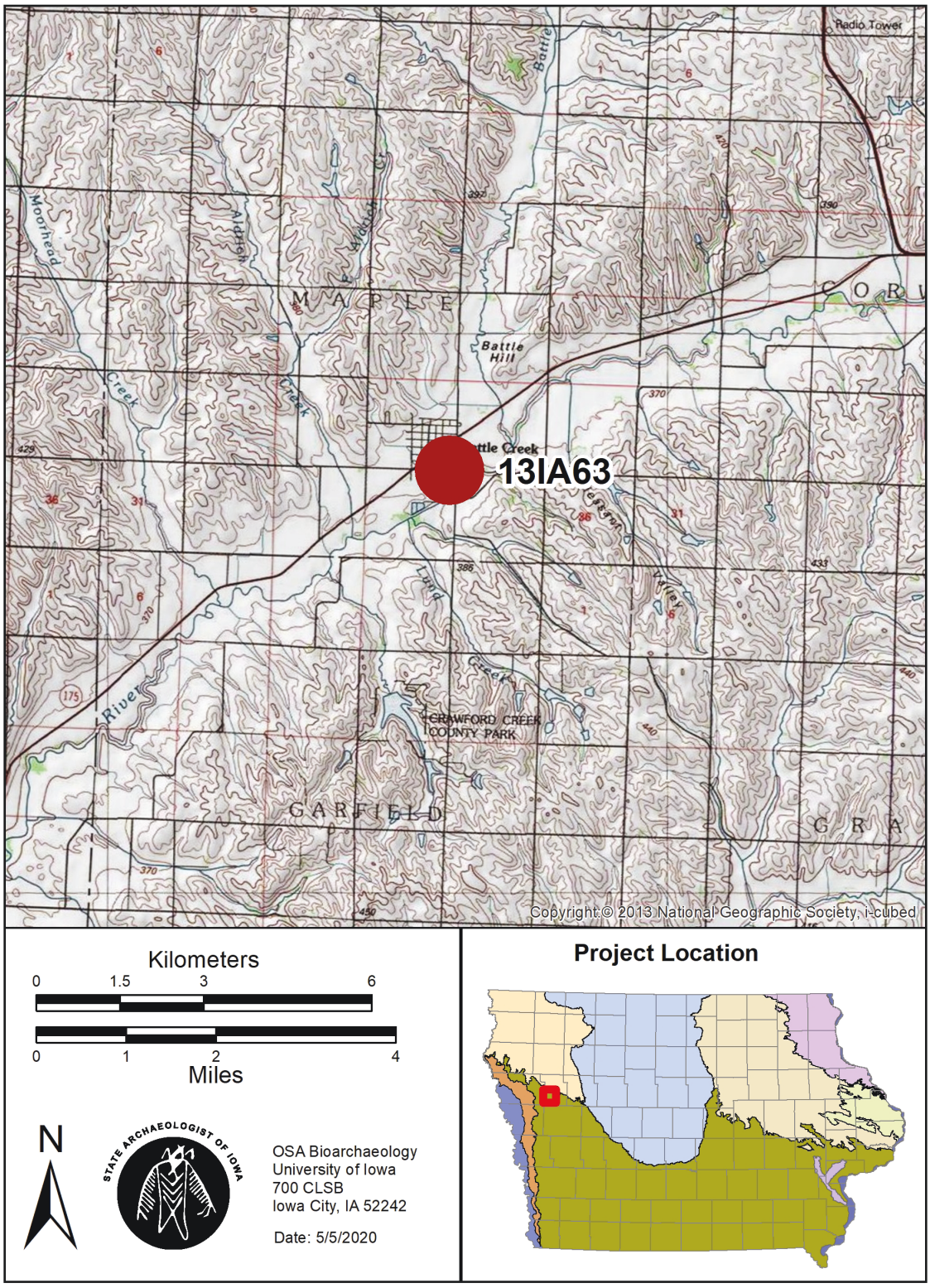

Figure 1. Findspot of human remains, 13IA63.
From USGS Battle Creek (1982), 7.5' series quadrangle map. Scale 1:100,000.

Osteological Analysis

The human remains recovered include the left tibia, fibula, talus, calcaneus, navicular, cuboid, and cuneiforms, and the metatarsals and phalanges of the second through fifth digits. The metatarsal and phalanges of the first digit are absent, as is one of the other distal phalanges (probably from the second digit). The long bones, talus, calcaneus and phalanges are in good condition, with most of the cortex intact. The smaller tarsals and metatarsals are more poorly preserved, with cortex flaking or flaked off and portions of trabecular bone having crumbled away during recovery and gentle cleaning. Portions of all the metatarsal bases are missing. The tibia has two rust stains from contact with corroded iron objects, one on the margin of the medial condyle and one distal to the tibial tuberosity. A matching rust stain is present on the lateral surface of the proximal shaft of the fibula.

Age cannot be determined for this individual based on the elements present. Slight to moderate lipping is present on most observable articular surface margins, so the individual probably was not a young adult. Sex was tentatively determined to be male, based on metric data (Table 1). The proximal breadth and distal breadth—78 mm and 50 mm, respectively—are just over the cut-offs for male (75.11 mm and 49.24 mm, Bass 1995). When measurements were entered into FORDISC, the program placed the individual closer to White males than White females.

Stature was calculated using Trotter's formula for the fibula, with a result of 175.76 +/- 3.29 cm, or approximately 5'8" to 5'10 ½". Based on a combination of long bone and calcaneus measurements, and comparison with data from nineteenth-century White males, FORDISC produced a stature estimate of 66.6 inches to 70.7 inches, roughly 5'6 ½" to 5'10 ¾".

Pathology was observed on nearly all elements of the leg and foot. The tibia and fibula both exhibit extensive periosteal bone formation involving the full length of both shafts (in patches) but with no involvement of the articular surfaces. The pathological bone is woven in appearance or forms projecting spicules. Possible limited remodeling had occurred in a couple of places, but the disorganized nature of the bone apposition demonstrates that the infection/ inflammation was active at the time of death. Greater detail concerning pathological bone observed on each element is found in the paragraphs below.

On the tibia, spicules present on the lateral surface of the tibial tuberosity appear to be enthesophytes, but along the medial and inferior margins of the tuberosity, a patch of woven bone with a maximum diameter of 23 mm is present, along with a 5 mm long spicule of bone oriented mostly parallel (rather than perpendicular) to the original cortical surface. Irregular, lumpy spicules projecting from the popliteal line could be interpreted as enthesophytes, but their pathological nature is indicated by the presence of woven bone apposition medial to the popliteal line and running for its entire length, as well as wrapping around to the medial surface of the tibia. Beginning at the inferior end of the popliteal line and running distally for about 70 mm, periosteal bone apposition on the posterior surface of the tibia appears to have undergone remodeling, with sclerotic bone replacing the woven apposition. Beginning about 30 mm distal to the nutrient foramen, woven bone apposition is present on the anterior, medial, and lateral surfaces, increasing in thickness and irregularity on the more distal portions of the shaft. The deposits are slightly thicker on the lateral surface. Macroscopically, it is impossible to determine whether the underlying cortex was affected, or all of the apposition was superficial. The shape and dimensions of the tibia are not affected by the overlying new bone. At the distal metaphysis, the apposition is circumferential, affecting the posterior surface as well, which exhibits layered, platey deposits in an area measuring 15 mm by 15 mm. Bone apposition is present in the fibular notch, though it does not extend onto the distal articular surface.

Periosteal bone formation on the fibula is more severe than on the tibia, and is most prevalent on the medial surface, with large spicules along the interosseous border indicating severe inflammation of the interosseous membrane. Woven bone starts at the most proximal point of attachment for the interosseous membrane (just distal to the fibular head), and increases in severity moving distally. For the proximal 120 mm of the fibular shaft, woven bone and spicule formation is largely restricted to the anterior border. Distal

to this point, where an 8.5 mm spicule of bone projects posteriorly and medially, bone apposition is present on the anterior, medial, and posterior surfaces. The most dense and irregular bone apposition begins 135 mm superior to the distal end and extends for about 75 mm distally. The distal metaphysis exhibits only a light overlying layer of woven bone circumferentially. The distal articular surface and malleolus appear free of pathological bone.

The talus exhibits little pathological bone, except for a small amount of woven bone deposited on the posterior margin of the anterior subtalar facet. The calcaneus also appears to have small deposits of woven bone around the margins of the anterior/medial talar facet, though taphonomic erosion makes these observations uncertain. No pathological bone is found on any articular surfaces. Poor preservation and postmortem loss of cortex from the remaining tarsals renders pathological observations almost impossible. Platey bone apposition is observable on the plantar surface of the medial cuneiform.

Preservation of the metatarsal shafts and heads is better than that of the bases, and pathology is observable. Remnants of bone spicules are present on the dorsal and plantar surfaces of the second metatarsal base. These spicules extend circumferentially up the shaft to midshaft. Distal to midshaft, woven bone is present on the lateral and plantar surfaces only. The plantar surface of the head was lost to postmortem damage and the dorsal surface has no pathological bone. The third metatarsal exhibits a small amount of woven bone along the medial shaft and a few small spicules on the plantar and medial shaft. The thickest patch of woven bone is just proximal to the head, on the plantar surface. Most of the fourth metatarsal base was destroyed postmortem, but the entire shaft appears slightly thickened by bone deposition, which is thickest on the lateral and plantar surfaces and extends almost to the head.

The fifth metatarsal is the most severely affected, perhaps indicating the original source of infection. The articular surface was destroyed taphonomically, but woven bone apposition is visible on the dorsal and plantar surfaces of the base (though not on the lateral tubercle). The shaft is deformed by bone apposition, which is layered and striated on the dorsal surface and lumpy and spiculated on the plantar surface. The metatarsal head was resorbing at the time of death, with the distal half (approximately) already gone, suggesting osteomyelitis. Unfortunately, part of the proximal articular surface of the proximal phalanx of the fifth digit was lost postmortem, so it is unknown if this resorption affected the articulation. The head of this phalanx is angled proximolaterally, and the proximal articular surface of the middle phalanx is angled to match. This middle phalanx is fully fused to the distal phalanx, with some extra bone spicules on the dorsal surface.

The fourth digit proximal and middle phalanges appear normal. The distal phalanx has a spicule of bone projecting laterally from the base, and the head is irregular. The heads are missing from the proximal phalanges that appear to belong to the second and third digits. Though there is some taphonomic damage in the area, it appears that the heads were resorbed antemortem. A small plate of bone is present on the lateral surface of the third proximal phalanx shaft and woven bone is present on the plantar surface. The plantar surface narrows towards the dorsal surface, so that the phalanx almost ends in a point. Though a small fresh break is visible where the shaft should have begun to widen for the head, most of the surface color is consistent, indicating that the phalanx was deformed antemortem. The second proximal phalanx similarly narrows to a point, but with no recent breakage evident. The shaft is porous, particularly on the plantar surface, where the bone appears lacy. However, the middle phalanges presumed to belong to the second and third digits appear normal, as does the remaining distal phalanx, except for a little irregularity of the distal margin of the head.

No cut marks are evident on the lower leg and foot elements, so the amputation is presumed to have been an above-the-knee procedure. The patella and distal femur were not recovered from the site, but this is not surprising; given the amount of heavy machinery disturbance in the area prior to the discovery of the tibia, these elements could still be present on site in soil that was moved some distance from the discovery location. The absence of the entire first digit is harder to explain. The orientation of the leg and foot in situ (resting on the lateral surface) would have placed the hallux superior and slightly anterior to the rest of

the elements, so it could have been dislodged by the same action that pulled the tibia from the soil profile. However, in this case, the phalanges would be expected to remain in situ. At the time of recovery, the soil profile was explored for additional remains and no elements were found. It is possible that the first digit was removed as a first attempt to stop the spread of infection prior to the amputation of the lower leg. As the medial cuneiform is very poorly preserved, no evidence of an operation that disarticulated the joint would be observable. If a resection removed only the distal portion of the first metatarsal, the proximal portion may have been disturbed at the same time as the tibia.

Degenerative joint disease (DJD) was observed as slight marginal lipping on the tibia's medial condyle, fibular articular facet, and distal articular surface; the distal articular surface of the fibula; all articular surfaces of the talus and calcaneus; the proximal articular surface of the navicular; and the proximal articular surfaces of the middle and distal foot phalanges.

Identification Efforts

Newspapers from the town of Battle Creek have been preserved in digital format in the Community History Archive (battlecreek.advantage-preservation.com). A search of *The Battle Creek Times* from 1914 to 1930 (1931-1940 editions are unavailable) found numerous references to amputations, but these were narrowed down based on geographical location, body part, and circumstances (trauma or infection). Only one individual, an older man who lived in the nearby town of Denison, Iowa, was reported as having his left leg removed above the knee (*Battle Creek Times* 1927). An infection that had begun in a bunion and lingered for a month reportedly turned into "senile gangrene." The leg was amputated on February 27, 1927, but the patient died five days later (*Denison Review* 1927). A descendant (who was not yet born at the time of the incident) told OSA staff that, according to family lore, a hospital employee called at some point after the operation and asked what should be done with the amputated limb. The descendant did not know what response his family gave to the hospital. At the time of publication, efforts were underway to obtain funding for DNA comparison to confirm the identity of the skeletal remains.

Summary

The articulated elements of a lower left leg discovered in a late-nineteenth-century to early twentieth-century trash dump likely represent a lower limb amputated above the knee and discarded as medical waste. A severe infection was active at the time of removal, as evidenced by periosteal bone apposition along the lengths of both the tibia and fibula shafts, particularly in the areas of the interosseous membrane attachments. The talus and calcaneus were affected to a lesser extent, and other tarsals were unobservable due to poor preservation. All metatarsals present exhibited pathological bone, particularly the fifth metatarsal, which may have been the original source of infection. The fifth metatarsal head was partially resorbed and the second and third proximal phalangeal heads were completely resorbed due to pathological processes. The first digit is absent and may have been removed from the foot antemortem or separated from the remains due to recent excavation disturbance.

The amputated limb belonged to a middle-aged or old adult, possibly a male. Stature was between 5'6 ½" to 5'10 ¾". These details are consistent with those of a potential match, an older man from a neighboring town who underwent amputation after an infected bunion developed into gangrene. The dump was active from around 1890-1940, and the potential identification dates the amputation to 1927.

References Cited

Battle Creek Times
1927 "Neighboring News." 17 March:4. Battle Creek, Iowa.
Denison Review
1927 "George H. Lyon Called by Death Friday, March 4." 9 March:4. Denison, Iowa.
Rogers, Leah D., and Jennifer A. Price
2011 *Historic Context for the Battle Creek Steam Heating System for the PPC Pavement–Grade & Replace Project of Iowa 175, City of Battle Creek, Ida County, Iowa*. Tallgrass Historians, Iowa City. Submitted to Iowa Department of Transportation, Ames. Copy on file, Office of the State Archaeologist, University of Iowa, Iowa City.
University of Iowa, Office of the State Archaeologist (UI, OSA)
2020 Burial Project 3507. On file, Office of the State Archaeologist, University of Iowa, Iowa City.

Table 1. Postcranial Metrics (mm), Burial Project 3507, 13IA63

Element	Measurement	Left
Tibia	Length	383
	Max prox epiph breadth	78
	Max distal epiph breadth	50
	Max diam nutrient foramen	34
	Med-Lat diam nutrient foramen	24
	Circumference-nutrient foramen	98
Fibula	Max length	388
	Max diameter midshaft	altered by pathology
Calcaneus	Max length	87
	Middle breadth	42
Talus	Height	33
	Breadth	42
	Length	65

Human Remains Exposed by Rodent Burrowing at the Sayers/Athey Cemetery (13IW367), Iowa County, Iowa

Lara K. Noldner

Human remains representing one older adult male were reported by a private citizen at the Sayers/Athey Cemetery (13IW367) after being exposed by rodent activity. The bones, along with several pieces of coffin hardware, had been kicked out of a groundhog burrow near a row of headstones. Since the older adult age of the individual is inconsistent with the relatively young ages indicated on the three closest headstones, the individual is not identifiable by name. Given the extent of such burrows, it is unclear where the rest of the individual's remains are located. There are also prehistorically constructed mounds associated with the same site (13IW367), however the coffin hardware and condition of the bones strongly suggests the burial is historic and the individual is Euroamerican. The remains were reburied on-site.

Introduction

On May 6th 2019, a private citizen reported that human remains were disturbed by rodent activity at the Athey Cemetery, also known as the Sayers Cemetery in Iowa County, northwest of Marengo, Iowa (Figure 1). The property is still owned by the Sayers family. OSA Bioarchaeology Program Director, Lara Noldner, was able to meet on-site with the citizen and the landowner the same afternoon. An initial survey of the area on I-sites showed two notable locations already recorded there: a "possible" mound site (XX5763) and the Athey/Sayers Cemetery (XX3013). The mounds were readily apparent on LiDAR and were also investigated during the May 6th visit. Given that there is overlap between the prehistoric and historic components (one mound is clearly visible within the historic cemetery boundaries), both the mounds and historic cemetery were recorded as 13IW367. The remains described here are associated with the historic cemetery.

A groundhog/woodchuck had made a burrow directly behind (on the east side of) a row of headstones on the eastern side of the cemetery; the row is in a north-south line with the headstones' engraved surfaces facing west. A GPS point was taken at the location of the burrow entrance. The human skeletal elements exposed were mixed in with soil pushed out of the burrow. Sharply broken margins on many of the elements were consistent with recent breakage from the rodent activity. The elements present indicate the burrow passed through the neck and upper thoracic region of only one older adult male's grave.

Given the extent of such rodent burrows and that the individual was clearly older than any of the ages indicated on the closest headstones, the individual is not identifiable by name and the disturbed grave's location is unknown. The degree of mandibular alveolar resorption, advanced degree of mandibular dental wear, and prevalence of degenerative joint disease (DJD) are indicative of an older adult (50+ years at death). However, the nearest headstones belong to Alfred Athey (39 years old), John Athey (35 years old), and "Daniel" (no last name indicated) (22 years old). Daniel's last name was possibly Cox, as that is the only Daniel listed on IAGenWeb (http://iagenweb.org/iowa/cem/sayers/index.htm). The same website indicates there are at least 51 individuals buried in the cemetery; an exact count of existing headstones was not taken, but there are fewer than 51 headstones visible today. Large open areas and the antiquity of the

cemetery mean that unmarked graves and buried headstones are likely; years of death for individuals buried there range from AD 1852-1924.

Also unearthed from the same burrow were 9 coffin nails (some with wood fragments adhered to them), a hinge, a thumb screw and a coffin handle. The design of the coffin handle is more consistent with those typically used on a child's coffin (personal communication Jennifer Mack 2019), but no juvenile remains were kicked out of the burrow.

During inspection of the site, soil probe tests were also conducted on the possible prehistoric mounds. Four prominent mounds are visible on the ground surface of the saddle ridgeline extending northwest from the cemetery. The landowner indicated that oral history of them being created by Native Americans was passed down by his grandfather. Soil probes were placed on one of the very prominent mounds, as well as two possible mounds that the landowner had also been curious about farther north and west along the same ridge line. These two additional mounds were most likely not prehistorically constructed. Tests on them as well as in an adjacent area off the uplifts revealed 10-12cm of dark brown topsoil, and then homogenous yellowish-brown clay to a depth of one meter. The soil probe test on the more prominent mound just outside the cemetery revealed much less compact soil, shallower topsoil (about 5cm in depth), the same yellowish-brown clay, but also a mottled layer 20cm in depth that included organic matter. This mixing of soils, the prominence, size and shape of the mounds, their location along a high ridge, and their oral history all suggest they were prehistorically constructed. Therefore, in addition to the historic cemetery, 13IW367 also includes at least four conical mounds. No human remains were encountered in any of the soil probe tests.

All human remains and coffin hardware were taken to the OSA for analysis. Once the landowner was able to remove the rodents, and therefore threat of further disturbance, the remains and coffin hardware were reburied on-site, on September 1, 2019. All were placed as deeply as possible in the same rodent burrow; wire mesh was then packed in and the hole was backfilled. The Sayer's family continues to monitor the area and maintain the cemetery and mounds in good condition.

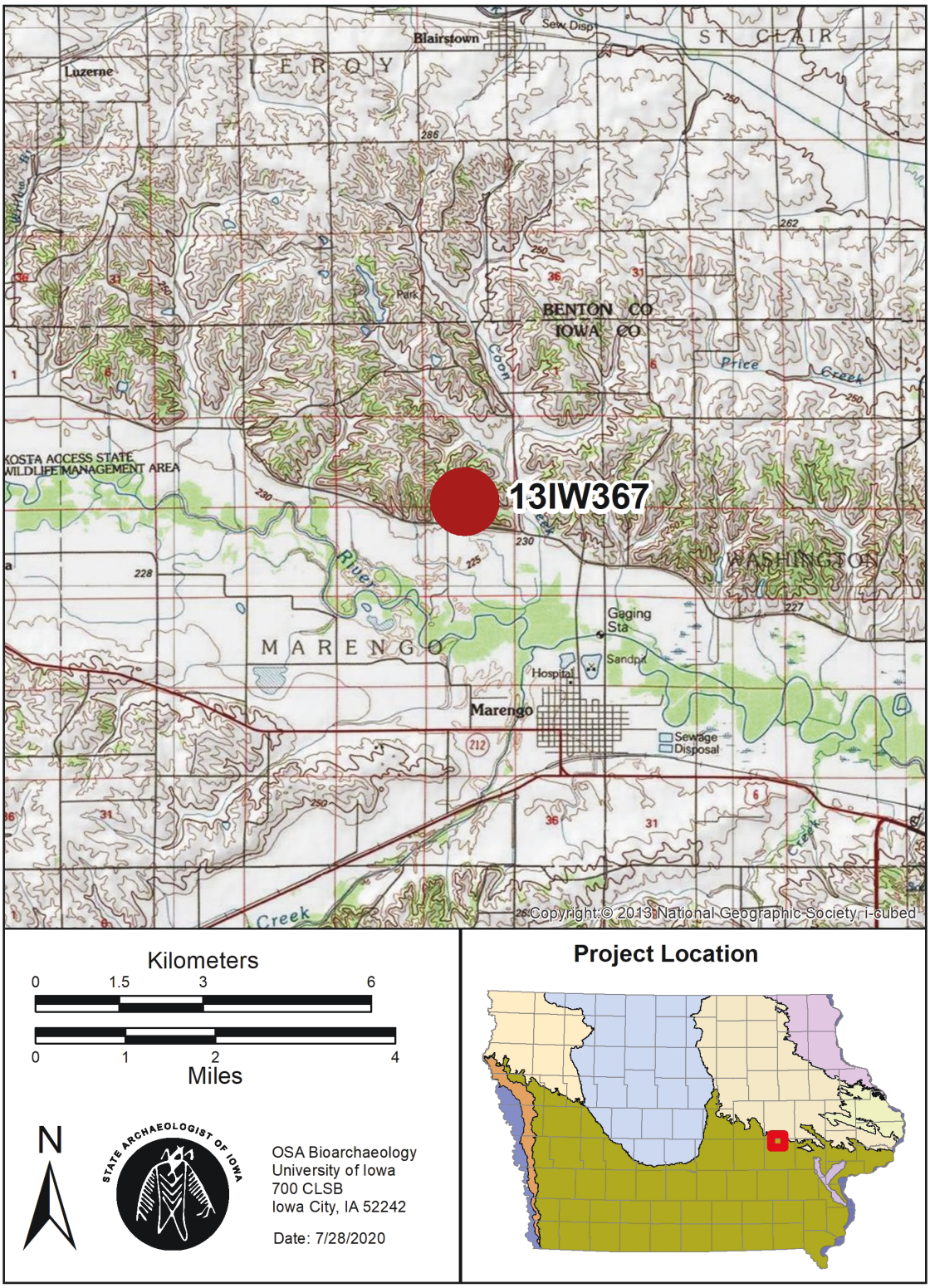

Figure 1. Location of human remains disturbance by rodents at the Athey/Sayers Cemetery (13IW367). From USGS Marengo, Iowa County, Iowa (1978), 7.5' series quadrangle map. Scale 1:100,000.

Osteological Analysis

The elements temporarily collected for analysis from the pile of dirt at the rodent burrow entrance included: a complete mandible and hyoid, a fragment of ossified cricoid cartilage, cervical vertebrae 3-7, thoracic vertebrae 1 and 2, right first, second, and third ribs, a partial left scapula, both clavicles, and one long bone fragment. All represent a minimum of one individual. The prevalence of DJD and degree of tooth wear and mandibular alveolar resorption are indicative of an older adult (50+ years at death). The morphology of the mental eminence and robusticity of the clavicles indicates this individual is male. DJD evident on articular surfaces of the cervical vertebrae, left second rib, acromial facets of the clavicles and the glenoid of the scapula, as well as the prominent enthesophytes on and general robusticity of the clavicles suggest the individual engaged in heavy manual labor involving the upper limbs. See Tables 1 and 2 for cranial and postcranial metrics.

All cervical vertebrae present (C3-7) have extensive syndesmophyte formation (projecting 3-5mm) aroung the majority of the superior and inferior surfaces of their vertebral bodies. C5 and C6 are completely fused together with no gaps between their vertebral bodies indicating fusion and extensive remodeling well before death; the spinous processes and most articular processes were broken off postmortem, but the articular processes joining the two vertebrae on the right side are also fully fused. The bone connecting all fused surfaces is normal and smooth. T1 and T2 have relatively minimal syndesmophyte formation around their vertebral bodies, projecting only 1mm or less. The right superior costal facet for the head of the first rib on T1 also exhibits expansion and lipping inferiorly so that it extends 3/4 of the way down the vertebral body and has a sharp semicircular inferior border. The left 2nd rib's articular surface with the transverse process of T2 also has uniform lipping around its entire border (projecting 0.5mm) that is mirrored on T2's left transverse process.

Both right and left clavicles are robust with sharp enthesophytes along the posterior borders of the attachment sites for the costoclavicular ligaments. Insertion sites for the conoid and trapezoid ligaments are more rugose on the right clavicle. Although most of the acromial facet on the right clavicle is missing due to postmortem damage, what remains of its anterior-most surface exhibits lipping and remodeling similar to that seen on the left clavicle's complete acromial facet. The entire surface of the left acromial facet exhibits granularity and a small area of porosity 3mm in diameter. Lipping that projects 2-3mm inferiorly and medially covers the anterior half of its inferior articular surface margin. The glenoid of the left scapula also exhibits lipping that projects 1-2mm around 2/3 of its articular surface, with one area of lipping located along its posterior border and another around its anterior, inferior curvature.

All left molars and premolars were lost well before death with the alveolus completely resorbed, except for that around the first premolar. Its partial socket is visible, and was in an intermediate stage of resorption with coarse trabecula lining it. The right second and third molars were also lost well before death; the alveolus around the third molar was completely resorbed and sockets for the second molar were still visible, but in the process of resorption. Periodontal disease is evidenced by recession of the alveolus, which was 3-5 mm away from the CEJ of the anterior teeth, and much more dramatically receding around the right first molar. 2/3 of the first molar's roots were exposed bucally, but no abscess was present. See Tables 3 and 4 for dental inventory and metrics.

Summary

While 13IW367 has both prehistoric and historic components, the condition of remains disturbed by rodent activity and their association with fairly well preserved coffin hardware, some pieces with remnants of adhering coffin wood intact, suggests the burial dates to the historic period, and that the one older adult male represented is most likely of Euroamerican ancestry. Rodent burrows can extend over 20 feet, and the burrow opening was 34 feet southeast from the base of the mound in the cemetery. However, the cortical bone on all elements present strongly suggests a more recent burial, and is not consistent with preservation seen for prehistoric mound burials. It is not possible to determine the individual's name or original burial location as it is unclear where the disturbed grave is located.

References Cited

University of Iowa, Office of the State Archaeologist (UI, OSA)
2019 Burial Project 3439. On file, Office of the State Archaeologist, University of Iowa, Iowa City.

Table 1. Cranial Metrics (mm), Burial Project 3439, remains from Sayers/Athey Cemetery

Cranial metric	Individual 1
Chin height	26.78
Mandibular height L	
Mandibular height R	
Bigonial width	97.48
Bicondylar breadth	114.59
Minimum ramus breadth L	33.5
Minimum ramus breadth R	33.39
Maximum ramus breadth L	43.45
Maximum ramus breadth R	43.84
Ramus height L	66.41
Ramus height R	67
Mandibular length	74
Mandibular angle	111

Table 2. Postcranial Metrics (mm), Burial Project 3439, remains from Sayers/Athey Cemetery

Element	Measurement	Left	Right
Clavicle	Length	147.55	
	A-P diameter midshaft	14.17	15
	Sup-Inf diameter midshaft	12.55	10.8

Table 3. Dental Inventory, Burial Project 3439, remains from Sayers/Athey Cemetery

Tooth	Presence	Attrition:	Attrition- molars:			
		I, C, P	Mes-buc	Mes-ling	Dis-ling	Dis-buc
MAXILLA:						
RM3	3		0	0	0	0
RM2	3		0	0	0	0
RM1	3		0	0	0	0
RP2	3	0				
RP1	3	0				
RC	3	0				
RI2	3	0				
RI1	3	0				
LM3	3		0	0	0	0
LM2	3		0	0	0	0
LM1	3		0	0	0	0
LP2	3	0				
LP1	3	0				
LC	3	0				
LI2	3	0				
LI1	3	0				
MANDIBLE:						
LM3	4		0	0	0	0
LM2	4		0	0	0	0
LM1	4		0	0	0	0
LP2	4	0				
LP1	4	0				
LC	2	6				
LI2	2	7				
LI1	2	7				
RM3	4	0				
RM2	4	0				
RM1	2		10	9	7	7
RP2	2	7				
RP1	2	7				
RC	2	6				
RI2	2	7				
RI1	2	7				

Dental Inventory Key:
Presence
1 Present but not in occlusion
2 Present, development completed, in occlusion
3 Missing, with no associated alveolar bone
4 Missing, with alveolus resorbing or fully resorbed: antemortem loss
5 Missing, with no alveolar resorption: postmortem loss
6 Missing, congenital absence
7 Present, damage renders measurements impossible
8 Present but unobservable (e.g. teeth in crypts)
9 Unobservable
Attrition (I, C, PM)
1 Unworn or small facets
2 Point or hairline of dentin
3 Dentin line of distinct thickness
4 Moderate dentin exposure, not resembling a line
5 Large dentin area with rim complete (two areas on premolars)
6 Large dentin area with enamel rim lost on one side (two areas coalesced on premolars)
7 Enamel rim lost on two sides (at least one side lost on premolars)
8 Complete loss of crown, no enamel remaining
9 Unobservable
Attrition (molars)
0 Unobservable
1 Wear facets invisible or very small
2 Wear facets large, but cusps and surface features still evident
3 Any cusp in quadrant is rounded, but not flat
4 Quadrant is worn flat, but no dentin is exposed (except pinprick-sized)
5 Quadrant is flat, dentin exposed on ¼ of quadrant
6 More than ¼ of dentin is exposed, with enamel ring still complete
7 Enamel is found on only two sides of quadrant
8 Enamel on only one side of quadrant, but enamel is still thick
9 Enamel on only one side of quadrant and it is very thin
10 No enamel remaining. Wear extends below the cervicoenamel junction onto the root

Table 4. Dental Metrics (mm), Burial Project 3439, remains from Sayers/Athey Cemetery

Tooth	Mesiodistal	Buccolingual	CEJ mesiodistal	CEJ buccolingual
MANDIBLE:				
LM3				
LM2				
LM1				
LP2				
LP1				
LC			5.50	5.75
LI2			3.55	6.20
LI1			3.20	5.35
RM3				
RM2				
RM1			8.25	8.10
RP2			4.60	7.50
RP1			4.35	6.80
RC			5.55	5.95
RI2			3.60	5.90
RI1			3.30	5.35

Summary Report of Human Remains Recovered from Woodpecker Cave, 13JH202, in Johnson County, Iowa, during Archaeological Field School Excavations, 2012–2017

Jennifer E. Mack

Numerous isolated human teeth and elements were recovered from habitation deposits in Woodpecker Cave (13JH202) in Johnson County, Iowa, during archaeological field school excavations conducted between 2012 and 2017. A minimum of four individuals are represented by the remains, including an old adult, an adolescent or young adult, a child 7.5–9.5 years old, and an infant 1.5–4.5 months old. A naturally-shed deciduous tooth represents the presence of an additional, living child, 11–12 years old. Both Archaic and Woodland components have been identified at the site.

Introduction

Woodpecker Cave, 13JH202, is a multicomponent prehistoric site located in the NW ¼ of Section 4, T80N, R6W, in Johnson County, Iowa (Figure 1). Partially excavated in 1956, the rockshelter was the focus of excavations by a University of Iowa Department of Anthropology field school between 2012 and 2017. The work, overseen by Dr. James Enloe, resulted in the collection of numerous isolated human teeth, cranial fragments, and small elements in deposits that also included faunal remains, lithic debitage, ceramics, and shell (UI, OSA 2012, 2014). No burials were discovered during the field school excavations or the previous 1956 work (Caldwell 1961). Though the digging in 2012 concentrated on back dirt from the 1956 project, subsequent excavations investigated intact deposits. Only in rare instances were multiple human bone specimens recovered from the same provenience.

Analysis of human remains recovered from the site in 2012 and 2014, which included five teeth and three phalanges, was published by the Office of the State Archaeologist Bioarchaeology Program in 2014 (Mack and Lillie 2014). However, the previously analyzed materials are included in the current discussion which summarizes all human remains recovered from Woodpecker Cave between 2012 and 2017.

Figure 1. Location of Woodpecker Cave, 13JH202.
From USGS Ely, Johnson County, Iowa (1994), 7.5' series quadrangle map. Scale 1:100,000.

Osteological Analysis

In all, 19 human bone elements were recovered from 13JH202 between 2012 and 2017, including 13 teeth, three cranial vault fragments, and three phalanges (Tables 1 and 2). The analysis below is ordered by the unit of recovery. Dates in parentheses indicate the years that units were excavated.

UNIT L93 (2012, 2016)

A maxillary right canine was recovered from Unit L93, between 150 and 160 cm below datum. The root is complete, and the crown is in good condition with only a few longitudinal cracks visible in the enamel. No carious lesions are present. Occlusal wear exposed a patch of dentin the size of a pinhead. Two smooth, narrow enamel hypoplastic defects are present on the labial surface, measuring 3.6 and 5.4 mm from the cemento-enamel junction (CEJ). The crown measures approximately 7.7 mm mesiodistally and 8.3 mm buccolingually. The apex of the canine root was closed, and the moderate degree of occlusal wear on the tooth suggests an adolescent or a young adult.

This same unit produced a deciduous maxillary right second molar at Level 9. The moderately worn deciduous tooth exhibited resorption of the root, demonstrating it was naturally shed. Though this tooth indicates the presence of a living 11–12-year-old at the cave in the past, it does not contribute to the MNI for the site.

UNIT M95 (2012, 2014)

A phalanx was recovered from Unit M95 between 0.0 and 10 cm below datum. The element is a distal foot phalanx, but it cannot be further identified as to side or digit, though it most likely originated from the second, third or fourth digit. The element is in good condition, with a maximum length of approximately 14.5 mm. The proximal epiphysis of the phalanx is fully fused, indicating the individual was an adolescent or adult.

In 2014, a darkly stained middle-row hand phalanx was recovered from Unit M95, Level 6. The proximal epiphysis was lost postmortem, but the size indicates the element belonged to an adult.

UNIT L98 (2014)

A maxillary left lateral incisor was recovered from Unit L98, Level 5. The mesial and distal enamel were lost postmortem, but the tooth appears to display moderate dental wear. Moderate calculus deposits are present. Two horizontal enamel hypoplastic defects are present, measuring 1.6 and 5.5-6.4 mm from the CEJ. Age cannot be estimated more precisely than adult.

A mandibular right third molar was recovered from Unit L98, Level 7 (catalog# L98.29). Moderately severe dental wear was observed on the molar, with the crown surface flattened and dentin exposed over almost all of the occlusal surface. The tooth displays slight calculus deposits but no carious lesions.

A middle row foot phalanx was also recovered from Unit L98 at Level 7. The proximal epiphysis is fused, and the phalanx is of adult size.

UNIT L95 (2014)

A deciduous maxillary left second molar was recovered from Unit L95, Level 7. Though one of the roots was lost postmortem, there was no evidence that the roots were resorbing, as would be seen in a naturally shed tooth. The maxillary second molar is usually shed in modern populations around the age of 11 to 12 years. However, the severe, cupped wear seen on the molar suggests that it may have been retained in the dental arcade past this age. Although relatively rare, the failure of permanent teeth to develop can lead to the retention of deciduous teeth into adulthood. An alternative explanation is that the individual represented by

this tooth was a child consuming a very heavy grit diet that accelerated the rate of wear. This molar could be associated with an older child, adolescent, or adult.

UNIT K95 (2014)

A maxillary left third molar was recovered from Unit K95, Level 6 (catalog# E-972). Heavy dental wear exposed dentin across the entire occlusal surface with cupping and significant loss of crown height. The attrition is uneven, with the mesial edge worn almost to the CEJ. The third molar from Unit L98 was not worn as severely, but both teeth may represent the same older adult. Slight hypercementosis is present on the root. Slight calculus is present, but the tooth was not affected by caries.

UNIT K97 (NO DATE)

An unsided mandibular premolar was recovered from Unit K97, Level 9. The enamel is fragile and portions were lost postmortem. This enamel loss combined with dental wear exposing dentin across the entire occlusal surface (with just a ring a enamel remaining) prevented further identification of the tooth. A middle or old adult is represented by the tooth.

UNIT M97 (2015)

Two small, dark-colored cranial vault fragments were discovered in Unit M97, Level 8. Based on morphology, the fragments may be parietal or occipital fragments. The edge of one fragment includes a section of cranial suture that is almost completely open. The thickness of the bone is consistent with that of an adult cranium.

UNIT I97 (2015)

A deciduous maxillary right central incisor was recovered from Unit I97, Level 4. Based on crown development, the tooth represents an individual aged 1.5–4.5 months at the time of death.

UNIT H97 (2015, 2017)

A maxillary right first molar was recovered from Unit H97, Level 5. The slight wear and rounded cusps indicate the tooth came from an older child to young adult. The tooth was split longitudinally postmortem, and some enamel was lost, rendering measurement impossible.

An unerupted mandibular right second molar was recovered from Level 9 in this unit. Initial root formation at the time of death indicates the individual was 7.5–9.5 years old.

UNIT G98 (2017)

A small cranial vault fragment was recovered from Unit G98, Level 5. The dark staining and overall thickness are consistent with the other two adult cranial fragments recovered.

UNIT F98 (2017)

Three human teeth were recovered from Unit F98 in Levels 5 and 6. A maxillary right central incisor was found in Level 6. Excavation damage prevents crown measurements or attrition classification, but the height of the crown suggests little wear.

Level 5 produced a mandibular left third molar, while a maxillary right third molar was found in Level 6. The mandibular third molar was erupted at the time of death, with a mesial contact facet and very slight wear evident. The root apices were half closed, indicating an age of approximately 19.5–23.5 years. The maxillary third molar was less developed, with the root about ¾ complete, indicating an age between 15.5

and 20.5 years. Much of the enamel was broken off this tooth postmortem, but no wear was evident on the portions that remained, suggesting it may have been unerupted.

All three teeth found in Unit F98 exhibit development and wear consistent with an adolescent or young adult and may represent the same individual.

Summary

Isolated human remains recovered from excavations at Woodpecker Cave (13JH202) between 2012 and 2017 represent a minimum of four individuals. An older adolescent or young adult was identified based on slight dental wear on five teeth and the incomplete roots of two third molars. This age classification may also account for the heavily worn deciduous second molar. At least one older adult is present, based on heavy dental wear observed on two third molars. A child aged 7.5–9.5 years is represented by an incompletely formed mandibular second molar. An infant 1.5–4.5 months is represented by the incomplete crown of a deciduous first molar. A child 11–12 years old was also present at the rockshelter, represented by a naturally-shed deciduous second molar, but does not contribute to the MNI, as this individual may have reached an older age before death. The dental remains are free of caries, and no pathology was observed on the few cranial fragments or phalanges. Both Archaic and Woodland components have been identified at the site. The period (or periods)from which the remains originate has yet to be determined.

References Cited

Caldwell, Warren W.

1961 Archeological Investigations at the Coralville Reservoir, Iowa. In *River Basin Surveys Papers*, No. 22, by Smithsonian Institution, Bureau of American Ethnology, pp. 79–148. Smithsonian Institution, Bureau of American Ethnology, Bulletin 179. U.S. Government Printing Office, Washington, DC.

Mack, Jennifer E., and Robin M. Lillie

2014 Isolated Human Remains from Woodpecker Cave, 13JH202, Johnson County, Iowa. In *Reports on Burial Projects Osteology and Archaeology*, edited by Robin M. Lillie and Shirley J. Schermer, pp. 63–67. Research Papers Vol. 38, No. 1. Office of the State Archaeologist, University of Iowa, Iowa City.

University of Iowa, Office of the State Archaeologist (UI, OSA)

2012 Burial Project 2755. On file, Office of the State Archaeologist, University of Iowa, Iowa City.

2014 Burial Project 3039. On file, Office of the State Archaeologist, University of Iowa, Iowa City.

Table 1. Commingled Dental Remains, Burial Projects 2755 and 3039, 13JH202

	# Left	# Right	# Unsided	Age
MAXILLA:				
M3	1			worn, old adult
M3		1		15.5-20.5 yrs
M2		1		7.5-9.5 yrs
M1		1		
dm2	1	1		Rdm2 shed at 11-12 yrs
C		1		
I2	1			
I1		1		
di1		1		1.5-4.5 mos
MANDIBLE:				
M3	1			19.5-23.5 yrs
M3		1		worn, old adult
Premolar			1	

Table 2. Commingled Remains, Burial Projects 2755 and 3039, Woodpecker Cave (13JH202)

Element	Number of Fragments/ Specimens	MNE Left	MNE Right	MNE Unsided	MNI
Cranium/mandible	3			1	1
Teeth	13	4	8	1	5
Hand phalanges	1			1	1
Foot phalanges	2			2	1

Human Remains Disturbed During Derecho Tree Damage Clean-up in Oak Hill Cemetery, Cedar Rapids, Linn County, Iowa

Jennifer E. Mack

Human skeletal remains found on the disturbed ground surface of Oak Hill Cemetery in Cedar Rapids, Iowa, represent a minimum of one adult individual. The remains appear to have been disturbed during the removal of a tree brought down by the August 2020 derecho. Based on dates inscribed on nearby grave markers, the unmarked, disturbed grave is believed to date to the 1880s–1890s. As more unmarked graves are possible in the vicinity, the location was designated site number 13LN1240.

Introduction

On October 26, 2021, the Office of the State Archaeologist (OSA) received a phone call from Elizabeth Jacobi, interim City Attorney for the City of Cedar Rapids, regarding a human femur that had been discovered on the ground surface of Oak Hill Cemetery (established 1854) during tree removal and clean-up work (Figure 1). The section of the cemetery where the remains were found is managed by the Parks and Recreation Department of Cedar Rapids, but a contractor was retained for post-derecho tree removal. While inspecting an area where a fallen tree and its uprooted stump had been removed on October 14, a city employee found what he believed to be a human bone on the surface of the disturbed and graded soil. Cedar Rapids police confirmed that the bone was a human femur. No other human remains were identified by cemetery employees, Parks and Recreation staff, or police at the time of discovery. The city reported no grave markers are present in the immediate vicinity of the fallen tree.

OSA Bioarchaeology Program staff visited the site on October 26 to collect the femur and examine the area of the discovery. Three additional bone fragments and several small pieces of probable coffin wood were collected from the ground surface in the same area. The grave markers nearest to the location of the removed tree are all several meters away. Markers to the east and west bear death dates from the 1880s–1890s and Czech-language inscriptions. During the site visit, OSA staff examined the areas of several additional uprooted trees in the cemetery but found no additional human remains or coffin materials (UI, OSA 2021).

The collected human remains and coffin wood fragments were taken to the OSA laboratory in Iowa City for analysis prior to the planned reburial of the materials. Since additional, now unmarked graves are likely surrounding the area of the exposed remains, the location was designated site number 13LN1240.

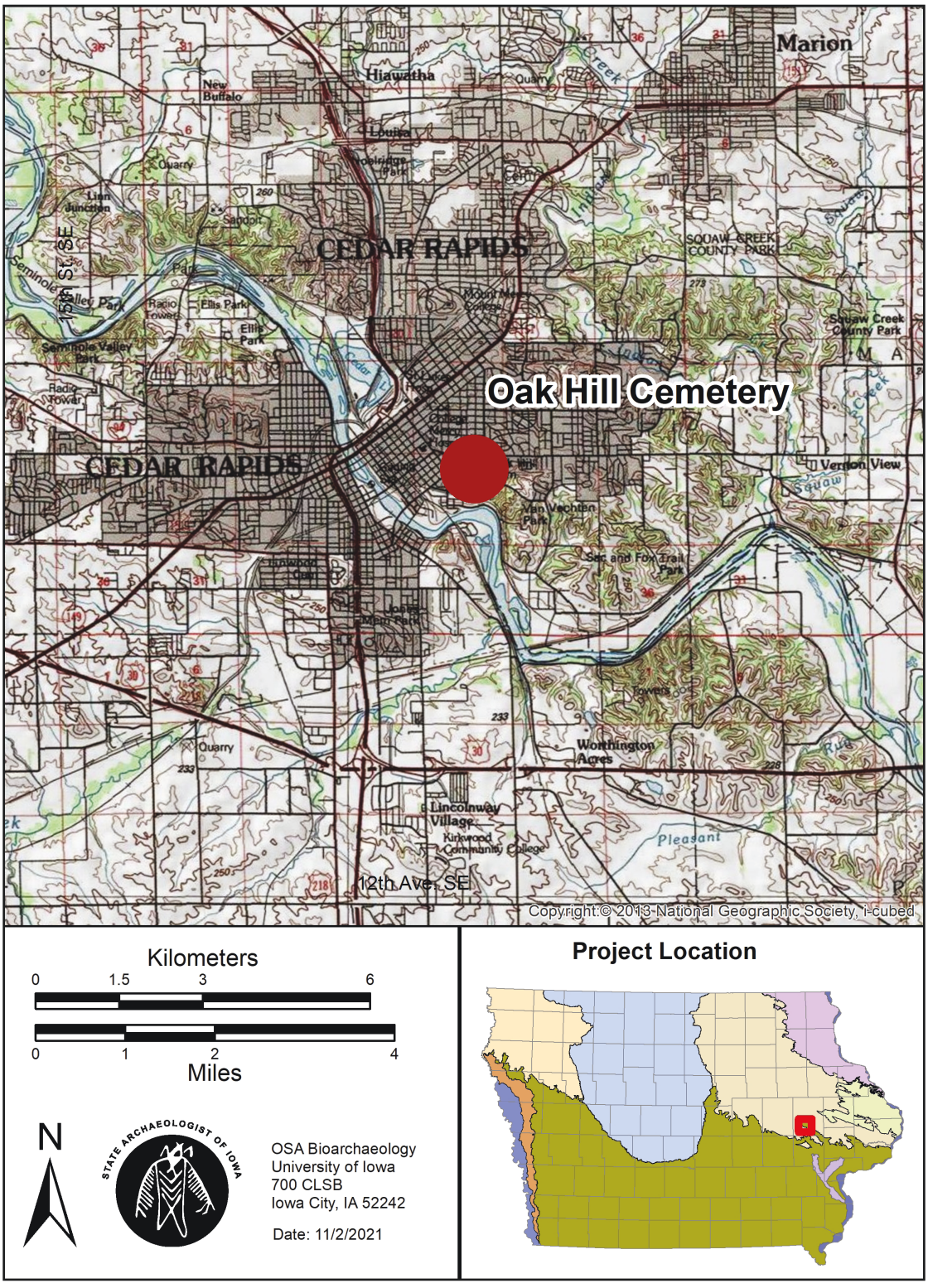

Figure 1. Location of Oak Hill Cemetery, Cedar Rapids, Linn County, Iowa. From USGS Cedar Rapids South, Linn County, Iowa (1994), 7.5' series quadrangle map. Scale 1:100,000.

Osteological Analysis

Human remains recovered from the location an uprooted tree in Oak Hill Cemetery represent a minimum of one adult individual. The recovered elements include a nearly complete right femur, a left distal radius fragment, and two unidentified bone fragments. The condition of the remains is poor likely due to preservation conditions on site and post-depositional disturbance from both the growth of the tree roots and the removal of the tree. The cortical surface of the femur is cracked and flaking; portions of the surface are missing due to taphonomic erosion or mechanical damage. The remaining cortex has a warm dark brown color often found in association with coffin wood. The greater trochanter, lateral condyle, and most of the medial condyle of the femur are absent. Very little of the cortical surface remains on the radius fragment.

Age and sex could not be determined based on the portions of femur and radius present. Few measurements could be collected, due to postmortem damage. The anterior-posterior subtrochanteric diameter for the right femur is 31 mm, while the medial-lateral subtrochanteric diameter is 34 mm. The femoral shaft exhibits anterior bowing in the proximal third of the shaft only, and the head appears slightly elongated medially, but these features fall within the range of normal human variation rather than indicating some type of pathology.

Summary

At least one adult of indeterminate age and sex is represented by these human remains disturbed in Oak Hill Cemetery during tree removal activities in October 2021. The presence of board fragments found near the remains supports the presumption that the skeletal elements originated from a coffined burial. Based on information inscribed on the surrounding grave markers, the area of the cemetery where the individual was buried was used by the Czech community in the 1880s and 1890s.

References Cited

Iowa State University Geographic Information Systems Support and Research Facility (ISUGISSRF)
2021 Iowa Geographic Map Server. Iowa State University Geographic Information Systems Support and Research Facility, Ames, Iowa. Electronic document, ortho.gis.iastate.edu, accessed November 2, 2021.

University of Iowa, Office of the State Archaeologist (UI, OSA)
2021 Burial Project 3640. On file, Office of the State Archaeologist, University of Iowa, Iowa City.

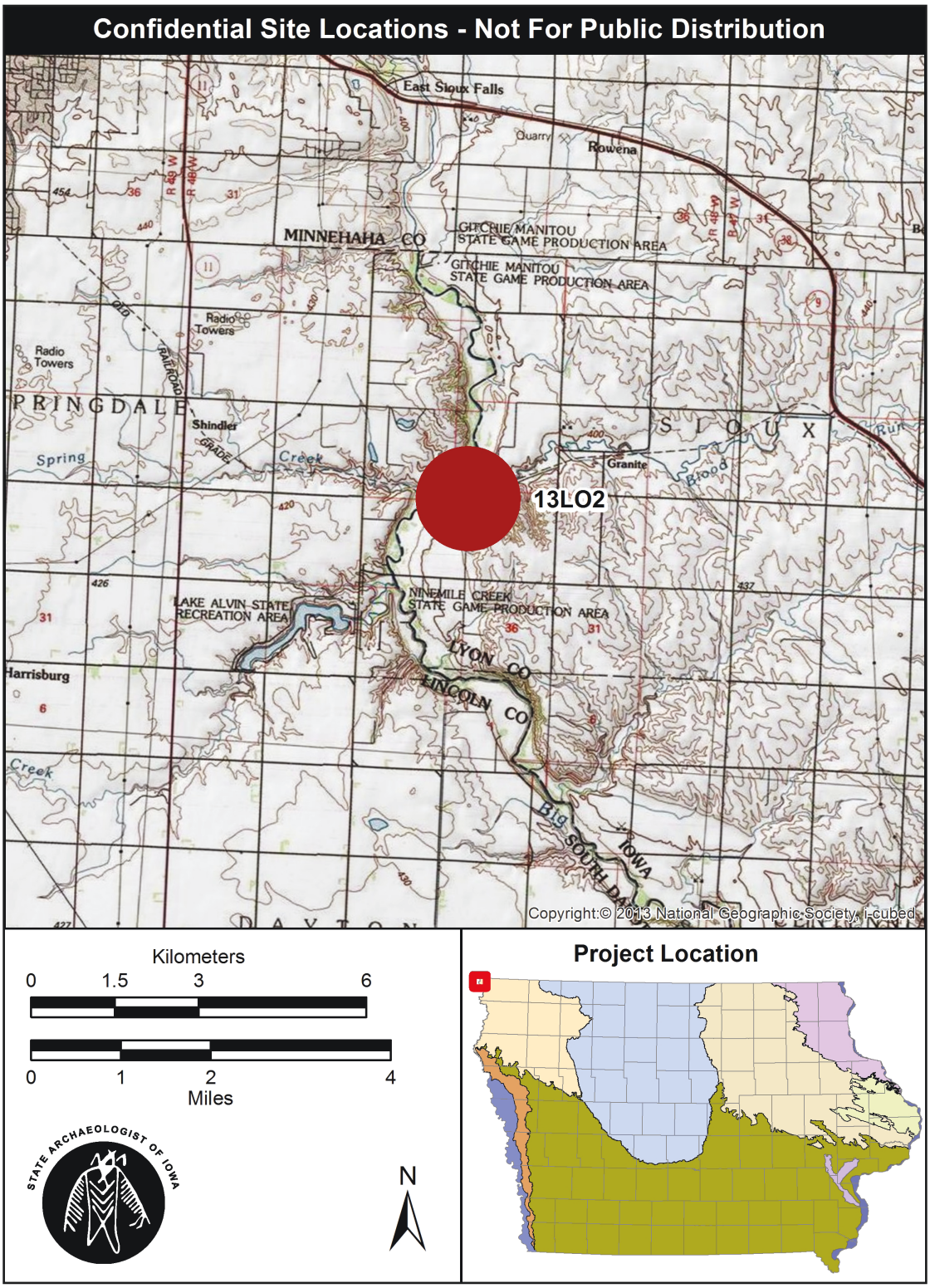

Figure 1. Location of the Blood Run National Historic Landmark site, 13LO2.
From USGS Klondike, Lyon County, Iowa (1962), 7.5' series quadrangle map. Scale 1:100,000.

Additional Human Remains Collected from an Eroding Landform at Blood Run National Historic Landmark (13LO2), Lyon County, Iowa

Jennifer E. Mack

Human remains recovered from an eroding landform at the Blood Run National Historic Landmark (NHL), within the boundaries of 13LO2, were reported to the OSA by Iowa Department of Natural Resources (DNR) staff on May 3, 2019. Eroding remains had been observed and collected from this location the previous year (Noldner 2019). All of the elements collected in May 2019 appear to represent the individual previously recovered from the landform. The remains were reburied on-site in a more secure location.

Introduction

The Blood Run site (13LO2), over 600 acres in extent, straddles the Big Sioux River where it divides northwestern Iowa from southeastern South Dakota (Figure 1). Archaeological evidence indicates that several village and mound areas existed within the site's boundaries. The greater portion of the site is located in Lyon County, Iowa, where archaeological remains are especially concentrated on the floodplain and terraces of the Big Sioux and its tributary, Blood Run Creek. The site has attracted attention since the time of initial Euroamerican settlement of the area, from those pursuing scholarly interests as well as from the merely acquisitive. Various surveys undertaken in the late 1800s suggest that 200 to 300 mounds may once have existed at the site and adjacent vicinity. Early surveyors also reported the presence of numerous stone circles. These have completely disappeared from the site, as the stones were removed from fields to facilitate plowing. Nearly a century of intense cultivation reduced the number of identifiable mounds to 77 by 1980. Archaeological investigations of Blood Run have uncovered evidence of extensive late prehistoric-early historic Oneota occupation at the site. Historic accounts of French traders as well as various Native American traditions indicate that during the late seventeenth and early eighteenth centuries Omaha, Iowa, and Otoe groups all probably resided along the Big Sioux River, possibly settling together for a brief period at the Blood Run site. Gravel quarrying, farming, and urban sprawl impacted the site in the twentieth century. The State of Iowa acquired ca. 200 acres of the site in 1987, and the State of South Dakota acquired ca. 200 acres in 1997. The Iowa-owned portion of the site was designated the Blood Run National Historic Landmark (Alex 2000; Henning 1993; Henning and Anderson 1985; Mack et al. 2017:17).

On May 3, 2019, Iowa DNR staff contacted the OSA to report the exposure of human remains at Blood Run NHL. Exposed remains had previously been reported at this location, and were collected in November 2018 (Noldner 2019; UI, OSA 2018). A site visit on May 3 found the remains eroding out of the same actively slumping, southeast facing cutbank approximately 35 feet above the north bank of the Blood Run Creek channel. A cranial vault and two long bone shafts were found in situ. The long bones, a humerus and fibula, were found together approximately 30 cm below the grass line of the slumping cutbank. The cranial remains were found 40 cm north of the long bones, approximately 15 cm below the grass line. Deeper into the bank, behind the cranium, an incomplete atlas was found, along with three complete copper coils and coil fragments. All of the remains were located approximately 50 cm below the summit of the landform.

The fragmented but largely intact cranial vault was found slightly north of the frontal bone recovered in November 2018, likely because the frontal was moved from its original location by the slumping soil. The skull was resting on its left side, so that the facial elements would have been facing south-southeast, looking at Blood Run Creek. The atlas was found near the occipital, but was oriented horizontally in the bank, rather than angled to articulate with the occipital condyles. What appears to be a fibula fragment was found crossed over the left humeral shaft, suggesting the individual was not articulated at the time of burial. The soil around the remains was darker than the exposed soil further north on the cutbank, but no clear feature outline was observed.

Osteological Analysis

The frontal collected from this location in November 2018 articulates with the parietals recovered in May 2019. Though the left humerus collected in 2019 appears to exhibit pathological alteration, it is generally the same size and condition as the right humerus previously recovered. No duplicate elements were identified in the two collections of remains. Therefore the minimum number of individuals for the two collections is one, and it is likely that all the remains represent a single individual.

The cranial vault collected in 2019 consists of the parietals, temporals, occipital, part of the sphenoid, right zygomatic, and part of the right maxilla with three teeth (Tables 1 and 2). Green staining from contact with the copper coils—and perhaps other copper objects lost in the slumping soil—is present on all surfaces of the left half of the atlas, the left zygomatic process, left temporal squamous (with some staining ectocranially along the suture), and the portion of the left parietal immediately superior to the temporal suture. At the copper-stained locations, the cortical surface of the bone is smooth and well preserved. The rest of the ectocranial surface exhibits postmortem erosion. The anteromedial portion of the left parietal, which was exposed prior to collection, has a greater amount of erosion and some sun-bleaching, similar to the previously collected frontal. The distal portion of the left humeral shaft and one end of the fibula shaft segment are also bleached from exposure. The cortical surface is exfoliating off the remaining portions of the two long bone shafts. Evidence of animal gnawing is present on the proximal end and posterior surface of the left humerus. No other skeletal elements were observed or collected during this visit.

The individual represented by these and the previously collected elements was likely a young adult, based on open cranial sutures. Though suture closure was apparently beginning on the endocranial surface, the taphonomic separation of all cranial elements along suture lines indicates that fusion was not far advanced. Dental wear was quite moderate for prehistoric Native American populations, which supports the general age estimate of young adult (approximately 20 to 35 years). The individual was previously identified as a possible male, based on the prominence of glabella. Of the sex markers observable on the newly collected remains, the nuchal crest was intermediate and the right mastoid process was short but broad, somewhat ambiguous. Neither observation contradicts the identification of the individual as male.

The left humeral shaft exhibits abnormal morphology, suggesting some sort of pathological and/or developmental deformation. The precise nature of the pathology cannot be determined, due to taphonomic damage to the bone. Only approximately three-quarters of the shaft is present, and the cortical surface is eroding in places and has exfoliated completely in others. However, some observations were possible. The entire shaft segment present exhibits a flat posterior surface, similar to the normal morphology of the distal humerus, but extending to the proximal end of the shaft. This flat surface exhibits slight concavity in the proximal-distal direction. It is possible that the humerus was slightly bowed, but damage to the anterior surface makes this difficult to determine. A widening of the shaft is present at the location of the deltoid tuberosity but has a swollen appearance, lacking definition at the insertions for the deltoideus and the pectoralis major. The widest transverse diameter on the deltoid tuberosity is 24.8 mm, similar to the normal right humerus, which measures 24.2 mm at the deltoid tuberosity. The anterior-posterior diameter

at this same location is 15.4 mm on the left humerus, due to flattening, compared to 21.3 mm on the normal right humerus. The presence of a narrow, deep groove on the anterior surface of the swollen tuberosity area suggests the presence of periosteal bone apposition at that location. Based on the small amount of observable intact cortical surface, this bone apposition appears to have been sclerotic and well-remodeled at the time of death. In the cross-section of the distal broken end of the shaft, porosity is evident in the cortical bone of the anterior surface, suggesting the original cortical surface may have been remodeled into spongy bone. It is possible the trauma or infection which caused the pathological bone apposition occurred while this individual's long bones were still growing, and that disuse of the arm and subsequent atrophy could have caused the flattening of the shaft, as the muscle tensions which shape the bone shaft would not have been active.

Summary

Human remains found eroding out of a cutbank above Blood Run Creek within the Blood Run NHL appear to represent the same individual as the remains collected from the same location in November 2018. These remains represent a young adult male, who appears to have been buried as a bundle rather than in articulation. The left humerus exhibits abnormal morphology and periosteal bone apposition, indicating an unidentified pathological condition. Copper coils were found associated with the first cervical vertebra, and copper staining on the left side of the cranium indicates that additional copper objects were originally present. Based on provenience and the presence of the copper coils, these remains are believed to represent a Native American affiliated with the Oneota cultural tradition or a protohistoric or early historic group. The human remains recovered were included in a reburial on-site with all other individuals from Blood Run NHL that were reposed at the OSA from 2005 to 2019.

References Cited

Alex, Lynn M.
2000 *Iowa's Archaeological Past.* University of Iowa Press, Iowa City, Iowa.

Henning, Dale, R.
1993 The Adaptive Patterning of the Dhegiha Sioux. *Plains Anthropologist* 38:253-264

Henning, Dale R., and Duane C. Anderson
1985 The Blood Run Archaeological Site: A Landmark in Plains-Midwest Prehistory. Manuscript on file, Office of the State Archaeologist, University of Iowa, Iowa City.

Mack, Jennifer E., Robin M. Lillie, and Lily Doershuk
2017 Human Remains from the Blood Run Site (13LO2), Found in the Amy Harvey Collection and in the Luther College Archaeological Laboratory Collection. In *Bioarchaeological Reports on Human Skeletal Remains from Iowa and Other Proveniences*, edited by Jennifer E. Mack and Lara K. Noldner, pp. 17-22. Research Papers Vol. 42, No. 2. Office of the State Archaeologist, University of Iowa, Iowa City, Iowa.

Noldner, Lara K.
2019 Human Remains Recovered from Eroding Landform at Blood Run National Historic Landmark (13LO2), Lyon County, Iowa. In *Bioarchaeological Reports on Human Skeletal Remains from Iowa and Other Proveniences,* edited by Jennifer E. Mack and Lara K. Noldner, pp. 17-18. Research Papers Vol. 44, No. 1. Office of the State Archaeologist, University of Iowa, Iowa City, Iowa.

University of Iowa, Office of the State Archaeologist (UI, OSA)
2018 Burial Project 3407. On file, Office of the State Archaeologist, University of Iowa, Iowa City.

Table 1. Dental Inventory, Individual 1, Burial Project 3407, 13LO2

Tooth	Presence	Attrition:	Attrition- molars:			
		I, C, P	Mes-buc	Mes-ling	Dis-ling	Dis-buc
MAXILLA:						
RM1	2		6	6	5	4
RP2	2	3				
RC	2	3				

Table 2. Dental Metrics (mm), Individual 1, Burial Project 3407, 13LO2

Tooth	Mesiodistal	Buccolingual	CEJ mesiodistal	CEJ buccolingual
MAXILLA:				
RM1	10.0	11.9	7.4	10.7
RP2	6.3	8.3	4.2	7.1
RC	7.9	7.8	5.5	7.3

A Deciduous Human Tooth Discovered with Faunal Remains from 13ML139 in Mills County, Iowa

Jennifer E. Mack

A naturally shed deciduous human molar discovered stored with faunal remains from 13ML139, a Nebraska Phase house site in western Iowa, represents a subadult approximately 10.5 to 11.5 years old.

Site 13ML139 (Figure 1) was one of several Nebraska Phase house sites excavated between 1971 and 1972 in Mills County, Iowa, by the Office of the State Archaeologist (OSA) Highway Archaeology Program in advance of construction of Highway 34. Though no human remains were identified during the excavation, two isolated elements—a section of adult femoral shaft and a naturally shed deciduous incisor representing a 5.0-6.0-year-old child—were later discovered during analysis of faunal remains from the site (UI, OSA 1982). These remains, recovered from two separate locations within 13ML139, were reburied in 1985. In 2017, during a review of faunal remains stored in the OSA repository, another deciduous tooth was found. This tooth crown had been recovered from Cache #1 and incorrectly identified as fish bone. The tooth was subsequently transferred to the OSA-BP for analysis and repatriation.

The human tooth found in Cache #1 is a deciduous maxillary left first molar. The irregular, thinned edges of the crown are consistent with those of a tooth crown naturally shed. Loss of the maxillary first molars generally occurs around the age of 10.5 to 11.5 years. The subadult represented by this tooth is older than the previously identified subadult, thus raising the minimum number of individuals represented by remains from 13ML139 to three. However, since naturally shed teeth represent individuals who were still alive at the time of deposition, only one potential burial is represented at the site. Additionally, the same subadult could have contributed both deciduous teeth, with the separate depositions occurring several years apart.

References Cited

University of Iowa, Office of the State Archaeologist (UI, OSA)

1982 Burial Project 167. On file, Office of the State Archaeologist, University of Iowa, Iowa City.

2017 Burial Project 3302. On file, Office of the State Archaeologist, University of Iowa, Iowa City.

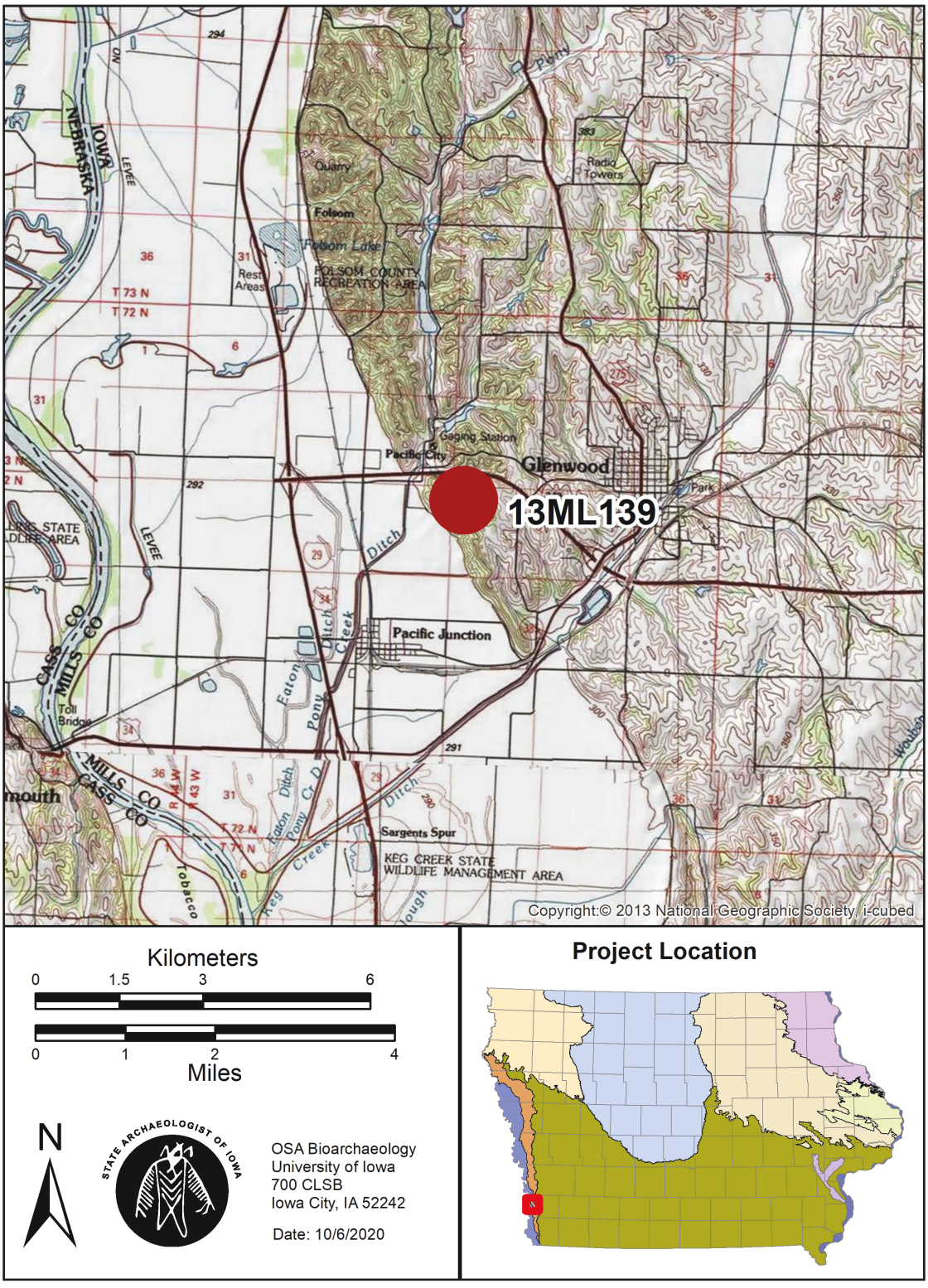

Figure 1. Location of 13ML139.
From USGS Pacific Junction, Mills County, Iowa (1993), 7.5' series quadrangle map. Scale 1:100,000.

A Partial Cranium Found in the Cedar River (13MC350) in Muscatine County, Iowa

Jennifer E. Mack

A partial human cranium found in the Cedar River by a private citizen in Muscatine County, Iowa, represents an adult of indeterminate sex. Biological affinity cannot be determined with certainty from the limited remains, and the original burial site was not identified. The individual is considered possibly Native American, based solely on the fact that Native American remains are more often discovered in rivers in Iowa than Euroamerican remains.

Introduction

On September 23, 2017, a private citizen discovered a partial human cranial vault on a sandbar in the Cedar River in Muscatine County, Iowa (Figure 1). The citizen contacted the Muscatine County Sheriff's Office, which took possession of the remains. On September 29, 2017, OSA Bioarchaeology Program Director Lara Noldner visited the findspot and determined that no additional human remains were present. No evidence of the original burial site was identified near the findspot. The closest previously recorded burial site on the Cedar River is 13MC336, a historic-period Native American burial located 6.25 miles upstream from the sandbar findspot (now designated 13MC350). The remains were transferred to the OSA Bioarchaeology Program on September 29, 2017 (UI, OSA 2017).

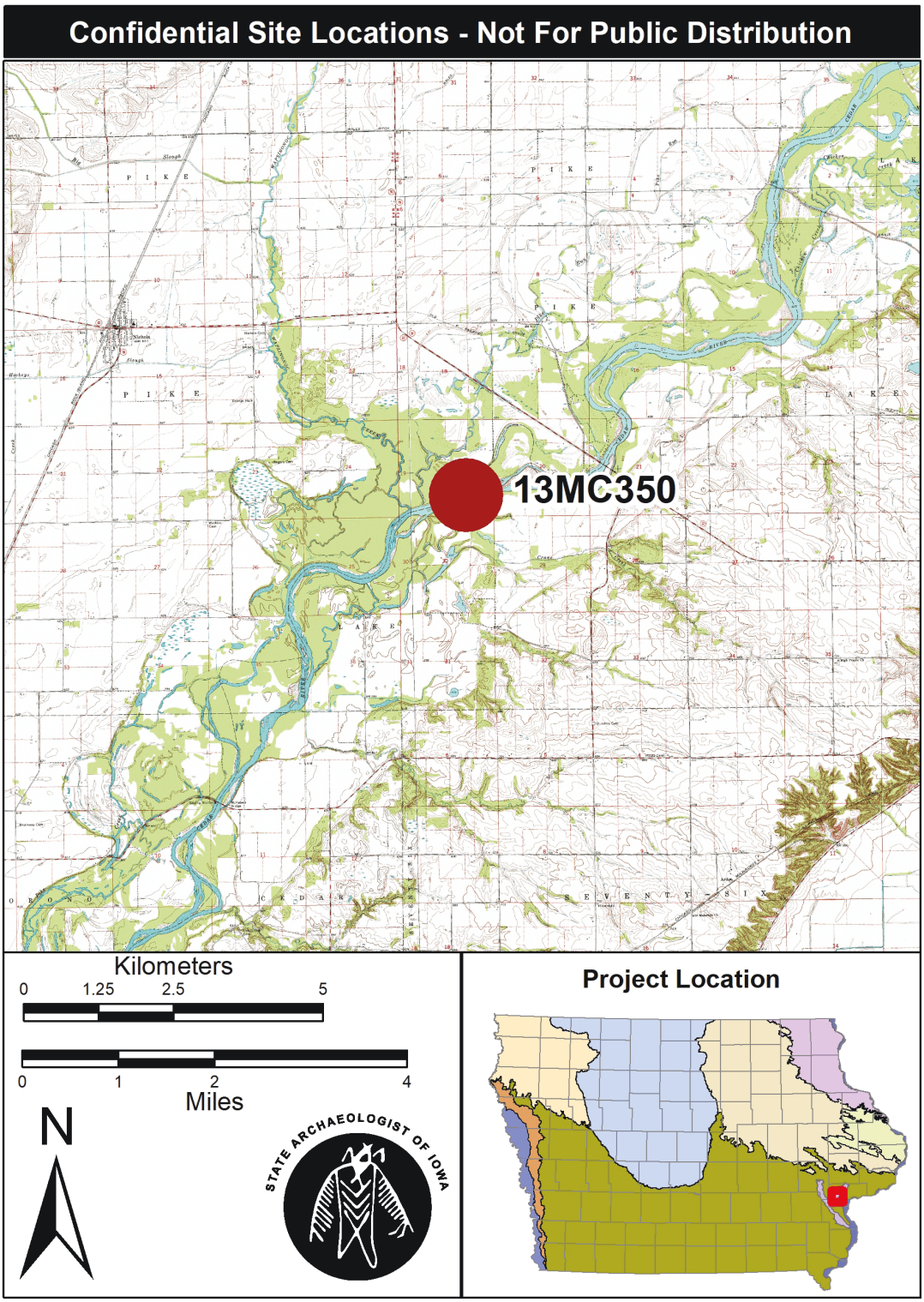

Figure 1. Findspot of human remains.
From USGS Muscatine NW, Muscatine County, Iowa (1978), 7.5' series quadrangle map. Scale 1:100,000.

Osteological Analysis

The cranial remains consist of a nearly complete left parietal fused to the anterior three-quarters of the right parietal. The right parietal is missing the area of the temporal suture, while the left temporal suture is represented only by the posterior-most portion. Slight sun-bleaching is evident on the ectocranial surface of the vault. The cortex on this surface, which was likely exposed for some time above the water or out of the soil at its original burial location, has suffered postmortem erosion and is exfoliating at the crown, to either side of the sagittal suture. The endocranial surface is darker and better preserved than the ectocranial surface, though it does not exhibit the dark brown coloring that would indicate years of exposure to riverine conditions. The fracture edges on the parietals are rounded, suggesting that the cranium was tumbled in the river and may have traveled a significant distance.

The coronal suture is open ectocranially and completely closed endocranially. The sagittal suture is completely obliterated on both the endocranial and ectocranial surfaces. With no additional observations, age cannot be accurately estimated. This level of fusion suggests the individual was a middle or old adult (>35 years). No sexually dimorphic characteristics were observable, so the sex of this individual is indeterminate. Lacking facial features, dentition, or metric data, this cranium could not be assessed for biological affinity. No pathology was observed.

With no skeletal indicators of biological affinity and no provenience for the human remains, ancestry cannot be determined with certainty. However, because the majority of identifiable crania recovered from rivers in Iowa have been determined to be Native American, and because a Native American burial site was reported upstream from the findspot, this individual is considered more likely to be Native American than Euroamerican.

References Cited

University of Iowa, Office of the State Archaeologist (UI, OSA)
2017 Burial Project 3287. On file, Office of the State Archaeologist, University of Iowa, Iowa City.

Disturbed Human Skeletal Remains Recovered from an Earthen Dam in Muscatine, Iowa

Jennifer E. Mack

Disturbed human remains collected from the ground surface of an earthen dam after trenching for utilities represent a minimum of one adult individual. The skeletal remains were likely previously disturbed during the construction of the dam, and the original burial location is unknown. The postmortem interval is greater than 54 years, based on context, and less than 120 years, based on preservation. Sex is indeterminate, and age is estimated as middle to old adult.

Introduction

On April 22, 2020, a private citizen contacted the Muscatine Police Department (PD) regarding human cranial remains discovered on an adjacent property (Figure 1). Muscatine PD responded to the scene, looked for additional remains on the ground surface, and, finding none, took custody of the cranial remains (Muscatine PD case # 20-013850). The remains were transferred to the Iowa Office of the State Medical Examiner (IOSME case# 20-02268). Forensic anthropologist Heather Garvin-Elling examined the remains, and though she could not determine the postmortem interval with certainty, she believed the cranial vault represented a disturbed coffined burial and thus had no forensic significance. Based on this finding, the remains were transferred to the Office of the State Archaeologist Bioarchaeology Program (OSA-BP) in May 2020.

On May 7, OSA-BP staff conducted a site visit to examine the area of exposed soil for additional remains or artifacts. Between the initial discovery and this site visit, the Muscatine Medical Examiner was regularly monitoring the area for additional remains, and during one visit recovered another human bone fragment. Two additional fragments were recovered during the OSA's site visit. OSA-BP staff interviewed the landowner and a former owner of the property for details regarding the timeline of disturbance to the area (UI, OSA 2020).

Background Research

The original statement collected by Muscatine PD regarding the origin of the disturbed soil in which the remains were found was incorrect. Though the informant believed the soil had originated from a basement excavated for a new house, the landowner claims that the soil was exposed during trenching for two separate utility lines along the earthen dam built in the past to retain a farm pond. OSA-BP staff examined all exposed soil during the site visit, including basement and foundation spoil piles and material from the utility trenches. No human remains or artifacts were found at any locations other than the slope of the earthen dam, and all human remains recovered likely originated from the 42 inch-deep water and sewer trench dug alongside the driveway on the dam. A shallower (ca. one foot deep) electrical trench running roughly west to east up the slope was later excavated, but the bone fragment found in this trench appeared to have fallen in from the surface.

Information from the landowner and a former landowner, confirmed by an article from *The Muscatine Journal* (1966), indicated that the artificial pond was created in 1966 by the construction of an earthen dam blocking a small drainage on the property. The current landowner suggested the dirt might have been brought in from another location. However, a former landowner believed that the soil originated from the widening and deepening of the drainage to create the pond. He further stated that no modifications to the dam had occurred during his ownership from 1980-2008. The original landowner who created the pond passed away in 1968 and could not be interviewed. The former landowner claims to have heard a rumor that human remains had been discovered during the creation of the pond and that archaeologists were called to the site but determined that the bones were not ancient. No mention of this discovery appears in the newspaper article about the pond (*The Muscatine Journal* 1966) or in files at the OSA. Archaeological surveys were conducted in the general vicinity of the site (now designated 13MC367) in the 1990s; it is possible that the presence of archaeologists was misinterpreted by some local residents. A mound site is located approximately 1 km (0.6 miles) to the southwest of the site and a historic cemetery is present 1 km (0.6 miles) to the north, but no burial sites have been documented any closer.

Working under the assumption that the skeletal remains may have originated from the same property where they were found, OSA-BP staff checked maps and aerial photographs for any evidence of a cemetery or church at that location in Section 30, Township 77 North, Range 1 West. Maps from 1838, 1874, 1875, 1884, 1899, 1916, 1921, and 1930 showed no such land usage. Aerial photographs from the 1930s, 1950s, 1960s, and 1970s show various structures—probably farm buildings—to the west of the dam area.

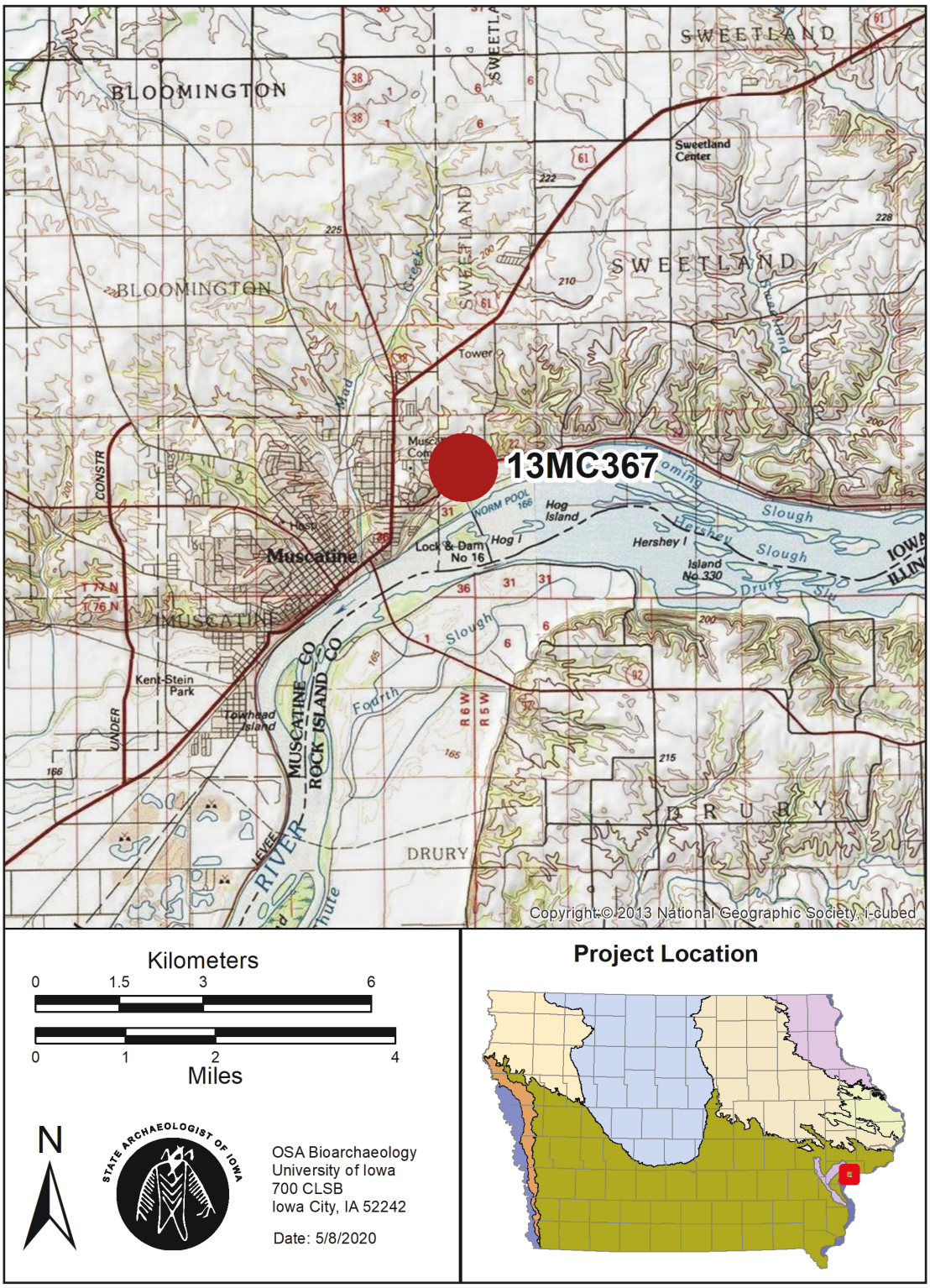

Figure 1. Findspot of human remains, 13MC367.
From USGS Muscatine, Muscatine County, Iowa (1991), 7.5' series quadrangle map. Scale 1:100,000.

Osteological Analysis

The remains recovered from the earthen dam to date consist of a partial cranial vault, a small unsided rib fragment, a fragment of right ilium, and a complete distal foot phalanx from the first digit. The cranial vault consists of the posterior two-thirds of both parietals and the squamous portion of the occipital with just the posterior margin of the foramen magnum. The squamous sutures are absent from both parietal portions. The fracture edges of the parietals are relatively straight and have no dirt embedded. Based on the light coloring of the exposed cortical profile and diploë, the breakage occurred relatively recently, and refitting cranial fragments are very likely still onsite. The MNI for the remains is one, as all elements are adult, and no distinguishing characteristics exclude them from representing the same individual.

The sex of the individual is indeterminate. Though there is no prominence at the nuchal crest, this single observable sexually dimorphic feature is not sufficient for the estimation of sex. Few indicators of age are observable. Given the significant closure of the sagittal suture and superior portions of the lambdoidal sutures, the individual is likely a middle or old adult.

Minor pathology was noted on the cranium and foot phalanx. The very well-preserved, ivory-colored portion of the posterior left parietal exhibits pinpoint, healed porosity. The right parietal is not observable for similar porosity due to cortical flaking. This porosity could be related to a periosteal reaction. Porotic hyperostosis is unlikely as the diploë exposed by fracturing appears normal. The margins of the proximal articular surface of the distal foot phalanx exhibit moderate lipping associated with age and joint degeneration.

A fracture is present along the left lambdoidal suture. This fracture extends across individual sutural fingers on the ectocranial surface but appears on the endocranial surface as a diastasis (sutural separation). The color of the fracture edges is the same as the surface bone, indicating that the damage is not recent and is possibly perimortem. The right lambdoidal suture exhibits a similar, though smaller, sutural separation. This bilateral diastatic fracturing could be related either to perimortem trauma or to ground pressure (Campobasso et al. 2019; Grossart and Samuel 1961).

Condition and Taphonomy

The initial report prepared by the state forensic anthropologist noted an unusual mix of preservation which prevented a confident estimate of postmortem interval. This differential preservation was fully documented and is presented here to provide comparative data for future inadvertent discoveries of human remains from uncertain contexts.

The endocranial surface is well-preserved, with warm brown staining, a little black speckling, and a significant amount of root-etching, especially on the right parietal and occipital. All of these features are consistent with decomposition in a burial context, as observed in skeletal remains from both prehistoric and historic graves in Iowa. The ectocranial surfaces of the anteromedial portions of the parietals are stained the same brown as the endocranial surface. Approximately 23 mm anterior to the parietal foramina, an irregularly-shaped 29 mm-long green stain is present, crossing the sagittal suture transversely. Though the stain does not have the slight blue tint often associated with copper salt staining, and though algae staining is present elsewhere on the cranium, this parietal stain is likely due to contact with a copper object in the burial context, as staining was found underlying the soil and was not visible before the cranium was cleaned.

The anterolateral portion of the left parietal exhibits poorer preservation, with a slightly grayer brown color, black speckling, and some cortical flaking. The endocranial surface of this location exhibits a concentration of black speckling. The surficial appearance is consistent with human remains from historic, coffined burials, though the good bone density preserved beneath the flaking surface is inconsistent with nineteenth century remains previously excavated by the OSA-BP. Posterior to the left parietal foramen, a band of extremely well preserved bone is present, extending laterally to the broken inferior edge of

the parietal. The ivory color and lack of cortical erosion are inconsistent with human remains recovered from ancient or historical burial contexts (>150 years) in Iowa. A small amount of root etching, though, demonstrates that this portion of the skull was also previously exposed to plant growth.

A small area of ivory-colored bone is present on the inferior broken edge of the right parietal, as well. A crack measuring 46 mm originates in this area. This fracture does not extend through to the endocranial surface. Based on the light-colored fracture edges, it appears the crack is postmortem and recent, perhaps from ground pressure or heavy machinery action. The posterior portion of the right parietal exhibits black speckling and cortical flaking, again consistent with historic-period burial contexts. The corresponding area of the endocranial surface exhibits a concentration of root etching.

The occipital exhibits the greatest extremes in preservation. The bone around the inferior portion of the left lambdoid suture and the left occipitomastoid suture is ivory colored with almost no cortical erosion or root etching. The bone around the posterior margin of the foramen magnum is also ivory colored, but exhibits significant etching, cortical erosion, and a small amount of algae growth. The rest of the occipital squama exhibits significant cortical erosion, with the perforation of an exceptionally thin portion at the location, endocranially, of an arachnoid fovea. The white color of the eroded bone in places (slight sun-bleaching), the presence of algae growth, and the fact that no soil was present on the occipital when the remains were collected by the police all indicate that the occipital was exposed for a period of time while the rest of the cranial vault was still covered with soil. A small amount of brown cortical bone present on a margin of the weathered area indicates that the flaked away portions were likely somewhat degraded prior to the exposure weathering. Significant root etching is present on the endocranial surface of the occipital, especially on the more poorly preserved right half of the squama.

Similarly mixed preservation is present on the foot phalanx, which exhibits weathering, cortical erosion, and sun-bleaching on the dorsal surface and brown staining and cortical erosion on the plantar surface, with a core of dense, well-preserved, ivory-colored bone visible in the proximal articular surface.

Interpretations

From this lengthy discussion of preservation and taphonomic observations, several plausible conclusions can be drawn. Evidence suggests this cranial vault originated from a buried context and was redeposited at the discovery location. Recent breakage indicates that more portions of the cranial vault are likely still present in the vicinity of the discovery. In the original burial context, the cranium was likely resting on the right portion of the occipital squama and the posterior portion of the right parietal. During decomposition, a copper or copper-alloy object was resting against the posterior portion of the "top" of the skull. Weathering and algae growth indicate that the occipital was exposed while the rest of the cranial vault was still covered with soil, potentially for around one month, based on the landowner's timeline of utility trench installation.

Two crucial issues remain unresolved—the age of the remains and the original burial context type. Portions of the cranium exhibit better preservation than that observed on any skeletal elements excavated from historic burials in Iowa, with comparative samples dating from ca. 1833-1930. Preservation can vary based on soil conditions, water drainage, coffin construction (if coffined), and treatments such as embalming, so it is not possible to state with certainty that the remains are more recent than 1930. However, this individual's death likely dates to the twentieth, rather than the nineteenth, century.

Regarding burial context, the original report's conclusion that the remains likely originated from a coffined burial hinges on two observations. The darker, mottled brown staining on the ectocranial surface was identified as possibly due to contact with coffin wood. While this staining does appear on historic coffined burials, similar staining has been found on prehistoric Native American crania from uncoffined burials in Iowa. The second reported observation was coffin wear. Though some publications describe the differential preservation occurring at pressure points in contact with a coffin floor as the result of "minor,

repeated movement" (Rogers 2005), the term "coffin wear" is misleading. The poor preservation at pressure points observed in some coffined burials is the result of the pooling of decomposition fluids and acidic groundwater around bone portions in contact with a relatively non-porous surface (Pokines et al., 2016). Because coffins provide both a non-porous surface and void in which fluids can collect, they are probably the burial context that most commonly produces such differential preservation. However, burial in any type of container or burial at a depth affected by a fluctuating water table could also result in damage to the inferior-most portions of the skeleton. In this case, it is likely that the recently exposed occipital weathered so quickly because the bone was already compromised by differential deterioration at a pressure point in the original burial context. However, though the evidence is suggestive, this differential preservation is not proof that the individual was buried in a coffin.

In discussion with Dr. Garvin-Elling, a few explanations for the variable preservation were proposed. Excellent preservation is seen in early cast-iron caskets that have remained sealed, but materials in these caskets usually have rust staining, which was not observed on the remains in this case. Bone preservation is sometimes affected by the presence of hair and/or soft tissues. An individual excavated from Dubuque's Third Street Cemetery (ca. 1833-1880) exhibited better cranial bone preservation below a mass of preserved hair. In that case, however, the protected bone was stained brown, like the rest of the cranium (Lillie and Mack 2013). The presence of a copper or copper-alloy object in the grave (as evidence by green staining on the cranium) can lead to preservation of materials such as hair and skin in contact with the object, as the copper salts produced by corrosion are toxic to microorganisms which would normally consume organic matter in the grave (Beck 2014; Trevors and Cotter 1990). Another possibility is that embalming lead to superior preservation of portions of soft tissue and bone. Absent any solid evidence for postmortem interval or burial context, a test for the presence of embalming chemicals might establish whether or not these remains originated from a formal burial.

Conclusions

The remains recovered from this site appear to represent a single middle to old adult individual of indeterminate sex. Green staining on the parietals indicates contact with a copper object during decomposition. Pathological observations include slight porosity on the left parietal and moderate lipping on the articular surface of the left first distal foot phalanx. Diastatic fractures along both lambdoid sutures may be taphonomic or related to perimortem trauma.

Overall, preservation indicates the relatively modern origin of the remains (twentieth century, <120 years) or decomposition in an unusual burial environment. Based on documentation of the creation of the earthen dam in 1966 and witness statements that the dam has not been altered in the last 40 years, the minimum postmortem interval is likely 54 years. Though the possibility that an individual was buried in the dam at the time of its creation cannot be entirely ruled out, the distribution of the remains makes this scenario unlikely. Multiple regions of the body are represented by the recovered skeletal remains. If an articulated skeleton were disturbed to this extent during recent trenching activities, workers could be expected to see and recognize the remains as human. A more likely sequence of events is that a burial or burials were disturbed during the digging of soil for the dam. The skeletal remains were disarticulated in this process and redeposited as part of the dam. These dispersed remains were then further disturbed during the creation of utilities trenches, and some elements were brought to the surface. This slope will continue to be monitored by the landowner and the Muscatine County Medical Examiner. The discovery of additional remains and associated artifacts (such as clothing fasteners or coffin hardware) may clarify the postmortem interval and original burial context. To date, no historic documentation has been located which would suggest a pioneer or family cemetery existed on this property.

References Cited

Beck, Margaret
2014 Site and Artifact Preservation: Natural and Cultural Formation Processes. In *Encyclopedia of Global Archaeology*, edited by C. Smith, pp.6683-6687. Springer Science + Business Media, New York.

Campobasso, Carlo Pietro, Francesco De Micco, Valentine Bugelli, Antonio Cavezza, William C. Rodriguez, and Bruno Della Pietra.
2019 Undetected Traumatic Diastasis of Cranial Sutures: A Case of Child Abuse. *Forensic Science International* 298:307-311.

Grossart, K.W.M., and Eric Samuel
1961 Traumatic Diastasis of Cranial Sutures. *Clinical Radiology* 12(3):164-170.

Lillie, Robin M., and Jennifer E. Mack
2013 *Bioarchaeology and History of Dubuque's Third Street Cemetery, 13DB476, Dubuque County, Iowa.* OSA Research Papers Vol. 37, No. 1. Office of the State Archaeologist, University of Iowa, Iowa City.

The Muscatine Journal
1966 "Farm Pond Construction Continues in County." 16 December:12. Muscatine, Iowa.

Pokines, James T., Debra Prince Zinni, and Kate Crowley
2016 Taphonomic Patterning of Cemetery Remains Received at the Office of the Chief Medical Examiner, Boston, Massachusetts. *Journal of Forensic Sciences* 61(S1):S71-S81.

Rogers, Tracy L.
2005 Recognition of Cemetery Remains in a Forensic Context. *Journal of Forensic Sciences* 50(1):1-7.

Trevors, J.T., and C.M. Cotter
1990 Copper Toxicity and Uptake in Microorganisms. *Journal of Industrial Microbiology* 6:77-84.

University of Iowa, Office of the State Archaeologist (UI, OSA)
2020 Burial Project 3503. On file, Office of the State Archaeologist, University of Iowa, Iowa City.

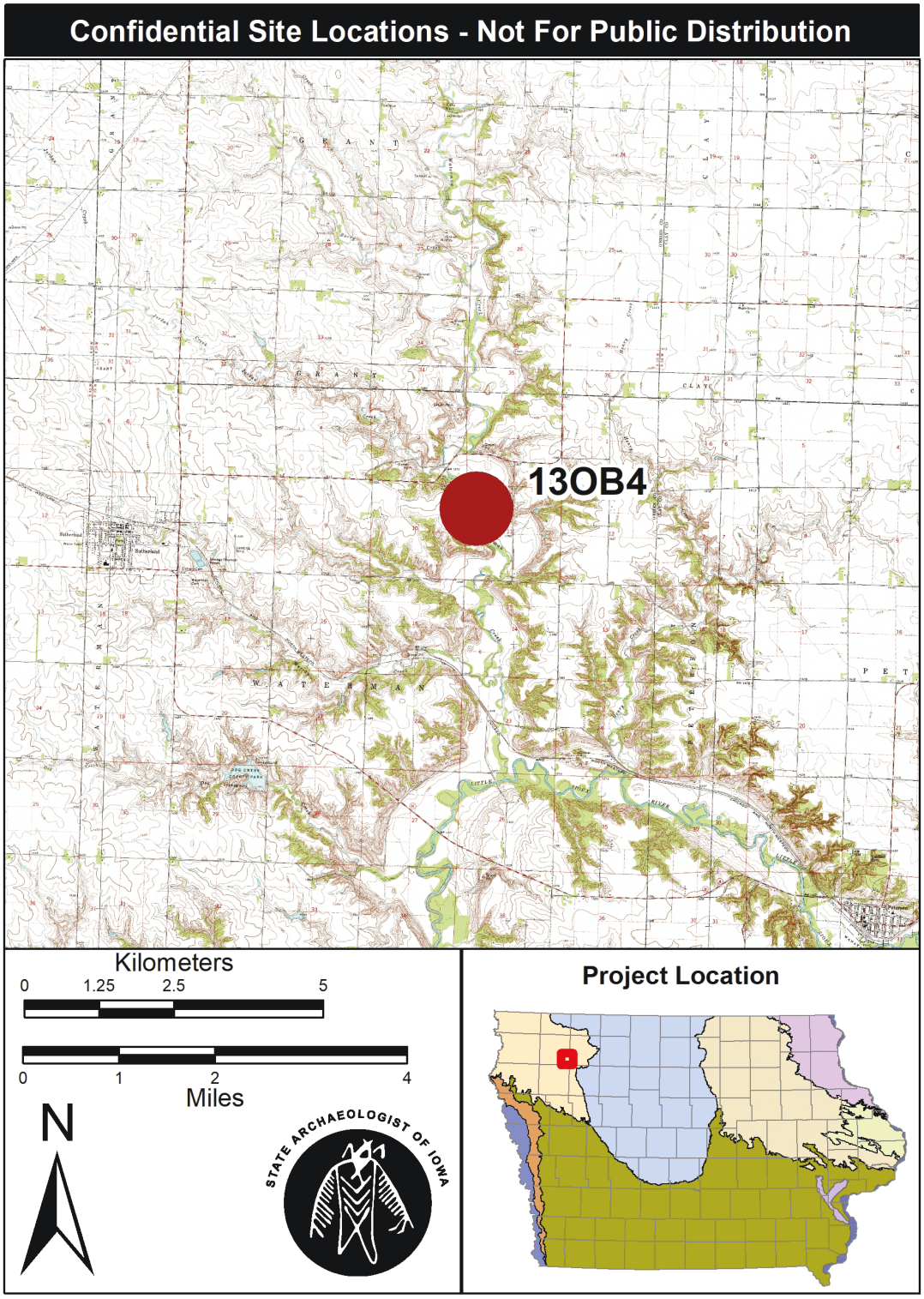

Figure 1. Location of 13OB4.
From USGS Sutherland East, O'Brien County, Iowa (1971), 7.5' series quadrangle map. Scale 1:100,000.

Isolated Skeletal Remains from The Wittrock Site (13OB4), O'Brien County, Iowa

Jennifer E. Mack

Human skeletal remains representing a minimum of three individuals were recovered from various non-mortuary contexts at the Wittrock Site (13OB4) in O'Brien County, Iowa, during excavations in 1959 and 1963. Two adolescents and an adult are represented by these remains. Based on provenience, cultural affiliation is likely Mill Creek.

Introduction

In 2015, a review of faunal bone collections from the Wittrock Site (13OB4, Figure 1) stored in the repository of the Office of the State Archaeologist (OSA) discovered 11 isolated human elements recovered from excavations in the mid-twentieth century (UI, OSA 2014). The elements were recovered from at least seven different locations in general site fill, with a single unfused epiphysis found in pit feature 4 (1963 excavation). These human remains were transferred to the OSA Bioarchaeology Program for analysis and repatriation.

The Wittrock Site is located in the NW¼ of Section 11, T94N, R39W, O'Brien County, Iowa (Figure 1). Archaeological excavations of this Mill Creek village were conducted by the University of Iowa in 1959 and 1965, and by the University of Wisconsin-Madison in 1963. The results of these excavations are summarized by Anderson (1985). Human skeletal remains recovered during these fieldwork episodes were previously reported (Fisher 1978, Lillie 2014). The isolated elements were found in house pits and fill, and there was no archaeological evidence to suggest a mortuary context. The previously reported remains represent a child 6 to 8 years old, an adolescent approximately 14 years old, and three adults (one middle-aged female and two possible males).

Osteological Analysis

Human remains analyzed during the current project include one damaged tooth, three unfused femoral heads, and seven hand and foot elements (Table 1). Almost all enamel from the tooth crown was broken off postmortem, but it appears to be a completely developed mandibular premolar, possibly from the left side; it was found in Square S-21-C, 0-28 inches depth. Hand elements include an incomplete metacarpal (probably a left 5th), an unsided proximal phalanx, middle phalanx, and two distal phalanges (from S-17-B, S-19-B, S-21-C, and S-16-A, respectively). Foot elements include a right 5th metatarsal (S-20-B) and a proximal phalanx (provenience unknown).

Three unfused femoral heads were recovered. All were adult-sized, and no signs of fusion were visible on the undamaged portions, suggesting an age range of 13 to 19 years for all three. Two femoral heads were found in the same excavation unit, N-18-C, at 0-28 inches and 03-32 inches of depth, respectively. Both of these heads appear to be from the left sides, and the deeper one appears to be slightly smaller, though postmortem damage prevents accurate diameter measurements. The side of the third femoral head could not be determined, due to postmortem damage. It was found in Feature 4, Level 8 (42-48 inches) during the

1963 excavation. The epiphyseal surface appears morphologically dissimilar to the other unfused heads, and therefore the element could represent a third adolescent individual. However, too much of the surface is unobservable to make this determination. A cautious estimate of the minimum number of individuals (MNI) represented by this collection is three, including two adolescents represented by the two left femoral heads and one adult represented by the mature hand and foot bones.

No pathology was noted on any of the remains except for very slight lipping on the proximal articular surface margins of a distal hand phalanx. Old postmortem damage to the dorsal surface of the metacarpal shaft represents either three converging transverse cutmarks which removed a piece of bone measuring 1.4 mm wide or an atypical isolated rodent gnaw mark.

Summary

The 11 elements in this limited collection of isolated human remains recovered from 13OB4 in 1959 and 1963 represent three individuals, including two adolescents (13 to 19 years old) represented by unfused left femoral heads and one adult represented by mature hand and foot bones. However, the addition of this collection to previously analyzed remains only increases the site-wide MNI by one. The mature hand and foot elements could easily belong to one of the previously reported three adults, while one of the unfused femoral heads might belong to the previously analyzed 14-year-old. Therefore, only the second adolescent is added to the MNI for 13OB4, which now includes a child 6 to 8 years, an adolescent around 14 years, an adolescent 13 to 19 years, and three adults (one middle-aged female and two possible males).

References Cited

Anderson, Duane C.
1985 *Excavations at the Wittrock Site (13OB4): A Compilation of Information Pertaining to Projects Conducted in 1959 and 1965*. Research Papers 10(1). Office of the State Archaeologist, University of Iowa, Iowa City.

Fisher, Alton K.
1978 Human Remains from the Wittrock Site, 13OB4. In *Report on Human Remains from Six Archaeological Sites*, edited by Alton K. Fisher. Research Papers 3(4):1-5. Office of the State Archaeologist, University of Iowa, Iowa City.

Lillie, Robin M.
2014 A Human Patella and Two Teeth from 13OB4, The Wittrock Site, O'Brien County, Iowa. In *Reports on Burial Projects, Osteology and Archaeology,* edited by Robin M. Lillie and Shirley J. Schermer, pp. 135-137. Research Papers 38 (1). Office of the State Archaeologist, University of Iowa, Iowa City.

University of Iowa, Office of the State Archaeologist (UI, OSA)
2014 Burial Project 3095. On file, Office of the State Archaeologist, University of Iowa, Iowa City.

Table 1. Commingled Remains, Burial Project 3095, 13OB4

Element	Number of Fragments/ Elements	MNE Left	MNE Right	MNE Midline	MNE Unsided
Mandibular teeth	1	1			
Metacarpals	1	1			
Hand phalanges	4				4
Femur	3 (adolescent)	2			1
Metatarsals	1		1		
Foot phalanges	1				1

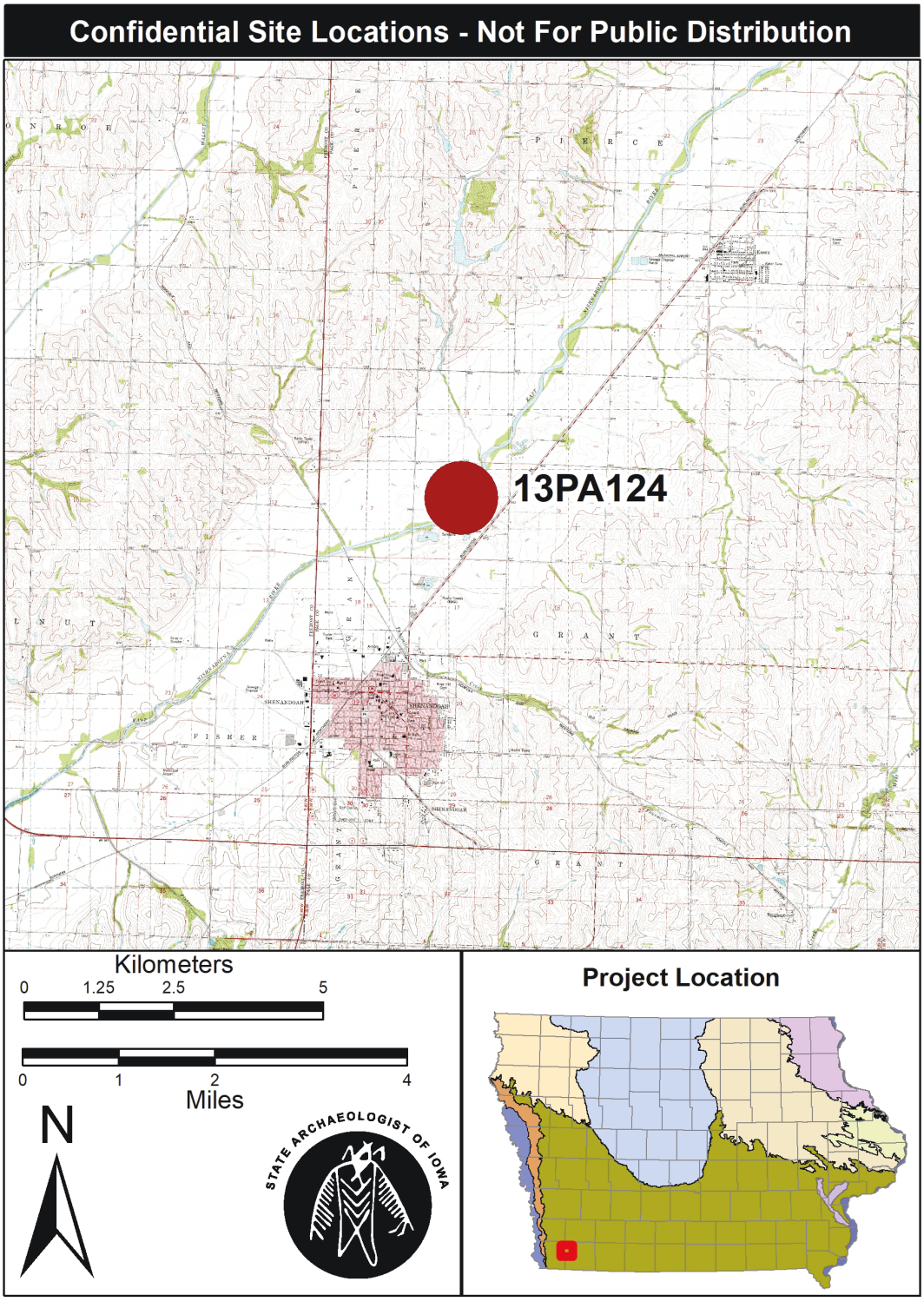

Figure 1. Findspot of human remains, 13PA124.
From USGS Shenandoah East, Page County, Iowa (1978), 7.5' series quadrangle map. Scale 1:100,000.

A Human Cranium Found on a Sandbar in the East Nishnabotna River, Page County, Iowa (13PA124)

Jennifer E. Mack

A partial cranium discovered out of context on a sandbar in the East Nishnabotna River in Page County, Iowa, represents a middle adult female. The remains were determined to be likely Native American based on cranial metrics and dental morphology. Cultural affiliation could not be determined. No pathology was observed.

Introduction

On July 1, 2019, kayakers on the East Nishnabotna River in Page County, Iowa, notified the Page County Sheriff's Office that they had discovered a human cranium on a sandbar in the river (Figure 1). Deputies collected the human remains and sent them to the Iowa Office of the State Medical Examiner (IOSME case #19-03834). The consulting forensic anthropologist from Des Moines University, Dr. Heather Garvin-Elling, determined that the remains were too old to be of forensic interest, and likely Native American. The cranium was transferred to the Iowa Office of the State Archaeologist on August 1, 2019 for further investigation and repatriation, if appropriate (UI, OSA 2019).

Osteological Analysis

The remains consist of the complete left side of the cranium and portions of the right side. Most of the right parietal is absent, except for a portion along the sagittal suture. The right zygomatic and temporal are absent, as is the right one-third of the maxilla, frontal, and occipital. The broken edges of the extant cranial bones are dark in coloration and most have slightly rounded edges, indicating postmortem fracturing occurring in the distant past. Sharper edges are noted on some of the thinner bones of the face, such as the nasals and right maxilla, which likely indicate more recent damage.

Differential staining evident on the skull is related to the burial environment. The facial skeleton and all extant portions of the right half of the cranium are darkly stained, both endocranially and ectocranially. The left half of the occipital and posterior portions of the left parietal and temporal are lighter in color, again both endo- and ectocranially. An algae stain is present on the ectocranial surface at the border of the color change. The differential staining suggests that all but the posterior left portion of the cranium was submerged in water for a significant period of time. Postmortem erosion and pitting are present on the darker, water-exposed portions of the cranium.

The degree of cranial suture closure suggests an age of 27 to 51 years. The level of dental wear, with dentin exposed on all teeth present except the maxillary left third molar, indicates the individual was not on the younger end of the range. The lack of wear on the third molar and lack of antemortem tooth loss both suggest the individual was not an old adult. Age was estimated to be 30 to 40 years, a younger middle adult.

All observable sexually dimorphic features are intermediate. The orbital margin is neither sharp nor robust, and a small prominence is present at glabella. The nuchal crest, which has some postmortem damage, is rugose though not pronounced. The mastoid process is broken, and the mandible is absent. However,

when the cranial metrics (Table 1) were entered into the FORDISC discriminant function analysis software and both sexes were selected for comparison, the results strongly suggested female sex.

FORDISC analysis was also used to determine ancestry, as the morphological traits of the cranium are indeterminate. The individual has a somewhat rounded palate and a trace of a malar tubercle, but also exhibits nasal guttering and a receding zygomatic. When the metrics from the partial cranium were input and compared with those of nineteenth-century White and Black females and Arikara females in the Howells dataset, the individual was found to be closest Arikara females. However, the results indicated the morphology of the cranium was atypical for Arikara. The low typicality probabilities were related to the abnormally long occipital chord measurement, which was due to unusual suture lines forming a partial apical bone. When the occipital chord measurement was eliminated, the individual was again found to be closest to Arikara females, with a posterior probability of 0.989 and higher typicality probabilities (cross-validation rate 87.0%). Dental morphological analysis following Scott et al. (2018) was also attempted, though only seven of the possible 21 morphological traits are observable. When these traits were entered into the rASUDAS web-based application for bio-geographic ancestry determination (https://osteomics.com/rASUDAS/) and compared against individuals of American Indian, Sub-Saharan African, and Western Eurasian origin, the individual from 13PA124 was found to be closest to American Indians, with a probability of 0.9226.

Dental remains are limited as the mandible is not present and several teeth were lost postmortem, including all anterior teeth; see Table 2 for a complete dental inventory. The teeth still present are heavily worn, which also prevented observation of some morphological traits. Measurements could only be taken at the cemento-enamel junction (see Table 3). A small amount calculus is still present on the teeth, despite exposure in the river, but no carious lesions were observed. No teeth were lost antemortem, suggesting relatively good dental health. No dental or cranial pathologies were observed.

Summary

The partial cranium found on a sandbar in the East Nishnabotna River represents a middle adult female. Based on cranial metrics, dental morphology, and the context of the discovery, the remains likely represent an individual of Native American ancestry from the prehistoric or historic period. Without further context information, cultural affiliation cannot be determined.

References Cited

Scott, G. Richard, Marin A. Pilloud, David Navega, Joao d'Oliveira Coelho, Eugenia Cunha, and Joel D. Irish
2018 rASUDAS: A New Web-Based Application for Estimating Ancestry from Tooth Morphology. *Forensic Anthropology* 1(1).

University of Iowa, Office of the State Archaeologist (UI, OSA)
2019 Burial Project 3456. On file, Office of the State Archaeologist, University of Iowa, Iowa City.

Table 1. Cranial Metrics (mm), Burial Project 3456, 13PA124

Cranial metric	
Maximum cranial length	171
Basion-bregma height	138
Cranial base length	96
Basion-prosthion length	94
Maxillo-Alveolar breadth	57
Maxillo-Alveolar length	52
Upper facial height	67
Nasal height	48.5
Nasal breadth	26
Orbital breadth L	37
Orbital height L	33
Interorbital breadth	21
Frontal chord	109
Parietal chord	102
Occipital chord	110
Foramen magnum length	35
Foramen magnum breadth	30.5

Table 2. Dental Inventory, Burial Project 3456, 13PA124

Tooth	Presence	Attrition:	Attrition- molars:			
		I, C, P	Mes-buc	Mes-ling	Dis-ling	Dis-buc
MAXILLA:						
RM3	5					
RM2	2		3	6	5	4
RM1	2		6	7	7	6
RP2	5					
RP1	2	5				
RC	5					
RI2	5					
RI1	5					
LM3	2		1	2	2	1
LM2	2		4	6	5	5
LM1	2		6	7	7	6
LP2	2	5				
LP1	2	5				
LC	5					
LI2	5					
LI1	5					

Dental Inventory Key:
Presence
1 Present but not in occlusion
2 Present, development completed, in occlusion
3 Missing, with no associated alveolar bone
4 Missing, with alveolus resorbing or fully resorbed: antemortem loss
5 Missing, with no alveolar resorption: postmortem loss
6 Missing, congenital absence
7 Present, damage renders measurements impossible
8 Present but unobservable (e.g. teeth in crypts)
9 Unobservable
Attrition (I, C, PM)
5 Large dentin area with rim complete (two areas on premolars)

Attrition (molars)
0 Unobservable
1 Wear facets invisible or very small
2 Wear facets large, but cusps and surface features still evident
3 Any cusp in quadrant is rounded, but not flat
4 Quadrant is worn flat, but no dentin is exposed (except pinprick-sized)
5 Quadrant is flat, dentin exposed on ¼ of quadrant
6 More than ¼ of dentin is exposed, with enamel ring still complete
7 Enamel is found on only two sides of quadrant
8 Enamel on only one side of quadrant, but enamel is still thick
9 Enamel on only one side of quadrant and it is very thin
10 No enamel remaining. Wear extends below the cervicoenamel junction onto the root

Table 3. Dental Metrics (mm), Burial Project 3456, 13PA124

Tooth	Mesiodistal	Buccolingual	CEJ mesiodistal	CEJ buccolingual
MAXILLA:				
RM2			8.7	9.7
RM1			8.0	10.8
LM3			8.2	9.7
LM2			8.2	
LM1			7.8	11.3
LP2				8.5
LP1			5.0	7.8

Maxillary Molar Recovered from Historic Trash Deposit (13PA126) in Page County, Iowa

Jennifer E. Mack

A human molar recovered from a historic trash deposit in Page County, Iowa, was likely extracted or lost naturally through abscessing and does not represent a human burial. The presence of an amalgam dental filling indicates the tooth dates to the historic period. The potential for additional human remains at this site is low.

In September 2020, a human tooth was encountered during an archaeological survey conducted by the University of Iowa Office of the State Archaeologist (OSA) in Page County, Iowa. The tooth was discovered in a historic trash deposit—now designated 13PA126—along with materials dating from circa 1870 to the 1920s (Figure 1). No other human remains were observed at this site (UI, OSA 2020).

The tooth, which was broken into three pieces, appears to be a maxillary right first molar. This identification is not certain as portions of the tooth are still missing after reconstruction. Breakage occurred around the edges of a large dental filling, which extended along most of the mesial-distal axis of the tooth. The filling material is dark gray with a lighter gray patina on the occlusal surface, consistent with some type of silver-based amalgam. It appears that the tooth continued to decay after filling, with the cavity eventually intruding on the pulp chamber. For this reason, it is presumed that the tooth was extracted or was perhaps lost through abscessing. Unfortunately, most of the roots are missing and cannot be examined for pressure resorption that would indicate a periapical abscess. Whether removed or naturally lost, the condition and non-burial context of the discarded tooth suggest that the dump site has little potential for additional human remains.

Amalgam dental fillings were first introduced to the United States in 1833 and continue to be used in the twenty-first century (Ramesh *et al.* 2010). Therefore, the filling material does not provide a narrower date range than the associated artifacts in the trash deposit (1870s-1920s). Ancestry is indeterminate for this single tooth, but its context suggests it originated from a Euroamerican or other settler, rather than a Native American individual.

References Cited

Ramesh, Bharti, Kulvinder Kaur Wadhwani, Aseem Prakash Tikku, and Anil Chandra
2010 Dental Amalgam: An Update. *Journal of Conservative Dentistry* 13(4):204-208.

University of Iowa, Office of the State Archaeologist (UI, OSA)
2020 Burial Project 3536. On file, Office of the State Archaeologist, University of Iowa, Iowa City.

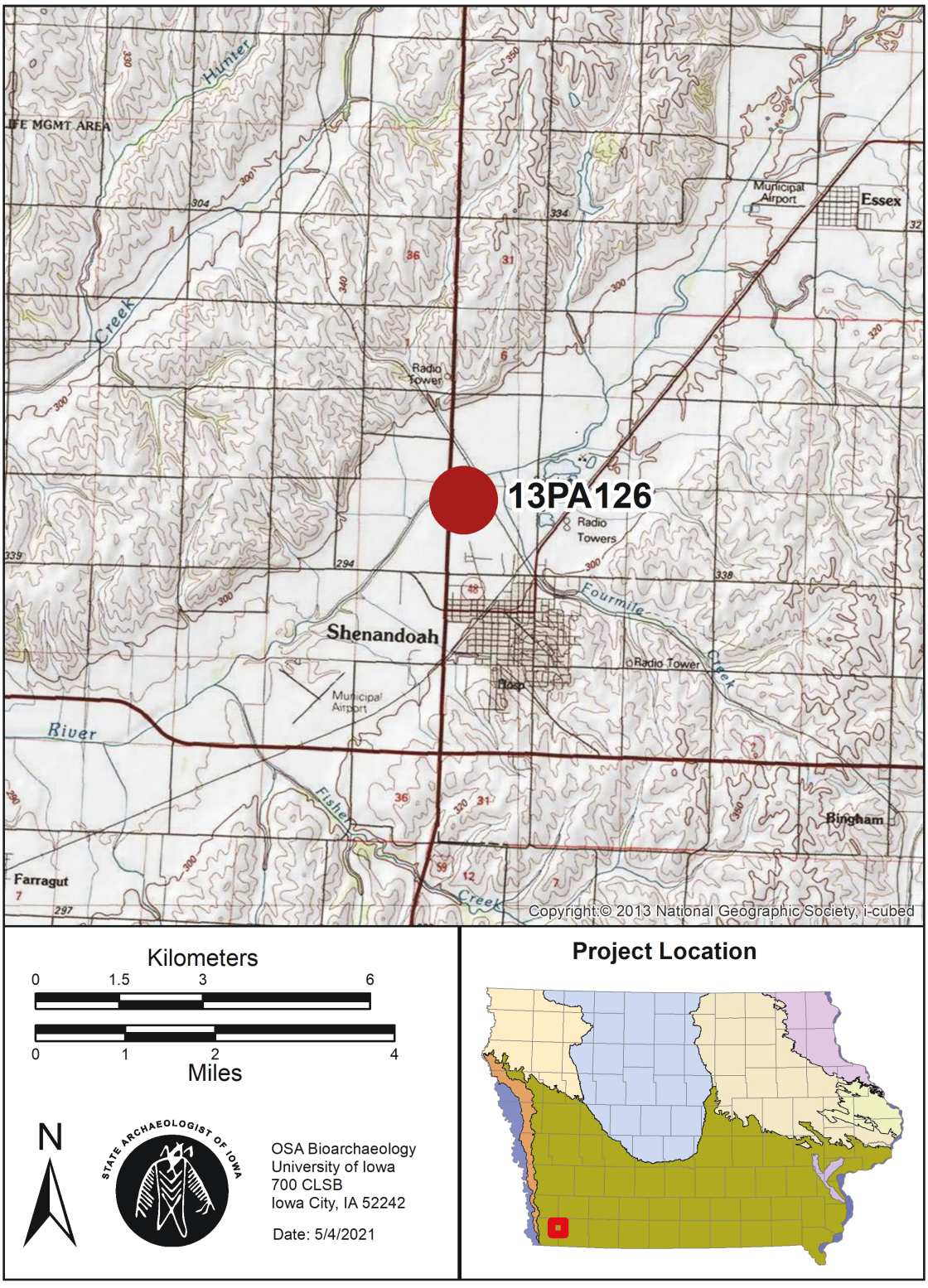

Figure 1. Findspot of dental remains, 13PA126.
From Shenandoah West, Page County, Iowa (1978), 7.5' series quadrangle map. Scale 1:100,000.

A Human Tooth Recovered from 13PK38 in Polk County, Iowa

Jennifer E. Mack

An isolated human tooth recovered during excavations at 13PK38 in 1963 represents an adult of unknown age and sex. Artifacts found in context with other human remains at this site, indicate affiliation with the Great Oasis cultural complex.

In 2018, a private citizen contacted the Office of the State Archaeologist Bioarchaeology Program (OSA-BP) about a human tooth she had inherited from her grandfather, who owned a business close to the West Des Moines burial site (13PK38, Figure 1) at the time of its excavation. The tooth, which was reportedly given to the business owner by one of the excavators, was transferred to the OSA-BP for proper disposition or repatriation (UI, OSA 2018).

The West Des Moines burial site, 13PK38, was disturbed in 1963 during construction of the Crestview Acres retirement facility. Approximately 75% of the site was destroyed before archaeologists could intervene. In July of that year, Jack Musgrove, curator, and Richard Boyt, museum director, of the Iowa Department of History and Archives (now the State Historical Society of Iowa) excavated the remaining burials from the construction project area. Looting and souvenir-taking of both artifacts and human remains occurred before, during, and after the official excavation, and thus much of the material ended up in private collections. Artifacts recovered from the organized excavation and analyzed by professional archaeologists—including the famous shell "crosses," numerous shell beads, ceramics, and chipped and ground stone tools—indicate that the site was used by people of the Great Oasis cultural tradition ca. 900-1100 AD (Tiffany and Alex 2001). Human remains previously transferred to the OSA, representing a minimum of 15 individuals, were reburied in 2001 (UI, OSA 1979, 1982, 1988, 1995).

The tooth transferred to the OSA in 2018 appears to be a mandibular right second molar, as the crown has both mesial and distal contact facets and the two roots are separate but very close together. Dental wear is moderate, with the cusps worn flat and only pinpoint dentin exposure except for the mesiobuccal cusp, which has less than 1/4 dentin exposure. This individual was likely an adult, since the second molar is not unworn, but there is clearly not enough wear to indicate an old adult. The mesial root surface exhibits some decalcification just inferior to the CEJ, but a carious lesion had not yet formed at the time of death. The crown measures 11.6 mm mesiodistally and 10.3 mm buccolingually, with measurements at the CEJ 8.6 mm and 8.0 mm, respectively.

References Cited

Tiffany, Joseph A., and Lynn M. Alex
2001 Great Oasis Archaeology: New Perspectives from the Decamp and West Des Moines Burial Sites in Central Iowa. Memoir 33, *Plains Anthropologist* 46(178).

University of Iowa, Office of the State Archaeologist (UI, OSA)
1979 Burial Project 129. On file, Office of the State Archaeologist, University of Iowa, Iowa City.
1982 Burial Project 172. On file, Office of the State Archaeologist, University of Iowa, Iowa City.
1988 Burial Project 294. On file, Office of the State Archaeologist, University of Iowa, Iowa City.
1995 Burial Project 879. On file, Office of the State Archaeologist, University of Iowa, Iowa City.
2018 Burial Project 3368. On file, Office of the State Archaeologist, University of Iowa, Iowa City.

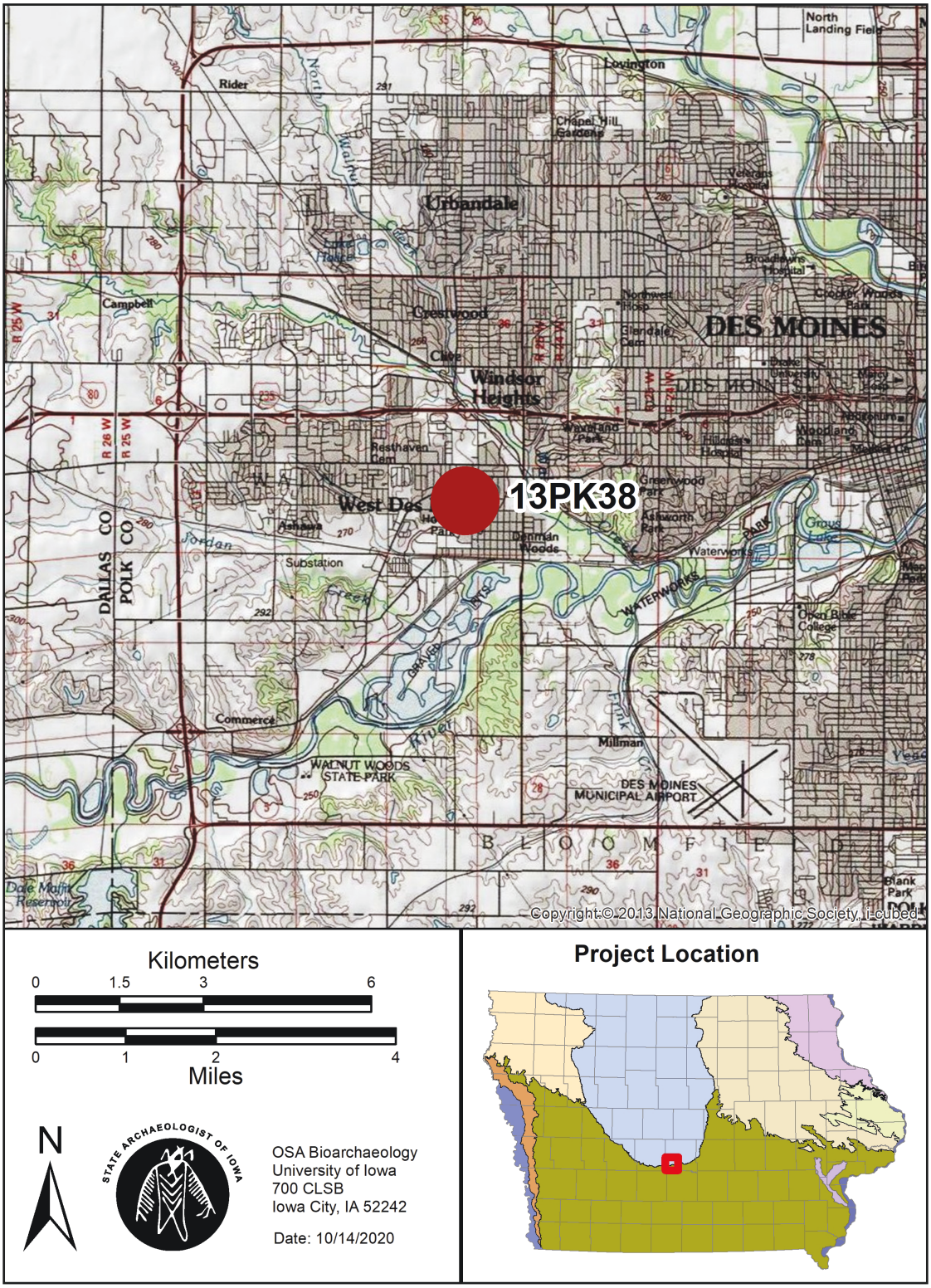

Figure 1. Location of 13PK38.
From USGS Des Moines SW, Polk County, Iowa (1976), 7.5' series quadrangle map. Scale 1:100,000.

Commingled Human Remains Recovered from a Flood-damaged Mill Creek Village (13PM7) in Plymouth County, Iowa

Jennifer E. Mack and Lara Noldner

Flooding during the spring of 2019 caused multiple levee breaches in the vicinity of a known Mill Creek village site, 13PM7. Floodwater scouring exposed a mortuary feature and spread skeletal elements across an area measuring approximately 20,000 square meters. Human remains recovered during multiple site visits and limited excavations (2019–2021) represent a minimum of six individuals, including a child 7.5 to 11.5 years old, an older adolescent or younger adult, a middle to old adult, and three adults of unknown age. Sex could not be determined with certainty, but two individuals were possibly male. A naturally-shed deciduous tooth represents a seventh individual, a 10 to 12 year old child who lived at the site.

Project Background

In the spring of 2019, record-breaking flooding on the Big Sioux River resulted in three breaches in the earthen levees to the north and west of a known Mill Creek village site, 13PM7 (Figure 1). When floodwaters receded and the area was inspected by the farm manager, thousands of artifacts were found to be strewn across the landscape, covering an area measuring approximately 30,000 square meters. Because human remains were also found scattered on the surface (in an area measuring approximately 20,000 square meters), the land manager reported the finds to the archaeologist at the Sanford Museum in Cherokee, Iowa, Megan Messerole. On June 21, in coordination with the Office of the State Archaeologist (OSA), Messerole conducted a field visit and surface collection, during which she encountered a concentration of human skeletal elements presumed to be the remnant of a mortuary feature. OSA Bioarchaeology Program Director Lara Noldner conducted a second site visit on July 26, and recovered additional human remains from the surface of the site. The OSA received an emergency grant from the Historic Resources Development Program (HRDP) of the State Historical Society of Iowa for ten days of fieldwork, August 19–28, to secure any additional human remains, evaluate damage to the site, and assess the potential for intact archaeological deposits (UI, OSA 2019).

During the HRDP funded fieldwork, no remnant of the initially reported mortuary feature, later designated Feature 88, was detected. However, soil probe testing of several remnant pit features revealed bone fragments suspected to be human in Feature 21. Because there were no plans to repair the levee and the following spring's floods would potentially impact the feature, 100% recovery of this feature was conducted October 29–30, 2019, by Noldner and OSA archaeologist, Dustin Clarke, with the approval of the Three Affiliated Tribes, the Mandan, Hidatsa and Arikara.

Another episode of surface collection and salvage excavation of the site was conducted by a crew of professional archaeologists and trained volunteers from November 8–10, 2019. Only two human elements (teeth) were recovered during this session.

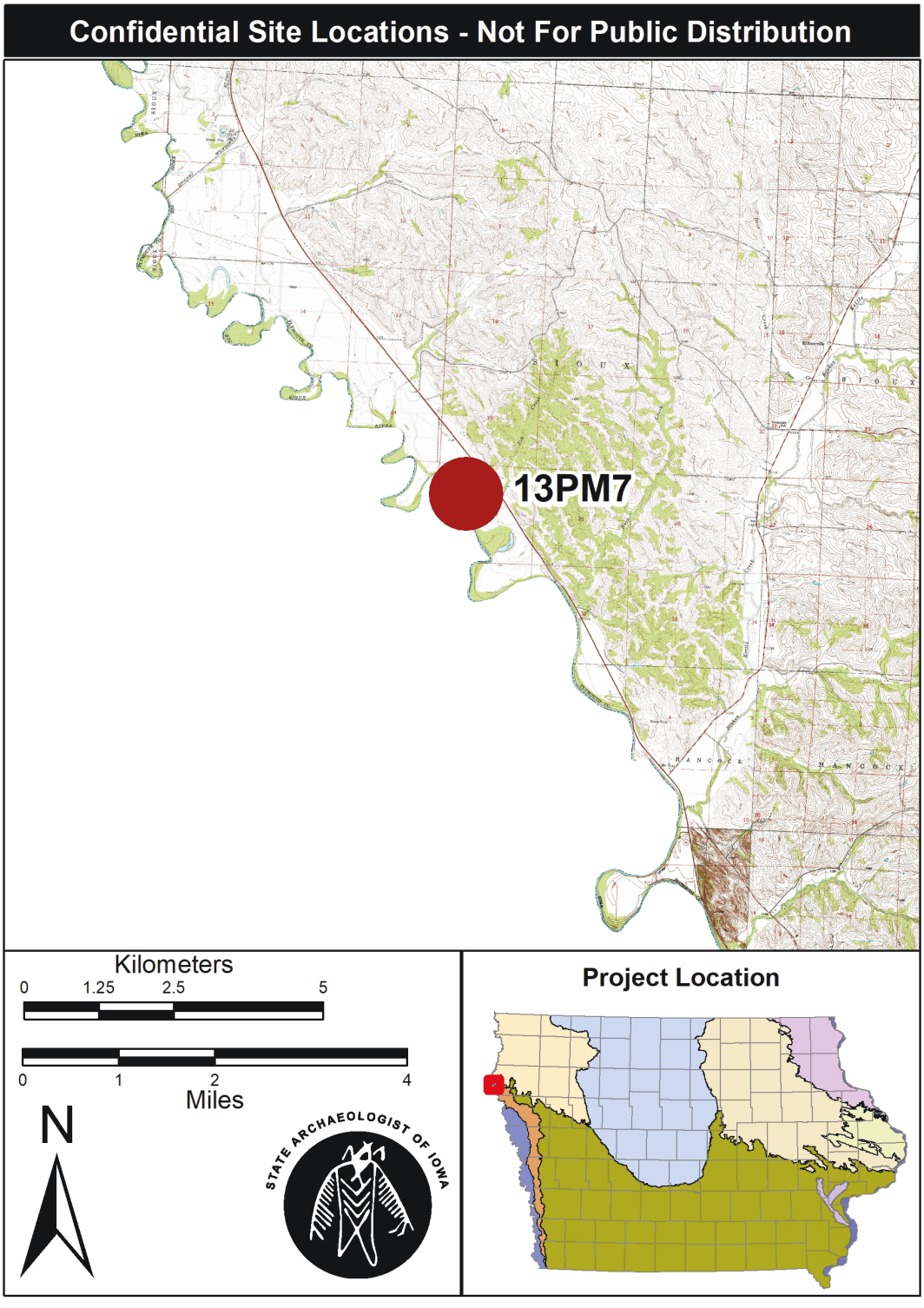

Figure 1. Location of the Joy Creek Major site, 13PM7.
From USGS Elk Point NE, Plymouth County, Iowa (1976), 7.5' series quadrangle map. Scale 1:100,000.

On April 11, 2021, human remains were again reported on the surface of the site, likely exposed due to a combination of factors including the planting and harvesting of corn in 2020 and snow melt and spring rains in 2021. On April 13, the new archaeologist of the Sanford Museum, Quinn Black, collected the reported remains, which were found at the same location as the previously recorded mortuary feature (Feature 88). On April 22, OSA Bioarchaeology Program staff returned to the site to perform intensive surface survey and skim-shoveling in an attempt to determine the location of the mortuary feature. Numerous human skeletal elements and fragments were recovered, but the feature was not identified.

On May 7, OSA staff conducted a limited field excavation to determine the location of the mortuary feature. Two test pits (TU 1 and 2) were excavated at the location of the original 2019 discovery of human remains, but no trace of the mortuary feature was found. A few fragments of human bone were found within the top 3 cm of TU 2.

A full report of the initial fieldwork and site evaluation, including osteological analysis, was published as part of the OSA's Technical Report series (Hawkins et al. 2020). At the time of the current publication, the OSA is awaiting grant funding for the production of a report detailing the November 2019 and May 2021 fieldwork.

Site Background

Site 13PM7, also known as the Joy Creek Major site, was first recorded in 1965 by avocational archaeologists who reported that the habitation site, which originally appeared as a circular midden mound, had been substantially leveled during the construction of a levee along the Big Sioux River to the west of the site. The midden deposits were estimated to be 2.4 m in depth, with the uppermost 1.2 m removed for the flood control project several years before the site was reported. Materials collected from 13PM7 at this time, as well as later collections by private citizens, Luther College, and the OSA, are consistent with those of other Mill Creek villages nearby, such as Broken Kettle (13PM1) and the Kimball Site (13PM4) (Bettis and Thompson 1982:18-20). The site is associated with the Big Sioux phase (A.D. 1100–1250) of Mill Creek occupation (Alex and Peterson 2010; Peterson and Schroeder 2014).

Mortuary Context

Human skeletal remains recovered from 13PM7 include 406 whole elements and fragments, 189 from 2019 fieldwork episodes and 217 from 2021. The majority of elements and larger fragments were found in the surface concentration interpreted in 2019 as a flood-damaged mortuary feature (F. 88) located approximately 30 m north of the original site boundary (Figure 2) or in the immediate vicinity. In 2019, this feature consisted of an oval-shaped, moderately dense surface scatter of human remains measuring approximately one meter by two meters. Two pieces of fire-cracked rock, a few ceramic sherds, shell fragments, two small faunal bones, and approximately 15 fragments of large mammal bones (including one bison metapodial) were also observed in this feature. All surface materials were collected in 2019. At that time, no additional artifacts or soil changes were visible below the collected materials. Evidence from artifact distributions, aerial photography, and fracture refitting across the site suggest that many of the human bone fragments recovered to the southeast of this location were displaced from the mortuary feature by floodwaters.

Human remains observed on the surface in April 2021 covered an area measuring approximately 9.5 m northwest–southeast and 3.75 m northeast–southwest, centered on the mortuary feature mapped in 2019. In the field, refits were observed between fragments in the central portion of the scatter and skeletal elements on the periphery, so all human remains were collected as part of the original F. 88. A concentration of human remains 4.25 m to the southeast of the center of F. 88 contained portions of femur, tibia, and fibula, all with

evidence of recent, severe fragmentation. This damage was likely due to heavy machinery moving over the area. Faunal remains, ceramic, shell, and fire-cracked rock were also observed on the surface, intermixed with the human remains.

An extensive gradiometer survey undertaken at 13PM7 in 2020 revealed features interpreted as fortification ditches and bastions (Kvamme 2020). The coordinates of the center point of F. 88 appear to fall close to or within the fortification ditch south of Bastion 1 (Figure 3). The elongated surface scatter observed in 2021 was oriented on the same long axis as that of the fortification ditch, running northwest (322°). It was noted in the field that this elongated orientation did not match that of the agricultural rows, and therefore was not likely related to the movement of farm machinery.

Non-Mortuary Contexts

FEATURE 21

Soil probing of F. 21 (Survey Block F) during the HRDP project in August 2019 recovered six small human bone fragments, so this feature was targeted for emergency salvage excavation. When initially identified and probed, the surface expression of F. 21 was an oval-shaped scatter of fire-cracked rock, faunal bone, ceramics, and shell measuring 1.1 m north-south and 1.2 m east-west. Due to additional flooding in late August/September, much of the surface scatter was redistributed and spread out so that only a few fragments of fire-cracked rock remained at the original location in October when the feature was salvaged. All artifacts on the ground surface within a 1.8 m by 1.9 m area around the feature were counted and recorded; none were collected. The area was then shovel-skimmed to define the feature's boundaries. After skimming approximately two centimeters of soil, the circular outline of the pit feature became apparent. The feature boundary was identifiable as an intermittent outline of yellowish-brown sediment (10YR5/4) which measured 1.0 m north-south and 0.87 m east-west. A line of five 11-cm diameter post holes was also noted immediately southeast of F. 21 (Figure 4).

The feature was bisected, and the southeast quarter was dug first in 10 cm levels; artifacts and animal bones encountered were counted and recorded, but not collected (see Table 1 for artifact counts). The remainder of the feature contents were bagged for flotation; the southwest quarter was collected first, and a profile was drawn of the bisected feature before the northern half was also collected. The maximum depth of the feature was 29 cm, and the bottom of the pit was basin shaped. The feature fill was lightly mottled grayish, dark brown (10YR3/1).

During excavation of each quadrant of the feature, all bones and bone fragments were inspected to identify any additional human remains that required collection. Seven recovered rib fragments were determined to be human. All were found within a concentration of large animal bones at the feature's center, primarily in Level 1 (0–10 cmbs). The concentration of bone measured a maximum of 23 cm deep and 51 cm wide. In addition to the human bone, only a wolf molar, a large piece of possible ochre, and a fine bone awl were collected. Faunal bones, fire-cracked rock, ceramic sherds, broken shell, charcoal, ochre, and a chert scraper were observed but not collected. No additional human remains were recovered, so this pit was not considered a mortuary feature.

FEATURE 23

During salvage excavations in November 2019, a deciduous human tooth was collected from the surface of F. 23. However, this tooth had a completely resorbed root, indicating the crown was shed naturally by a child. This feature consisted primarily of an articulated bison ribcage with charcoal, shell, and lithics. No additional human remains were found in F. 23, so it is not considered a mortuary feature. The center point of this feature falls within one of the fortification ditches identified by the gradiometer survey (Figure 3).



Figure 2. Distribution of human remains at 13PM7 after flooding in 2019.
Site map showing updated site boundary, mortuary feature, Feature 21, and surface findspots.

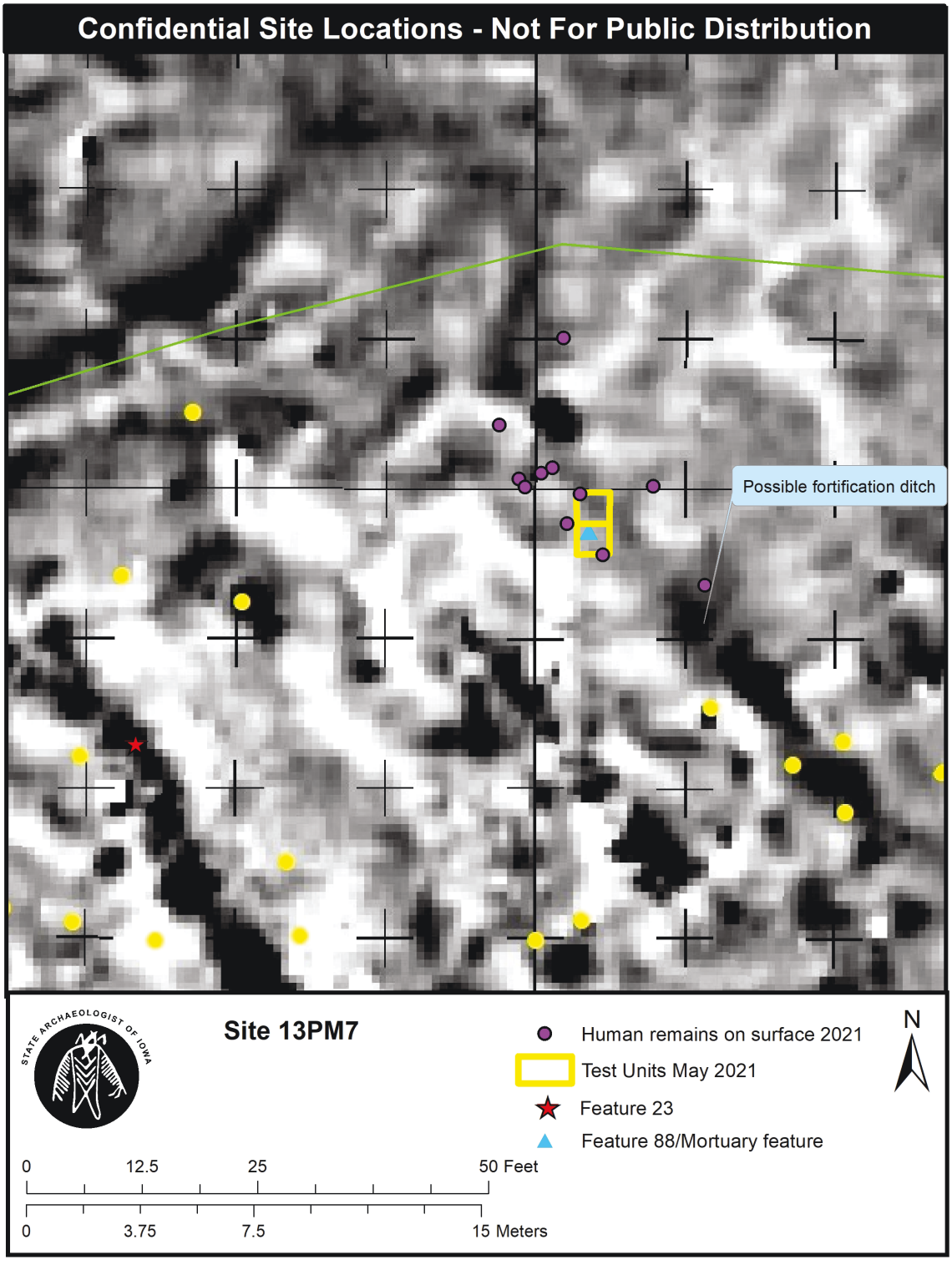

Figure 3. Gradiometer survey results shown in relation to Feature 88 (as observed in 2019) and the surface scatter of human remains collected in April 2021. Test units excavated in May 2021 also shown.

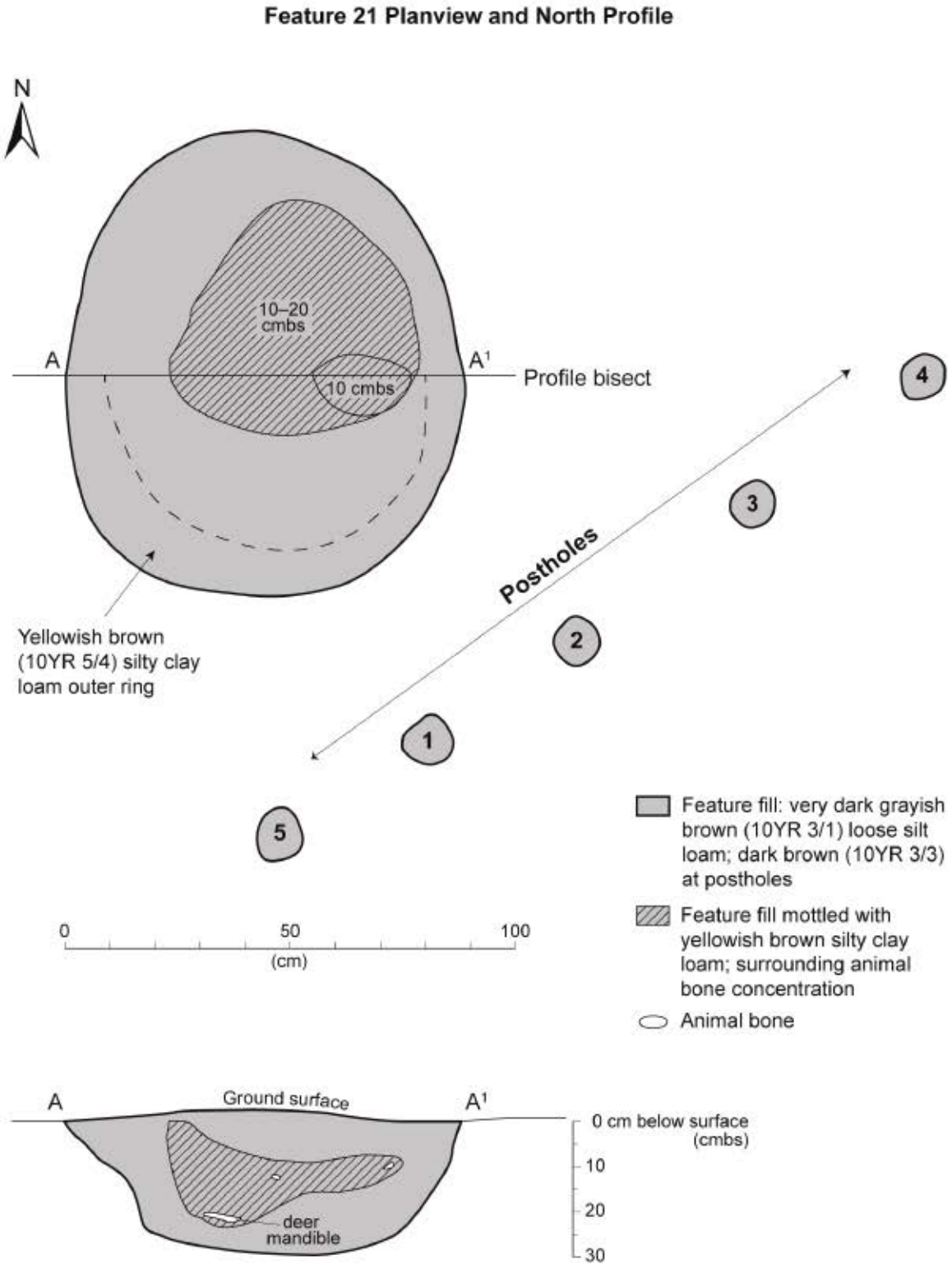

Figure 4. Planview and profile drawings of Feature 21, 13PM7. The five nearby postholes are also shown.

Table 1. Artifact and Faunal Bone Counts for Feature 21, 13PM7, Joy Creek Major - Surface and SE 1/4

Provenience	Potsherds	FCR	Lithics	Faunal Bones	Shell fragments	ochre
Surface - over entire feature						
Surface	53 (2 rim sherds)	28	1 (scraper)	47	24	0
SE 1/4						
0-10 cm	19	1	0	42	0	4
10-20 cm	5	0	0	18	10	0
20-29 cm	3	0	0	3	3	0

SURFACE SCATTER

The remainder of the human bone fragments (n=25) encountered during fieldwork sessions were found on the surface to the southeast of F. 88. Fragments that refit with elements from the feature were found up to 185 m away, indicating that fast-moving floodwaters transported human remains substantial distances when the levee failed. It is possible that all or most of the scattered remains originated from F. 88 and/or Feature 21.

Osteological Analysis

MORTUARY FEATURE (FEATURE 88)

Reconstructed cranial remains and dental remains from the mortuary feature represent three distinct individuals, designated Individuals 1, 2, and 4. The minimum number of individuals (MNI) represented in this feature, however, is five, based on the identification of three bilateral pairs of adult femora and a fourth, robust right femoral shaft, as well as a subadult tooth. Cranial and postcranial remains which could not be assigned to a specific "individual" are discussed in the Commingled Remains section below. Individual 3 is described in the section below entitled Human Remains Out of Context.

Individual 1

The remains designated Individual 1 consist of a fragmented, incomplete frontal, occipital, and both parietals. The left parietal was found with the other remains in the mortuary feature, while the right parietal was found 185 m southeast of the feature, in the flood washout area. All observable sutures are completely open ectocranially, with minimal closure on the endocranial surface, suggesting this individual was a young adult or adolescent. Most sexually dimorphic features of the cranium are unobservable, but the lack of prominent features at the nuchal crest and glabella suggests the individual was possibly female. Microporosity observed on the superior half of the occipital squama and the posteromedial corners of both parietals may represent healed porotic hyperostosis.

Individual 2

This individual consists primarily of refitting occipital, parietal, and temporal (left and right) fragments from the mortuary feature. Additional refitting cranial fragments were recovered at some distance from this feature. Fragments of frontal and left parietal were collected from the ground surface approximately 17 m east of the feature, while fragments of right frontal and right parietal were found 74 m and 60 m to the southeast, respectively.

Sex cannot be determined with certainty from the portion of the cranium present, though the mastoids are large, and the nuchal crest is moderately pronounced, suggesting the individual was possibly male. Age is also unknown. However, complete obliteration of all observable portions of the coronal suture and significant closure of the lambdoidal suture both suggest that this individual was a middle or old adult.

The only pathology observed takes the form of remodeled (well-healed) labyrinthine endocranial lesions on the right parietal and frontal. Under normal lighting conditions, these areas appear simply to be marked with deep vessel impressions; oblique lighting reveals traces of the former labyrinth-like network of smaller vessels. The fragments that bear these lesion remnants exhibit thick diploë. The cause of the lesions was likely a meningeal reaction, such as an epidural hematoma or meningitis (Ortner 2003:93-96).

Individual 4

The single tooth that represents Individual 4 was found on the ground surface to the north of the main mortuary feature concentration on April 22, 2021. The tooth is an unerupted maxillary left premolar, likely a first premolar. The root is ¼ complete, indicating an age of 7.5 to 10.5 years if a first premolar or 7.5 to 11.5 years if a second premolar. The total age range is for this individual is 7.5 to 11.5 years.

The Individual 4 tooth is unlikely to have originated from the same individual as the naturally shed deciduous mandibular second molar found in F. 23 (described below). The premolar root would exhibit a later stage of development if the tooth's eruption had caused the loss of a deciduous second molar.

Commingled Remains

Inventory

The commingled cranial and postcranial remains collected from the mortuary feature are listed in Table 2, with long bone measurements presented in Table 3. All regions of the skeleton are represented, and the minimum number of individuals is four, based on the presence of three bilateral pairs of complete and partial femora (Left and Right Femur 1, Femur 2, and Femur 3) and an unmatched section of robust right femoral shaft. One bilateral pair each of tibiae and os coxae were also identified. Though it is not possible to articulate any of the cranial remains with the postcranial elements, there is also no evidence that would eliminate the possibility that the postcranial remains belong with the crania designated Individuals 1 and 2 (or Individual 3, below). Right Femur 1 exhibits a remnant line of fusion on the head, and the iliac crest and ischial tuberosity are not quite fused on the bilateral pair of os coxae, suggesting a young adult or older adolescent individual. This age is consistent with the open sutures of the cranium of Individual 1. However, the size of the femur and the morphology of the os coxae both indicate a male, while the cranium was separately determined to be possibly female. As this determination of sex was based on only two cranial features, it is possible that the cranium actually belonged to a male.

Dental remains collected from the vicinity of Feature 88 in 2021 cannot be confidently associated with the crania designated Individuals 1, 2, and 3. The portion of right maxilla recovered has the lateral incisor, canine, and first premolar in situ. The right half of a mandible has seven teeth, the lateral incisor through the third molar. No evidence of antemortem tooth loss or caries is present. Slight calculus was observed on teeth from both arcades. Both sets of teeth exhibit moderate dentin exposure on the anterior teeth, while the posterior teeth of the mandible are only slightly worn. The maxilla is too incomplete to confidently occlude with the mandible or to exclude occlusion. Based on the slight to moderate dental wear, these teeth likely represent an adolescent or young adult individual, consistent with Individual 1. For full dental inventory and dental metrics, see Tables 4 and 5.

Pathology

Several elements exhibit pathological alterations. The left humeral fragment displays remodeling at the proximal shaft, resulting in loss of definition of the intertubercular groove and the crest of the lesser tubercle. Root etching obscures the area, but no pathological bone is apparent. The crest of the greater tubercle is exaggerated, forming a sharp, irregular ridge projecting anteriorly. This crest is the insertion site for pectoralis major, so the bone changes may be related to habitual activity or injury. A left distal radius fragment displays well-remodeled periosteal bone apposition on the posterior surface of the interosseous crest, extending past the defined portion of crest, down the distal ¼ of the shaft. The affected area measures 50 mm in length, with a maximum transverse width of 6 mm. The refitting proximal portion recovered from the same area in 2021 exhibits a small amount of sclerotic periosteal new bone formation on the anterior surface of the shaft, lateral to the interosseus crest.

A bilateral pair of femora (Left and Right Femur 1) both exhibit well-remodeled periosteal bone apposition on the proximal half of the diaphysis. On the left femur, the bone apposition is circumferential, with microporosity visible on the posterior surface distal and medial to the lesser trochanter. There is increased width at the gluteal tuberosity. A second nutrient foramen located on the distal third of shaft, with periosteal new bone extending distally along the linea aspera to the supracondylar lines. Large spicules of vertically oriented bone are present medial to the lesser trochanter, inferior to the neck, and may not be related to periosteal reaction, as they are mirrored on the right femur. The right femur displays patches of microporosity and heavily striated bone present on medial and anterior surfaces of the proximal shaft. A very small patch (measuring 35 mm superoinferiorly) of woven bone is present on the anterior surface of the distal end of the shaft.

Evidence of degenerative joint disease is present in the form of slight lipping on the articular margins of a right trapezium, right hamate, and left second metacarpal. In two instances, a distal foot phalanx is fused to the middle phalanx.

Taphonomy

A few ribs were found together, and a cluster of three leg bones (two femora, one tibia) was found within the mortuary feature. Other than those associations, the commingled nature of the remains suggests the individuals were already disarticulated when deposited in the feature. Chop marks on several elements provide further evidence of disarticulation. Three transversely-oriented chop marks are located on the distal third of the lateral shaft surface of Right Humerus 2. Approximately 15 mm distal to the distal-most chop mark, immediately proximal to the lateral supracondylar ridge, a missing 20 mm long splinter of bone may have been removed by the chopping, though rodent gnaw marks are present in this area as well. Rodent gnawing was also found near the proximal end of the shaft (as well as elements found out of context, see below). Uniform bone coloration indicates the rodent activity was not recent.

A portion of left humeral shaft displays at least nine chop marks on the medial surface of the proximal third of the shaft. All of the marks have parallel orientation, transverse but slightly diagonal, superomedial to inferolateral. The length of the shaft bearing the chop marks measures approximately 50 mm. The refitting distal shaft fragment was recovered in 2021. At the location of the transverse fracture which separated the two shaft portions, there is a round defect measuring 4 mm superoinferiorly and 5.5 mm transversely. This defect penetrates the cortex and extends into the medullary cavity. The shape of the defect appears too irregular to be a canine puncture. The coloring of the fracture edges on both refitting fragments indicates this is not recent breakage. The defect may be a percussion pit resulting from intentional breakage. A similar defect was noted on a left ulna, the proximal portion of which was recovered from the vicinity of Feature 88 (distal portion found 172 m southeast of the feature). The transverse shaft fracture separating the two sections is not recent. On the lateral edge of the anterior surface of the shaft at the location of the fracture, there is a small postmortem defect that appears to be an impact spall from a strike with an implement. The

defect, which measures 5 mm x 4.2 mm, does not penetrate into the medullary cavity. Neither the humerus nor the ulna exhibits evidence of anvil abrasion on the opposite shaft surface.

Two large and eight smaller chop marks were observed on the anteromedial surface distal to the neck of Left Femur 3. All marks are oriented transversely, with the largest closest to the neck and the smallest 47 mm distal to the largest chop mark. The coloring of the bone within all the chop marks described indicates ancient rather than recent damage. The right femoral shaft section recovered in 2021 exhibits some recent breakage, but the fracture edges at the proximal and distal ends of this shaft portion exhibit uniform coloring indicating old breaks. Damage to the proximal end, on and medial to linea aspera, created stepped fractures and spalling of the cortical bone and is suggestive of intentional postmortem breakage through percussion. Rectilinear sections of cortical bone have been broken away on the lateral surface of the proximal shaft fracture edge.

Together, the evidence of disarticulation, intentional breakage, and rodent gnawing suggests postmortem processing and periods of exposure before the human remains were deposited in Feature 88.

FEATURE 21

The remains recovered from a one-inch soil core taken from F. 21 in August 2021 include six very small bone fragments, each measuring 15 mm in diameter or less. These unidentified fragments were determined to be potentially human based on texture and cortical density, as well as the presence of distinct flecks of red ochre in the soil adhering to the bone fragments. Two of the recovered fragments may be vertebral.

Salvage excavation of F. 21 in October 2019 recovered seven human rib fragments. Because they were intermingled with a large concentration of animal bone, this feature was considered a non-mortuary pit feature. Most of the rib fragments are too fragmentary to identify by side and number. Two larger fragments are from ribs 5–10 but are unsideable; both represent an adult individual. No pathologies are evident on these fragments.

FEATURE 23

Only one human element was recovered from this non-mortuary pit feature, a deciduous human tooth found on the surface during fieldwork in November 2019. The deciduous left mandibular second molar crown has rounded cusps, and the root is completely resorbed, indicating that the tooth was shed naturally. Deciduous mandibular second molars are usually lost between the ages of 10 and 12 years. The discovery of this tooth does not increase the MNI buried at the site, but rather represents a child who lived at 13PM7.

HUMAN REMAINS OUT OF CONTEXT

Individual 3

Individual 3 is represented solely by a fragment of right parietal that includes a portion of the temporal suture which is duplicated in the remains of Individuals 1 and 2. The parietal fragment was found on the ground surface approximately 24 m south of the mortuary feature. Another right parietal fragment was found approximately 44 m east of the Individual 3 fragment. The two fragments are consistent in thickness and coloring but are not refitting portions so association could not be determined.

The fragment representing Individual 3 is thin in cross-section for an adult (approximately 3.5 mm), but the observable sections of cranial suture are closed or closing endocranially, indicating the individual was not a juvenile, despite the gracility of the parietal. Sex and age cannot be determined, and no pathology was observed.

Scattered Remains

Commingled human remains recovered from the ground surface to the south and east of the mortuary feature (F. 88) are listed in Table 2. These remains include cranial fragments, teeth, and portions of upper and lower limb bones. Two loose teeth, a maxillary left second incisor and a mandibular left second molar, exhibit little wear, suggesting they represent a young adult. An occipital fragment bears a portion of the superior nuchal line which is duplicated in Individuals 1 and 2. This fragment appears too thick to be consistent with the cranial remains of Individual 3, and thus could represent a fourth individual, though the lack of association with Individual 3 cannot be stated with certainty.

Only one of the scattered elements displays pathological bone. A portion of left ulnar shaft recovered from the washout area has a small amount of well-healed periosteal bone apposition on the anterior and posterior surfaces of the distal portion of the interosseous crest. Markedly irregular bone is present along a 24 mm long section just distal to the end of the interosseous crest.

Extensive rodent gnawing appears on two recovered fragments, a portion of fibula shaft (unsided) and the distal half of a left humerus. The gnaw marks do not appear to be recent.

REFITS AND ARTICULATING UNITS

Identified refitting bone fragments associated flood-scattered remains with remains found in Feature 88 in 2019. Bone fragments collected from the surface in the vicinity of F. 88 in 2021 also refit with remains collected in 2019 from the feature and the flood scatter.

As discussed above, the left parietal of Individual 1 was found in F. 88, while the right parietal was found 185 m southeast of the feature, in the flood washout area. Refitting fragments of frontal and left parietal of Individual 2 (F. 88) were collected from the ground surface approximately 17 m east of the feature, while fragments of right frontal and right parietal were found 74 m and 60 m to the southeast, respectively.

A portion of left proximal humeral shaft recovered from F. 88 in 2019 refits with a distal shaft fragment found in the vicinity of the feature in 2021. A proximal radius found in the vicinity of F. 88 in 2021 refits with a distal radius fragment found in the feature in 2019. A proximal ulna found in the vicinity of F. 88 refits with an ulna shaft fragment recovered from the flood scatter area in 2019. The left second metacarpal shaft collected from the vicinity of F. 88 during the OSA field visit on April 22, 2021, refits with the metacarpal head collected from an unknown location on April 13, 2021. The proximal portion of Left Femur 3 was found within F. 88, while the refitting distal shaft portion was found 173 m southeast of the feature. The fractures that divided these elements are old, based on the coloring of the broken edges.

Two potentially articulating sets of elements were identified among the commingled remains. A portion of right maxillary alveolus found in the flood scatter area to the southeast of F. 88 holds teeth which occlude well with the dentition of a right mandibular arcade. The dental inventory and metrics of Articulating Unit 1 are presented in Tables 6 and 7. Based on dental wear and dentin exposure, these teeth represent a middle or old adult. Unfortunately, the mandible was collected by the landowner, so its location was not recorded.

The left ulna with periosteal bone apposition along the interosseous crest is consistent in size, morphology, and pathology with the left radius fragment recovered from F. 88; this was designated Articulating Unit 2.

Summary

Human remains were recovered from the flood-damaged site of 13PM7 during four field visits/surface collections, a site evaluation project, targeted salvage of a pit feature, a general site salvage excavation, and excavation of two test pits, all taking place between 2019 and 2021. The collected remains represent a minimum of six individuals deposited at the site, including a child 7.5 to 11.5 years old, an older adolescent or young adult male, a middle to old adult (possible male), and three adults of unknown age and sex.

Most remains (MNI=5) were recovered from the remnants of a damaged mortuary feature (Feature 88) and its immediate vicinity. Though disturbance of the feature could have caused some movement of the remains, the lack of articulations observed in the feature and the presence of chop marks and rodent gnawing strongly suggest that the individuals were disarticulated prior to deposition in the feature. Human remains recovered from the ground surface to the south and east of the site were clearly moved by floodwaters. Based on refits and articulating units identified between the feature and the scattered remains, it is likely that most or all of the surface finds originated from the flooded feature. Scant skeletal material recovered from the intact fill of Feature 21 likely represents a sixth individual. A naturally-shed deciduous tooth found in Feature 23 represents a seventh individual, a 10 to 12 year old child who lived at the site.

References Cited

Bettis, Arthur E., III, and Dean M. Thompson
1982 *Interrelations of Cultural and Fluvial Deposits in Northwest Iowa.* Archaeology Laboratory, University of South Dakota, Vermillion. Copy on file, Office of the State Archaeologist, University of Iowa, Iowa City.

Hawkins, Alan J., Jennifer E. Mack, and Lara K. Noldner
2020 *Emergency Assessment and Salvage of Ancient Human Remains Exposed at 13PM7, Plymouth County, Iowa,* Technical Report 1205, Office of the State Archaeologist.

Ortner, Donald J.
2003 *Identification of Pathological Conditions in Human Skeletal Remains.* Academic Press, New York.

Peterson, Cynthia L., Lynn M. Alex, and William E. Whittaker
2010 *Kimball Village (a.k.a. Site 13PM4; Kimball Village Site; Kimball Site; Kimball Mound)*. National Register of Historic Places Registration Form. Office of the State Archaeologist, University of Iowa, Iowa City. Submitted to Office of Historic Preservation, State Historical Society of Iowa, Des Moines. Copy on file, Office of the State Archaeologist, University of Iowa, Iowa City.

Peterson, Cynthia L., and Maria F. Schroeder
2014 *Phase IA Cultural Resources Reconnaissance of the Big Sioux River Water Trail Corridor through Lyon, Plymouth, Sioux, and Woodbury Counties, Iowa and Lincoln and Union Counties, South Dakota*. Contract Completion Report 2069. Office of the State Archaeologist, University of Iowa, Iowa City.

University of Iowa, Office of the State Archaeologist (UI, OSA)
2019 Burial Project 3443. On file, Office of the State Archaeologist, University of Iowa, Iowa City.

Table 2. Adult Commingled Remains, 13PM7, Joy Creek Major

Element	Number of Fragments/ Specimens	MNE Left	MNE Right	MNE Midline	MNE Unsided
Commingled remains from mortuary feature					
Cranium/mandible	11		2		
Maxillary teeth	3		3		
Mandibular teeth	7		7		
Hyoid	1			1	
Cervical vertebra 2 (axis)	1			1	
Cervical vertebrae (3-7)	2			1	
Thoracic vertebrae	20			10	
Lumbar vertebrae	4			1	
Vertebrae indeterminate	6				
Sacrum	7			1	
Ribs 2-12	32	4	3		
Clavicle	1				1
Scapula	5	1	1		
Humerus	6	1	2		
Radius	3	1			
Ulna	4	1	1		
Carpals	4	2	2		
Metacarpals	4	1	1		
Hand phalanges	5				5
Os coxa	12	1	2		
Femur	17	3	4		
Patella	1	1			
Tibia	20	1	2		
Fibula	18	1	1		
Tarsals	2	2			
Metatarsals	5		2		1
Foot phalanges	4				4
Long bone fragments	30				
Indeterminate fragments	53				
Commingled remains from Feature 21					
Ribs 2-12	7				1
Indeterminate fragments	6				
Human remains from Feature 23					
Mandibular tooth	1	1			
Commingled remains recovered from washout area					
Cranium/mandible	6			2	
Maxillary teeth	4	1	3		
Mandibular teeth	6	2	4		
Humerus	1	1			
Ulna	1	1			
Patella	1		1		
Fibula	3				2
Long bone fragments	1				

Table 3. Postcranial Metrics (mm), commingled remains, 13PM7

Element	Measurement	Left	Right
Femur 1	Max length		495
	Bicondylar length		490
	Max diameter-head		52
	A-P subtrochanteric diam	31	31
	Med-Lat subtrochanteric diam	39	35
	A-P diameter midshaft	31	29
	Med-Lat diameter midshaft	28	29
	Midshaft circumference	95	93
Femur 2	A-P subtrochanteric diam		28
	Med-Lat subtrochanteric diam		38
	A-P diameter midshaft		29
	Med-Lat diameter midshaft		26
	Midshaft circumference		87
Femur 3	A-P subtrochanteric diam	28	
	Med-Lat subtrochanteric diam	34	
Tibia 1	Length		364
	Max prox epiph breadth		75
	Max distal epiph breadth		50
	Max diam nutrient foramen		37
	Med-Lat diam nutrient foramen		21
	Circumference-nutrient foramen		93

Table 4. Dental Inventory, F. 88 maxilla and mandible, 13PM7, 2021

Tooth	Presence	Attrition:	Attrition- molars:			
		I, C, P	Mes-buc	Mes-ling	Dis-ling	Dis-buc
MAXILLA:						
RP1	2	2				
RC	2	4				
RI2	2	3				
RI1	5	9				
MANDIBLE:						
RM3	2		3	3	4	4
RM2	2		4	3	4	4
RM1	2		4	3	4	4
RP2	2	2				
RP1	2	3				
RC	2	4				
RI2	2	5				
RI1	9	9				

Dental Inventory Key:

Presence

1 Present but not in occlusion
2 Present, development completed, in occlusion
3 Missing, with no associated alveolar bone
4 Missing, with alveolus resorbing or fully resorbed: antemortem loss
5 Missing, with no alveolar resorption: postmortem loss
6 Missing, congenital absence
7 Present, damage renders measurements impossible
8 Present but unobservable (e.g. teeth in crypts)
9 Unobservable

Attrition (I, C, PM)

1 Unworn or small facets
2 Point or hairline of dentin
3 Dentin line of distinct thickness
4 Moderate dentin exposure, not resembling a line
5 Large dentin area with rim complete (two areas on premolars)
6 Large dentin area with enamel rim lost on one side (two areas coalesced on premolars)
7 Enamel rim lost on two sides (at least one side lost on premolars)
8 Complete loss of crown, no enamel remaining
9 Unobservable

Attrition (molars)

0 Unobservable
1 Wear facets invisible or very small
2 Wear facets large, but cusps and surface features still evident
3 Any cusp in quadrant is rounded, but not flat
4 Quadrant is worn flat, but no dentin is exposed (except pinprick-sized)
5 Quadrant is flat, dentin exposed on ¼ of quadrant
6 More than ¼ of dentin is exposed, with enamel ring still complete
7 Enamel is found on only two sides of quadrant
8 Enamel on only one side of quadrant, but enamel is still thick
9 Enamel on only one side of quadrant and it is very thin
10 No enamel remaining. Wear extends below the cervicoenamel junction onto the root

Table 5. Dental Metrics (mm), F. 88 maxilla and mandible, 13PM7, 2021

Tooth	Mesiodistal	Buccolingual	CEJ mesiodistal	CEJ buccolingual
MAXILLA:				
RP1	6.8	8.3	4.8	7.5
RC		8.0	5.3	7.3
RI2		6.4	5.3	6.1
MANDIBLE:				
RM3	11.7	10.5	10.5	9.1
RM2	12.0	10.8	9.4	9.0
RM1	11.5	11.1	9.7	10.0
RP2		8.3	5.3	7.1
RP1	5.7	7.2		7.0
RC			5.0	6.7
RI2			4.1	5.5

Table 6. Dental Inventory, Articulating Unit 1, 13PM7

Tooth	Presence	Attrition:	Attrition- molars:			
		I, C, P	Mes-buc	Mes-ling	Dis-ling	Dis-buc
MAXILLA:						
RM3	3					
RM2	3					
RM1	2		6	7	7	6
RP2	2	6				
RP1	2	6				
RC	5					
RI2	5					
RI1	5					
MANDIBLE:						
RM3	4					
RM2	2		6	5	5	6
RM1	2		6	5	5	6
RP2	2	3				
RP1	2	3				
RC	5					
RI2	5					
RI1	9					

Table 7. Dental Metrics (mm), Articulating Unit 1, 13PM7

Tooth	Mesiodistal	Buccolingual	CEJ mesiodistal	CEJ buccolingual
MAXILLA:				
RM1			7.3	11.1
RP2			4.7	7.7
RP1			5.0	8.5
MANDIBLE:				
RM2			8.7	8.7
RM1			8.7	9.5
RP2			4.8	7.5
RP1			4.7	6.8

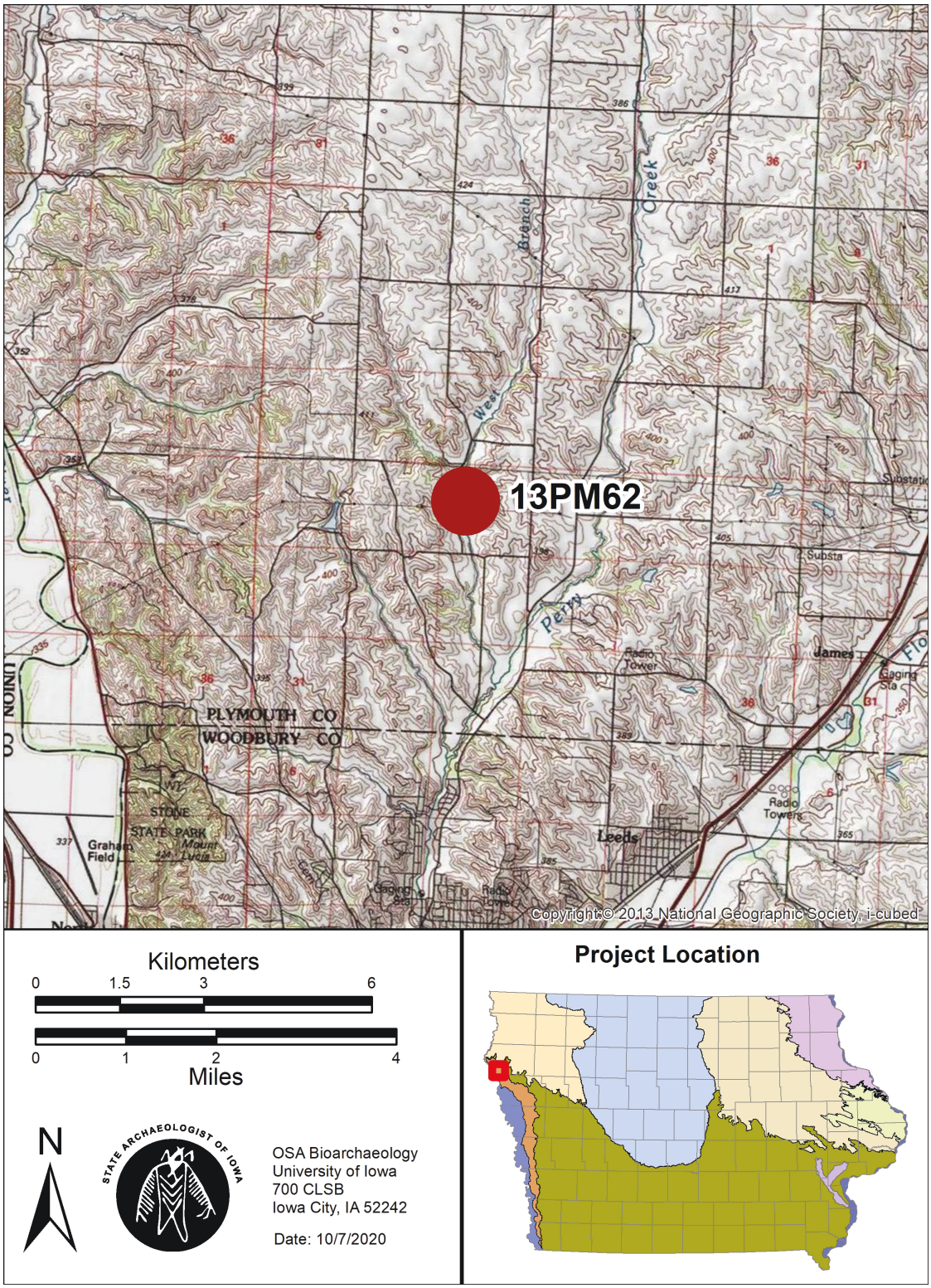

Figure 1. Location of 13PM62, a Great Oasis village site.
From USGS Sioux City North, Plymouth County, Iowa (1994), 7.5' series quadrangle map. Scale 1:100,000.

A Human Molar Recovered from 13PM62, a Great Oasis Village in Plymouth County, Iowa

Jennifer E. Mack

A single human tooth was recovered from 13PM62 during excavations in 1974. Based on dental wear, the individual represented by the tooth was a juvenile or very young adult.

The Great Oasis culture village site known as the Lawrence Vondrak Site (13PM62) was excavated in 1974 as a joint venture of the Department of Anthropology, University of Nebraska-Lincoln, and the National Park Service. During this excavation, only eight bone fragments were recovered. A single tooth found in a general excavation level (Square 5.4 SW 7.4, Level 7, 60-70 cm) was the only human element in the assemblage (Henning 1996). Subsequent to excavation, the materials were reposed by the US Army Corps of Engineers (USACE), Omaha District. In 2018, when the USACE collection was moved to the repository of the University of Iowa, Office of the State Archaeologist (OSA), the human remains were separated for analysis by the Bioarchaeology Program in anticipation of repatriation (UI, OSA 2018).

The human tooth, like the other bone fragments from 13PM62, is in poor condition. Postmortem erosion typical of burials in the Loess Hills region has left the crown chalky and pitted, and most of the root has either been broken or eroded away. The tooth is identified as a mandibular left first molar, though the morphology would be normal for a second molar as well. The distal 1/4-1/3 of the crown appears to have been destroyed by a carious lesion, though the cavity has been enlarged by postmortem damage. The level of dental wear on the buccal cusps is somewhat obscured by postmortem pitting. However, it appears the molar experienced little wear, with small to medium facets and no dentin exposure. If the tooth is correctly identified as a first molar, the lack of dental attrition indicates the represented individual was likely a juvenile. If the tooth is a second molar, the slight wear would be consistent with an older juvenile or very young adult individual from a prehistoric Native American site. It is unknown whether the tooth was extracted/lost during life or represents an individual who died during the active use of the village.

References Cited

Henning, Dale R.
1996 The Archeology of Two Great Oasis Sites in the Perry Creek Valley, Northwest Iowa. *Journal of the Iowa Archeological Society* 43:7–118.

University of Iowa, Office of the State Archaeologist (UI, OSA)
2018 Burial Project 3331. On file, Office of the State Archaeologist, University of Iowa, Iowa City.

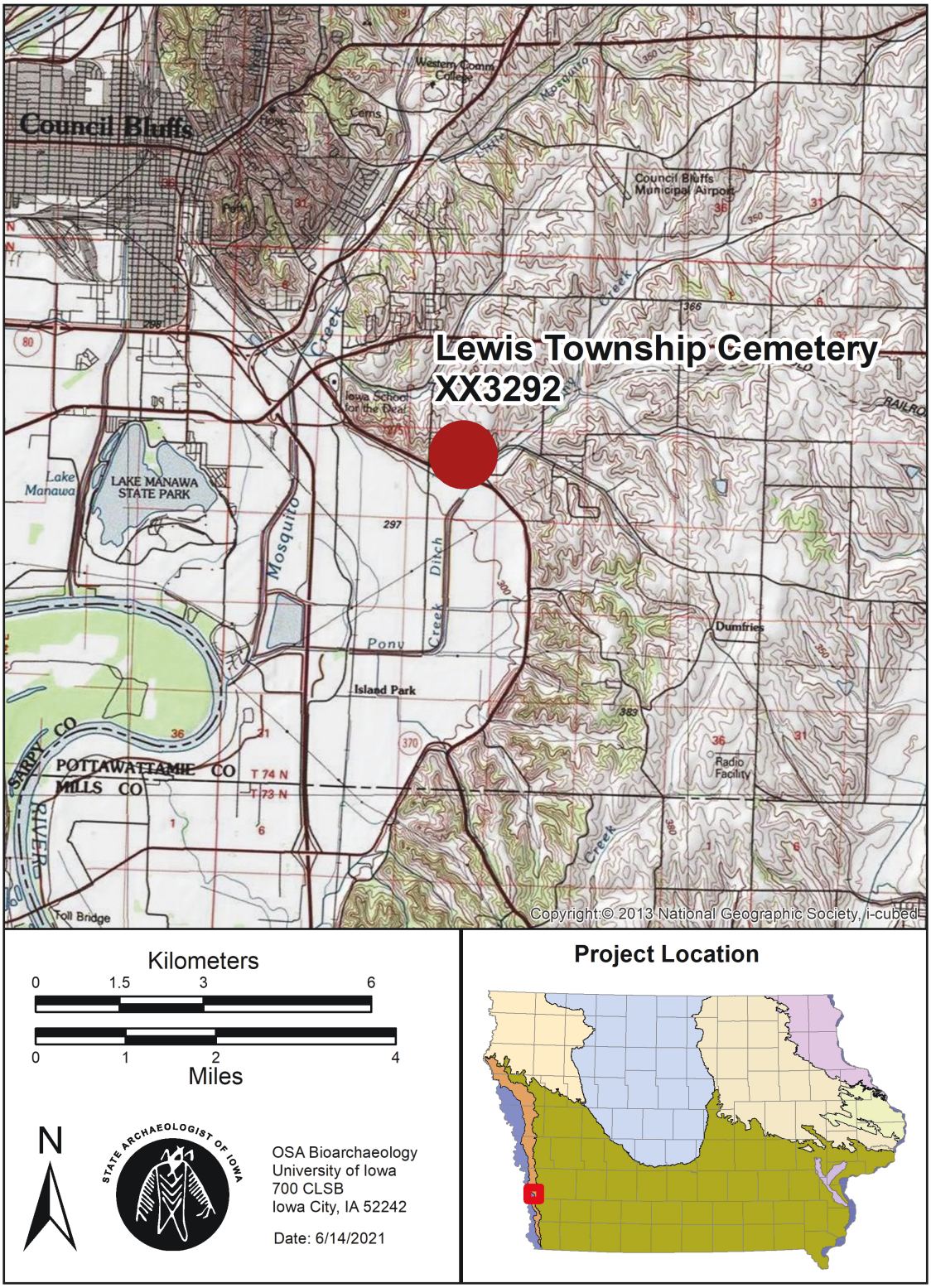

Figure 1. Lewis Township Cemetery, OSA Notable Location XX3292.
From USGS Council Bluffs South, Pottawattamie County, Iowa (1994), 7.5' series quadrangle map. Scale 1:100,000.

Human Skeletal Remains Disturbed in Lewis Township Cemetery, Pottawattamie County, Iowa

Jennifer E. Mack

Partial skeletal remains recovered from a back-dirt pile at Lewis Township Cemetery, Pottawattamie County, represent a probable old adult male. The condition of the remains and coffin materials recovered from the dirt pile suggest the individual was interred between 1900 and 1960. Less than 20% of the skeleton was found, indicating that the rest of the elements are still in situ in the unmarked grave or mixed in the soil used to backfill the grave shaft of a recent interment.

Introduction

On May 17, 2021, a private citizen reported to the Pottawattamie County Sheriff's Office that he had discovered a human mandible eroding out of a back-dirt pile at Lewis Township Cemetery (Figure 1; OSA Notable Location XX3292). The mandible was collected by law enforcement and the area was inspected for additional exposed remains. Crime scene investigator Hadley Mikovec consulted with Dr. Heather Garvin-Elling, a forensic anthropologist contracted through the Office of the State Medical Examiner, who advised that the remains were too old to be of medicolegal significance and suggested that Pottawattamie County contact the Office of the State Archaeologist Bioarchaeology Program (OSA-BP) about recovery and analysis of any additional human remains disturbed at the site. Lewis Township Cemetery was founded in 1889, and thus the graves technically fall outside the range of the OSA-BP's statutory responsibility, which includes individuals who died 150 years ago or more. However, staff of the OSA-BP often assist with exposures of human remains that fall in the gray area between forensic and ancient. OSA-BP Director Lara Noldner and bioarchaeologist Jennifer Mack travelled to Pottawattamie County to recover human remains on May 26 and 27, 2021 (UI, OSA 2021).

The Lewis Township cemetery superintendent indicated which dirt piles originated from the most recently excavated five graves. With the help of Pottawattamie County staff, including Hadley Mikovec, Chief Death Investigator Cheri Dahlheim, and two sheriff's deputies, OSA-BP staff screened soil from the grave shaft backfill piles through ¼-inch galvanized hardware cloth. Pieces of coffin wood, nails, screws, hinges, part of a possible shoe heel, and additional human remains were recovered from this soil.

Osteological Analysis

Relatively few elements and bone fragments were recovered from the backfill soil piles. Recovered remains include a portion of the cranial vault, complete edentulous mandible, right half of atlas, complete axis, additional cervical vertebra fragment, complete right ulna, nearly complete right radius, right carpals (capitate, lunate, trapezium), the base of the right first metacarpal, complete right second and third metacarpals, two metacarpal shafts, three small rib fragments, and a fragment of ilium possibly from the right side.

All of the skeletal remains appear consistent with a single adult in terms of condition, coloring, size, and morphology. There is no duplication of elements to suggest a second individual. Several elements, including the mandible, radius, ulna, and ilium fragment have purple staining attributed to fungal colonization (Piepenbrink 1986). Less than 20% of the skeleton was recovered. With the exception of small, unsidable fragments, all recovered elements originate from the right side and centerline of the upper body, suggesting that the newly dug grave intruded on only a portion of an existing older grave. Parts of the cranium, torso, left arm, pelvis, and/or legs may still be in situ in the grave, and disturbed elements from these body portions may be present in the soil used to backfill the recent burial.

The sex of this individual is possibly male, based on gonial eversion and a square chin. The lack of a prominent mental eminence appears due to bone resorption associated with extensive tooth loss. The physiological length of the ulna (estimated at 245 mm) is consistent with that of males in the OSA-BP comparative collection, and the robust nature of the carpals and metacarpals appears to support the identification of the individual as male.

Age is estimated as old adult (>50 years) based on the completely edentulous mandible. Degenerative lipping seen on joint surfaces indicates that this individual was an old adult or that he did strenuous work, or both. Slight to moderate degenerative lipping is present on a number of elements, including the superior and inferior right articular processes of the atlas (slight), the superior processes of the axis (slight), the inferior articular processes of the axis (moderate), the head of the radius (slight), the trochlear and radial notches of the ulna (moderate), the articular surfaces of the trapezium and lunate (slight), and the proximal articular surface of the third metacarpal. Additionally, an irregular ridge of enthesophytes developed along the entire posterior margin of the radial tuberosity, indicating habitual stress on the distal biceps brachii.

Non-human Materials

Recovered coffin-related artifacts include coffin wood (numerous pieces), nails (n=13), screws (n=7), tacks (n=3), and portions of two sets of hinges. The nails range from large common nails (3 in, 10-penny) to small finishing nails (1 ¼ in, 3-penny). The presence of wire nails, rather than machine cut nails with rectangular cross-sections, indicates this individual was buried after 1900 (Mainfort and Davidson 2006:115-120). The choice of a wooden coffin, and the near complete disintegration of that coffin in the period since interment, suggests the individual was likely buried prior to the rise in popularity of sheet-metal caskets in the mid-twentieth century. A piece of black rubber also recovered from the soil may be part of a shoe heel.

Pieces of medium diameter tree roots were found in the soil with the artifacts and human remains. Given the lack of trees and large bushes within the cemetery, the presence of roots in the associated soil suggests that the disturbed grave was likely located close to the tree line along the perimeter fence. The cemetery superintendent indicated that one of the recent burials occurred near the eastern boundary of the property. It is likely that the recent interment of this individual intruded on an unmarked grave offset slightly to the north and east of her grave shaft.

Summary

The partial skeletal remains of an older adult, probable male, were recovered from a backdirt pile on the property of Lewis Township Cemetery, Pottawattamie County, Iowa. A forensic anthropologist and OSA-BP bioarchaeologists concurred that the condition and context of the remains indicate they are not of medicolegal interest. The coffin and nail types suggest the individual was buried in the cemetery between 1900 and 1960. Less than 20% of the skeleton was recovered, and no distinguishing features were noted aside from the antemortem loss of all mandibular teeth. The only pathology noted was mild degenerative joint disease on several elements and enthesopathy of the radial tuberosity of the right arm. The individual cannot be identified based on these characteristics. Some of the missing portions of the skeleton are likely still in situ in the unmarked grave, and other elements may be mixed in the soil used to backfill the intruding burial in August 2020. All remains recovered from the backdirt pile were returned to the overseer of the cemetery and reburied in the cemetery's potter's field on December 21, 2021.

References Cited

Mainfort, Robert C., Jr. and James M. Davidson, eds.
2006 *Two Historic Cemeteries in Crawford County, Arkansas*. Arkansas Archeological Survey Research Series No. 62. Fayetteville, Arkansas.

Piepenbrink, Hermann
1986 Two Examples of Biogenous Dead Bone Decomposition and Their Consequences for Taphonomic Interpretation. *Journal of Archaeological Science* 13:417-430.

University of Iowa, Office of the State Archaeologist (UI, OSA)
2021 Burial Project 3591. On file, Office of the State Archaeologist, University of Iowa, Iowa City.

Human Cranium Discovered During Road Construction near Fairview Cemetery, Council Bluffs, Pottawattamie County, Iowa

Jennifer E. Mack

A human cranium discovered in disturbed soil during road construction near the western boundary of Fairview Cemetery in Council Bluffs, Pottawattamie County, Iowa, represents an individual approximately 14 to 20 years old. Cranial morphology and metrics suggest European ancestry. The condition of the remains and the context of discovery suggest the cranium originated from a grave in the cemetery, likely post-dating the addition of the westernmost portion of the burial ground, which occurred after 1875.

Background

On November 6, 2020, the Pottawattamie Sheriff's Office was notified of the discovery of a human skull in a soil pile at a road construction site. This construction site was located where Oakland Drive becomes Lafayette Avenue and cuts across the slope leading up to Fairview Cemetery (Figure 1). Marked graves are present at the top of the slope approximately 20–30 feet (6–9 m) east of the road, at an elevation of approximately 10–15 feet (3–5 m) above the current roadbed. The original location of the cranium is unknown, as the soil in the pile had been moved multiple times. Chief Death Investigator Cheri Dahlheim and other officers searched the disturbed soil for additional remains, and searched the slope for evidence of a grave, but found none. After a determination that the remains were not of medicolegal significance, the cranium was transferred to the Office of the State Archaeologist Bioarchaeology Program (OSA-BP) on May 26, 2021.

According to a city website (Council Bluffs 2021), the oldest known burial at the site occurred in 1826, and the burial ground was formally designated Fairview Cemetery in 1846. However, the western portion of the burial ground close to the cranium findspot was not added to the cemetery property until sometime between 1875 and 1885, based on historic maps (Figures 2 and 3; Allen 1885; Andreas 1875). This approximate addition date is consistent with earliest legible death dates—1883 and 1886—found on grave markers along the western boundary of the cemetery. It is likely, then, that the human remains discovered during construction technically fall outside the range of the OSA-BP's statutory responsibility, which includes individuals who died 150 years ago or more. Without associated artifacts, though, a precise date of burial cannot be determined (UI, OSA 2021). Given the location of the cemetery relative to the slope and the Christian tradition of interment with the head to the west, it is possible that only the skull of this individual was disturbed and that the rest of the skeleton remains in situ in the original burial location.

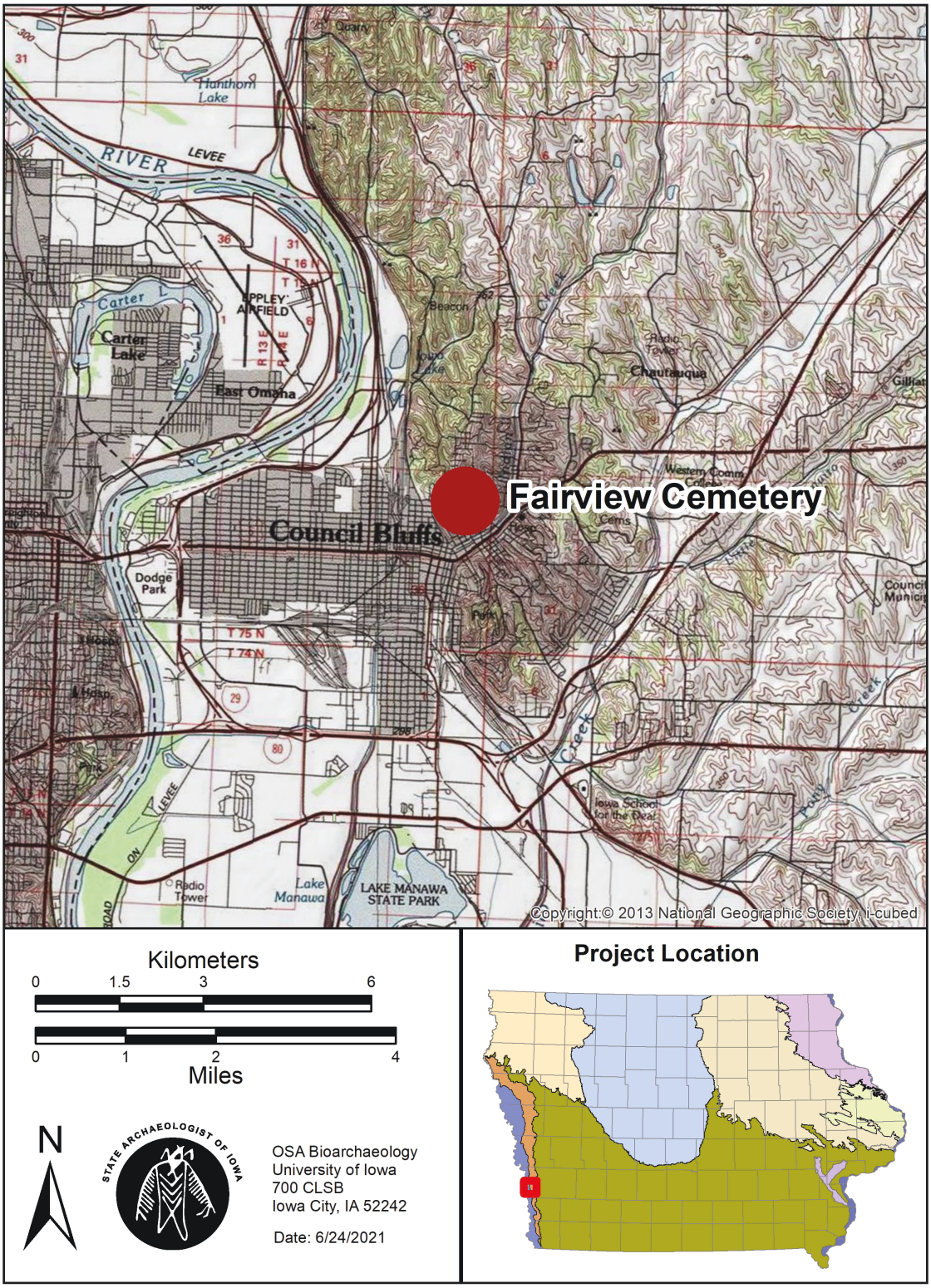

Figure 1. Location of Fairview Cemetery, Council Bluffs, Pottawattamie County, Iowa. From USGS Council Bluffs North, Pottawattamie County, Iowa (1994), 7.5' series quadrangle map. Scale 1:100,000.

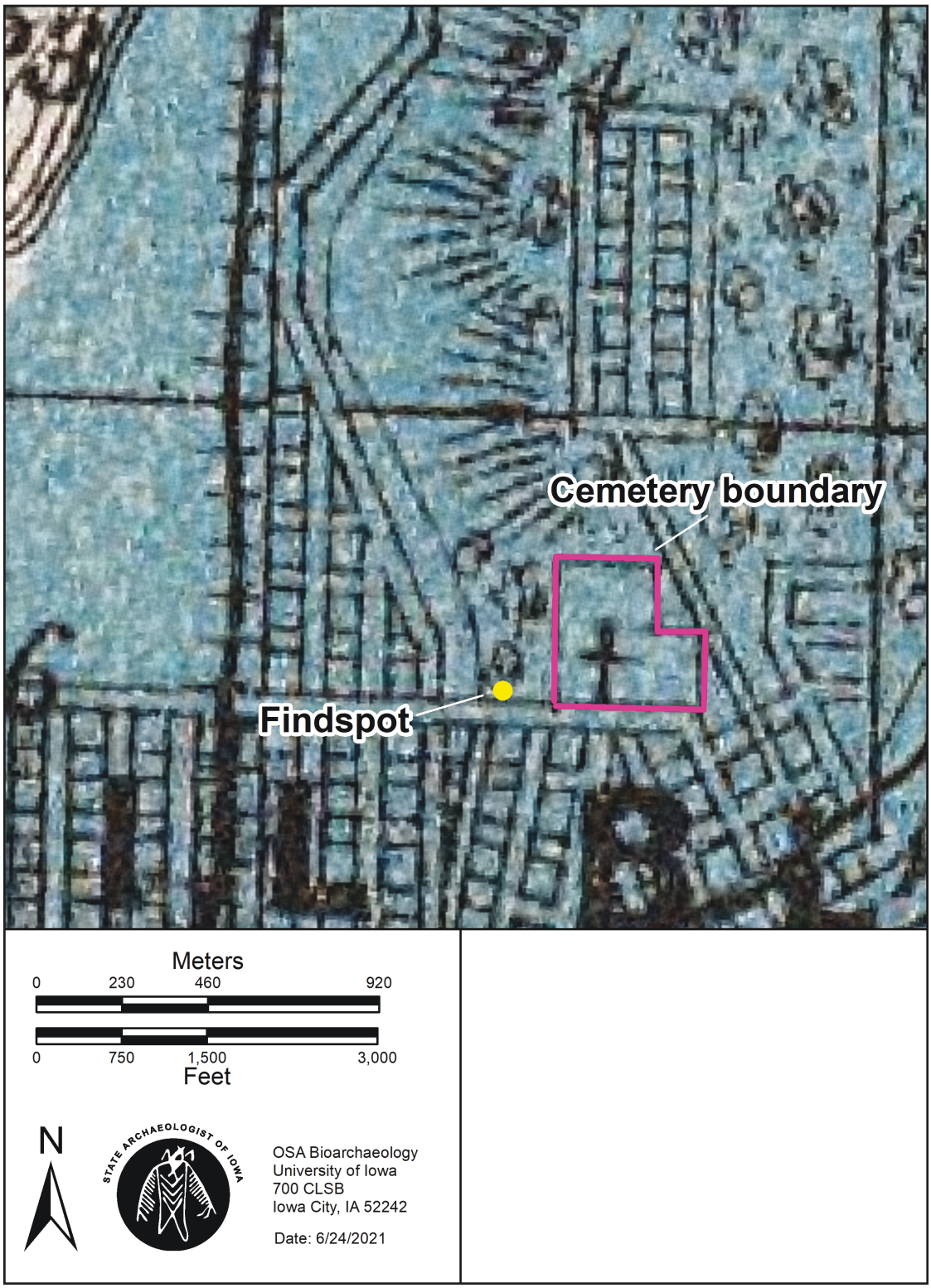

Figure 2. Findspot of human cranium near Fairview Cemetery, shown in relation to cemetery boundary in 1875 (Andreas 1875).

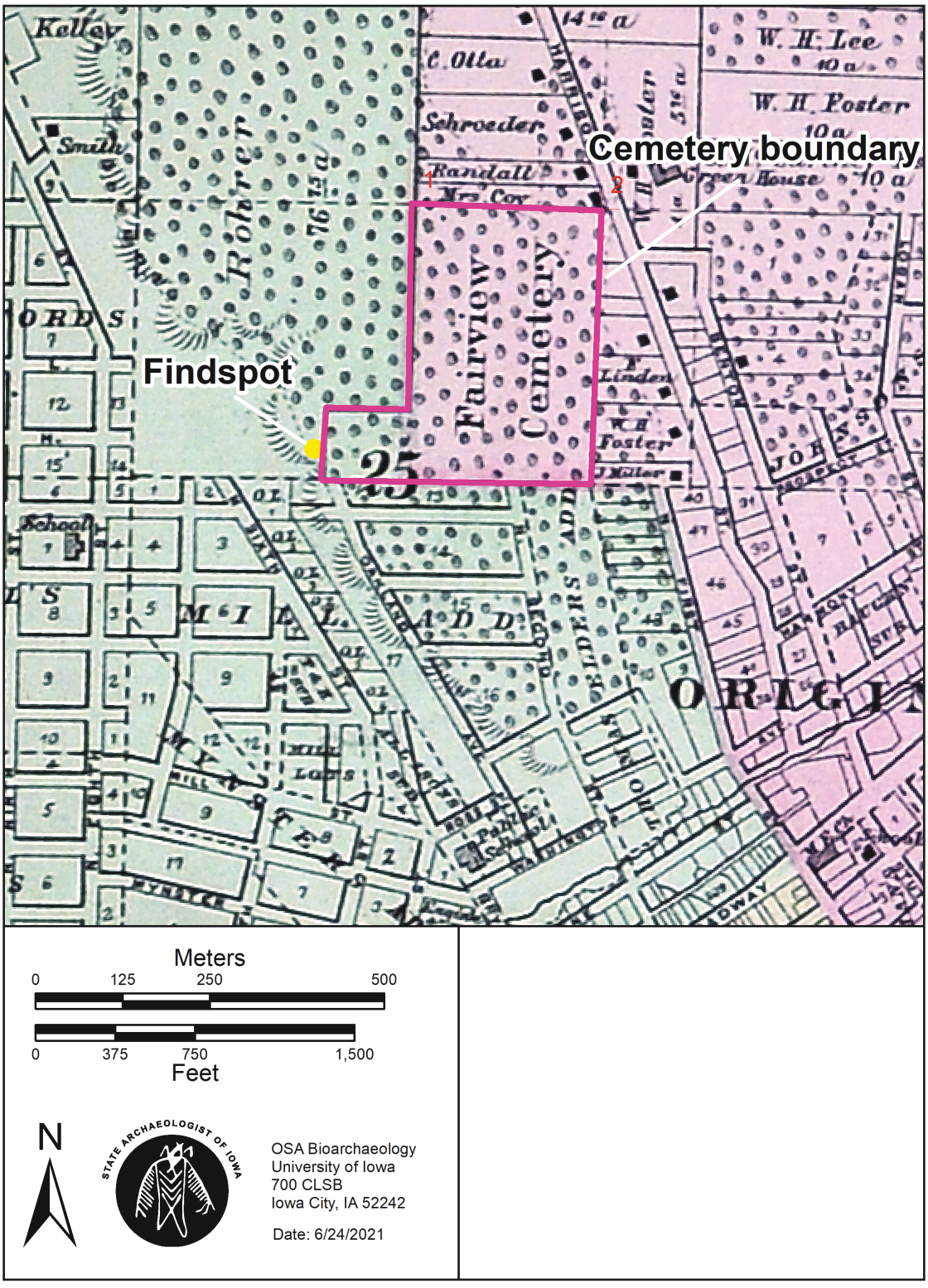

Figure 3. Findspot of human cranium near Fairview Cemetery, shown in relation to cemetery boundary in 1885 (Allen 1885).

Osteological Analysis

The remains consist of a partially intact cranium, the left side of which is almost complete. The right parietal is present but has separated from the cranial vault along open sutures. The missing portions of the cranium are the right maxilla, zygomatic, and temporal; the right half of the occipital squama; the lambdoidal suture of the right parietal; and the mandible. The frontal exhibits excellent preservation of the ectocranial and endocranial surfaces, with little soil staining as compared to the parietals and occipital. The remaining center portion of the occipital and the distal right parietal exhibit both cortical surface flaking and general degradation of the bone, with a chalky texture, as well as postmortem damage. Weathering subsequent to disturbance and exposure could be a possible cause of this differential preservation. However, given the context of the remains, it seems more likely that the cranium was resting in the grave slightly tilted to the right, resulting in a pooling of decomposition fluids and groundwater on the posterior right portion of the cranium, which hastened degradation of the bone. This weakened part of the skull would then have been more vulnerable to breakage when the skull was disturbed and moved around by heavy machinery.

Sexually dimorphic features of the skull suggest the individual was female, but this assessment is unreliable due to the individual's young age. The small mastoid processes, sharp orbital margins, and smooth glabella could simply indicate that the individual had not yet begun pubertal changes. Age cannot be determined precisely. All cranial sutures are open ectocranially with no closure, or very minimal closure endocranially, suggesting the individual was a child or adolescent (<20 years). The spheno-occipital synchondrosis is fused, a development which occurs between ages 11 and 16 years for females, and between 13 and 18 for males. The jugular growth plate is still open, but the timing of this fusion varies significantly. Dental development was difficult to assess due to antemortem pathology, postmortem damage, and a possible congenital abnormality. The apices of the roots of the left maxillary canine and left maxillary first molar are closed, indicating the individual was probably older than 14 years. Based on suture closure and dental development, age is estimated to be 14 to 20 years.

Ancestry was primarily evaluated based on morphological features of the cranium. The individual does not have projecting zygomatics and is not prognathic. Observable features suggesting European ancestry include a narrow nasal root, high nasal bridge, sharp nasal sill, prominent nasal spine (though broken postmortem), and narrow nasal aperture (apparent despite breakage on margins). The context of the discovery and the condition of the bone also point to a historic period Euroamerican burial, rather than ancient Native American remains. Though FORDISC is not generally recommended for analysis of individuals under the age of 18 years, the metrics for this adolescent cranium (Table 1) were entered into the program and compared with those of White and Native American males and females in the Forensic Databank. The individual was found to be closest to White females, with a cross-validation rate of 71.5% and posterior probability of 0.939. All typicality probabilities were 0.746 and above. Comparison was attempted with Howells' data as well, but the low cross-validation rates (60%) indicated that the low number of measurements was not suitable for this analysis.

The dental remains consist of the left arcade of the maxilla only (Tables 2 and 3). Of the eight teeth that should be present, three—the central and lateral incisors and the first premolar—were lost postmortem. The canine is present, complete, and observable. The second premolar, which was originally believed to be in the process of erupting, was revealed through cleaning to have been snapped off postmortem, with only a portion of root remaining in the socket. The crown of the first molar was almost completely destroyed by caries. The second molar is absent and changes to the alveolar socket suggest the tooth was lost due to an abscess. The alveolar bone is resorbed significantly at this location, at least 5 mm superior to the alveolar crests on the rest of the maxillary arcade. The second molar socket is not entirely resorbed, as two root impressions are still visible.

The location of the third molar on the alveolus displays unusual morphology. The bone is not smooth, as would be expected from a fully resorbed loss or congenital absence of the tooth. Some irregular bone formation is present, but there is no remnant of resorbing root sockets. The location exhibits the same degree of alveolar recession as the resorbing second molar socket. The lingual half of the location has dense bone texture that mirrors that of the maxillary palate, while the buccal half exhibits more porous bone. On the distal margin, an abnormal enamel formation was observed. The enamel of this hollow formation is thin and fragile and has the pinkish cast seen in unerupted tooth crowns. The rounded, cusp-like formation measures 3.7 mm mesiodistally and 4.7 mm buccolingually, with a height of approximately 3 mm. The formation does not appear to have a root and seems to be anchored to the alveolus. One possible explanation is that this enamel formation was hidden in the normal alveolus of an individual who seemed to have a congenitally absent third molar; the enamel was only exposed due to infection-related bone loss caused by the second molar abscess. Alternatively, the severe infection from the second molar may have disrupted development of the third molar. However, a literature search found no examples of this kind of disruption. It is possible that the pus pocket from the second molar abscess expanded and caused the loss of the still-forming third molar, leaving behind a cusp that had not yet coalesced. Unfortunately, the absence of a true third molar prevents narrower age estimate.

Aside from the dental pathology described above, no pathological bone was observed on the remains.

Summary

The partially intact cranium recovered from the road construction site just west of Fairview Cemetery in Council Bluff represents an individual between the ages of 14 and 20 years. Cranial morphology and metrics suggest the individual was a female of European ancestry, though these results are not definitive, as FORDISC was not developed for use with the skeletal remains of subadults. This individual exhibited poor dental health, with severe caries and at least one molar lost antemortem. Based on the proximity of the findspot to the boundary of a later addition to the cemetery, this individual was likely buried after 1875. The overseer of Fairview Cemetery was contacted regarding the return of the cranium for reburial in the cemetery, but indicated that she preferred the individual remain reposed at the OSA.

References Cited

Allen, C. R. (compiler)
1885 *Illustrated Atlas of Pottawattamie County, Iowa*. C. R. Allen, Council Bluffs, Iowa.

Andreas, Alfred T.
1875 *Illustrated Historical Atlas of the State of Iowa*. State Historical Society of Iowa, Iowa City.

Council Bluffs
2021 Cemetery page. Council Bluffs, Iowa webpage. Electronic document, https://www.councilbluffs-ia.gov/262/Cemeteries, accessed June 10, 2021.

Iowa State University Geographic Information Systems Support and Research Facility (ISUGISSRF)
2021 Iowa Geographic Map Server. Iowa State University Geographic Information Systems Support and Research Facility, Ames, Iowa. Electronic document, ortho.gis.iastate.edu, accessed April 13, 2021.

University of Iowa, Office of the State Archaeologist (UI, OSA)
2021 Burial Project 3596. On file, Office of the State Archaeologist, University of Iowa, Iowa City.

Table 1. Cranial Metrics (mm), Burial Project 3596

Cranial metric	
Basion-bregma height	128
Cranial base length	96
Minimum frontal breadth	97
Upper facial breadth	98
Nasal height	48
Orbital breadth L	40
Orbital height L	35
Interorbital breadth	18
Frontal chord	104
Foramen magnum length	34
Foramen magnum breadth	30

Table 2. Dental Inventory, Burial Project 3596

Tooth	Presence	Attrition:	Attrition- molars:			
		I, C, P	Mes-buc	Mes-ling	Dis-ling	Dis-buc
MAXILLA:						
LM3	1?					
LM2	4					
LM1	7		0	0	0	0
LP2	7	9				
LP1	5					
LC	2	2				
LI2	5					
LI1	5					

Dental Inventory Key:
Presence
1 Present but not in occlusion
2 Present, development completed, in occlusion
3 Missing, with no associated alveolar bone
4 Missing, with alveolus resorbing or fully resorbed: antemortem loss
5 Missing, with no alveolar resorption: postmortem loss
6 Missing, congenital absence
7 Present, damage renders measurements impossible
8 Present but unobservable (e.g. teeth in crypts)
9 Unobservable
Attrition (I, C, PM)
1 Unworn or small facets
2 Point or hairline of dentin
3 Dentin line of distinct thickness
4 Moderate dentin exposure, not resembling a line
5 Large dentin area with rim complete (two areas on premolars)
6 Large dentin area with enamel rim lost on one side (two areas coalesced on premolars)
7 Enamel rim lost on two sides (at least one side lost on premolars)
8 Complete loss of crown, no enamel remaining
9 Unobservable
Attrition (molars)
0 Unobservable

Table 3. Dental Pathologies, Burial Project 3596

Tooth	Calculus:		Caries:		Abscess:
	Presence	Location	Number	Type	Type
MAXILLA:					
LM3					infection spread from M2?
LM2					buccal perforation
LM1	small amount	buccal and lingual	1	large	
LC	small amount	interproximal			

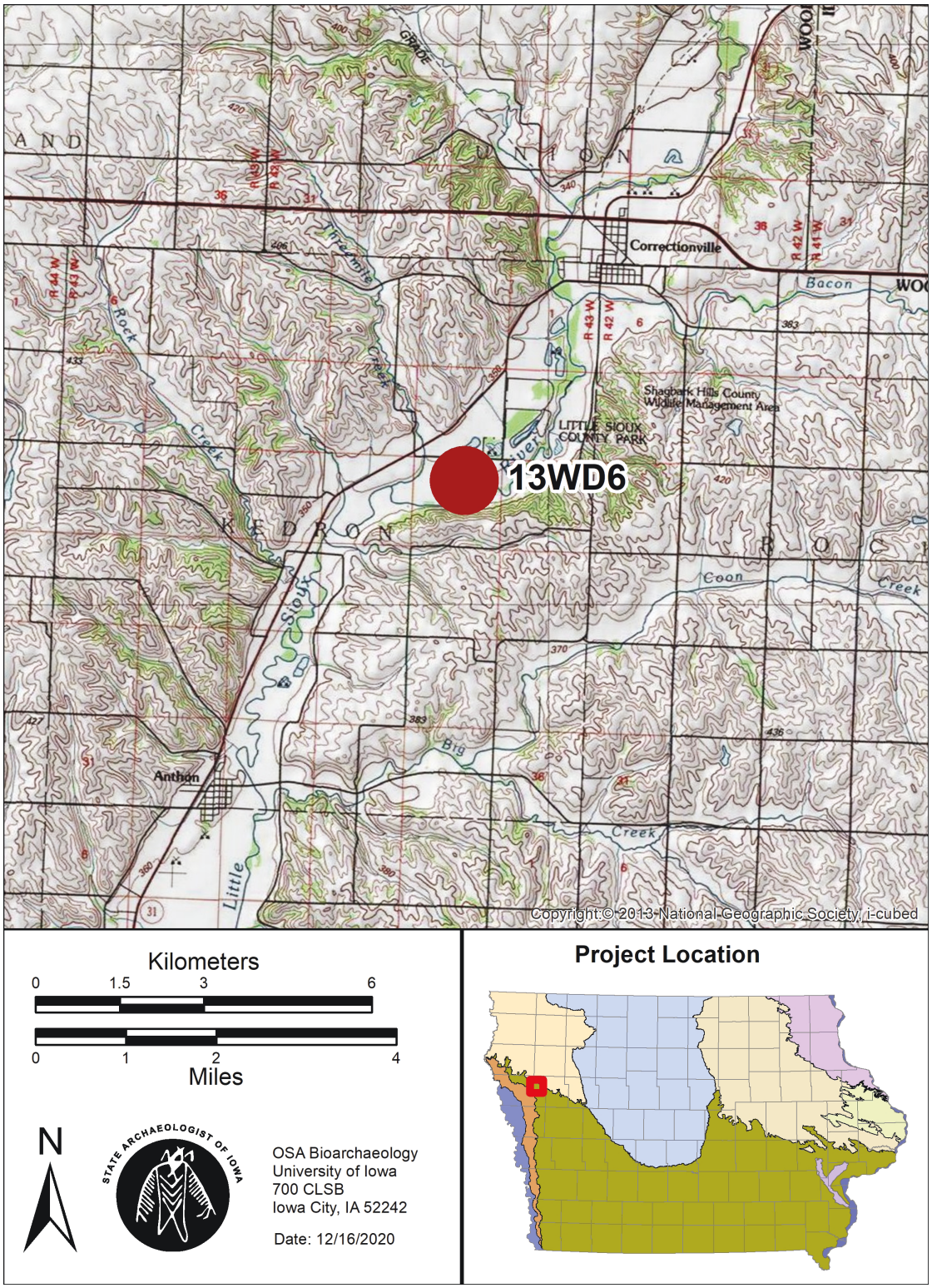

Figure 1. Location of 13WD6.
From USGS Correctionville, Woodbury County, Iowa (1969), 7.5' series quadrangle map. Scale 1:100,000.

Human Cranial Fragment Recovered ca. 1957 from the Correctionville Site (13WD6), Woodbury County, Iowa

Jennifer E. Mack

A human cranial fragment was discovered in 2019 among faunal remains from 13WD6, a large Oneota tradition village site excavated in 1957. The fragment represents an adult of unknown age and sex.

The Correctionville site, 13WD6, is a large Oneota tradition village site located in Section 14, Township 88 North, Range 43 West in Woodbury County (Figure 1). Known to archaeologists for almost 100 years, the site was first visited by Charles Keyes in 1925, when burials and pit features were reportedly being exposed by gravel quarrying. In 1957, members of the Northwest Chapter of the Iowa Archaeological Society and Dale Henning conducted salvage excavations at the site, which was rapidly being destroyed. Most of the materials recovered in 1957, as well as artifacts and human remains collected the following year, were reposed at the Sanford Museum in Cherokee, Iowa. On four previous occasions, human remains from 13WD6 have been transferred from the Sanford Museum to the OSA Bioarchaeology Program (OSA-BP) for reburial or repatriation. All of these remains have been reburied in consultation with tribes affiliated with the Oneota tradition in Iowa (Lillie and Schermer 2016).

In 2019, a researcher working on the 13WD6 collection from the Sanford Museum discovered a human cranial fragment mixed in with faunal remains from the site. The human remains were transferred to the OSA-BP in April 2019 (UI, OSA 2019).

The cranial vault fragment has a maximum diameter of 80 mm and includes portions of both the left and right parietals, fused along the sagittal suture. No recognizable landmarks are present, but the fragment probably originated from the midsection of the sagittal suture. The suture is completely obliterated endocranially; ectocranially, the suture appears largely closed though part of it is obscured by taphonomic erosion of the cortical surface. Based on suture closure and the thickness of the bone, the represented individual was an adult. Sex cannot be determined. No pathology is present. Both parietals exhibit deep vessel impressions on the endocranial surface, but this appears to be within the range of normal variation.

References Cited

Lillie, Robin M., and Shirley J. Schermer
2016 Human Skeletal Remains from the Correctionville Site, 13WD6, Woodbury County, Iowa. In *Bioarchaeological Reports on Human Skeletal Remains from Iowa and Other Proveniences,* edited by Robin M. Lillie and Lara Noldner, pp. 183-209. Research Papers Vol. 40, No. 1. Office of the State Archaeologist, University of Iowa, Iowa City.

University of Iowa, Office of the State Archaeologist (UI, OSA)
2019 Burial Project 3436. On file, Office of the State Archaeologist, University of Iowa, Iowa City.

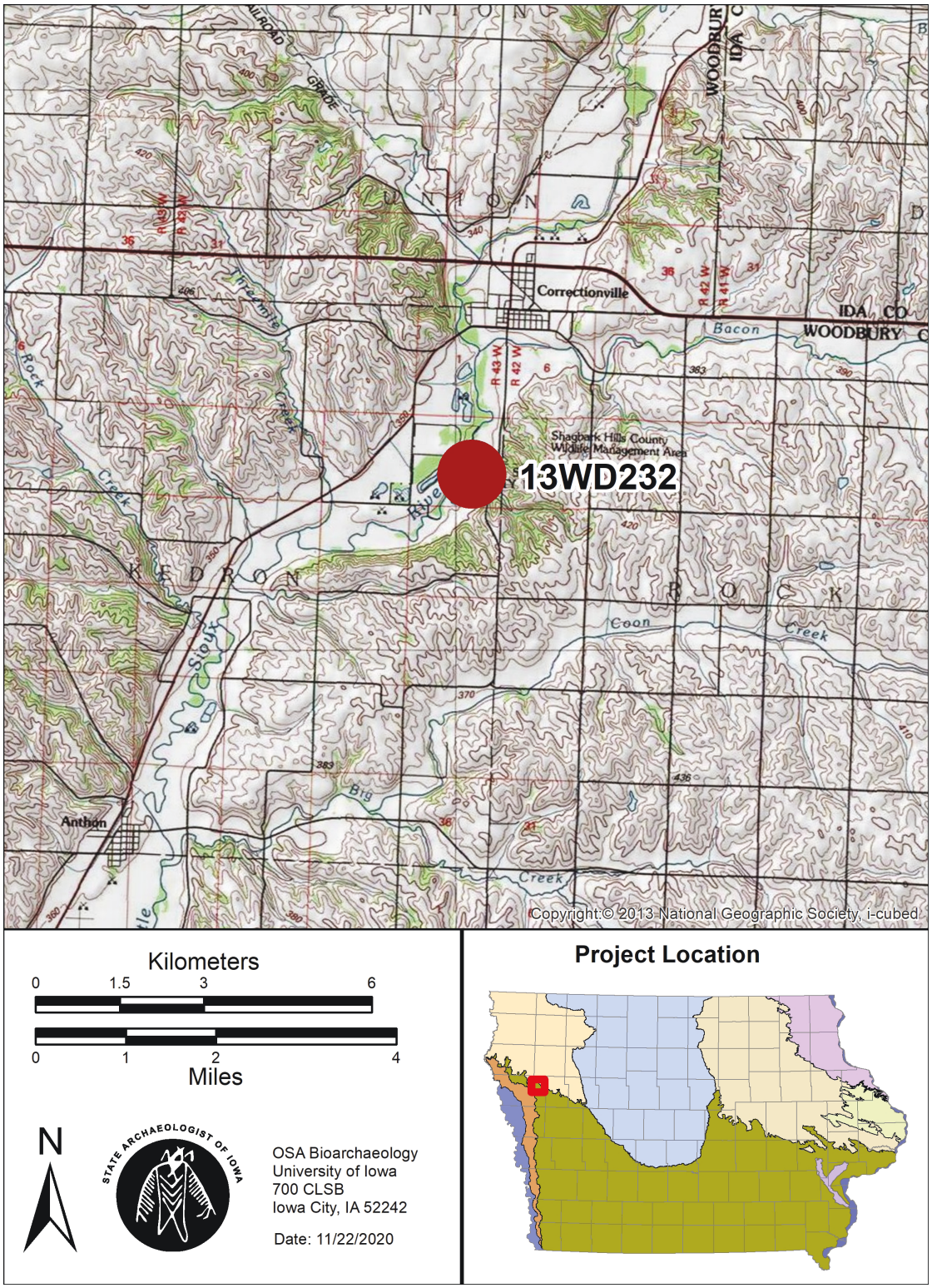

Figure 1. Findspot of human cranial remains, 13WD232.
From USGS Correctionville, Shelby County, Iowa (1969), 7.5' series quadrangle map. Scale 1:100,000.

Human Cranial Remains Discovered in the Little Sioux River (13WD232) in Woodbury County, Iowa

Jennifer E. Mack

Human cranial remains found out of context in the Little Sioux River in Woodbury County, Iowa, represent an adult of unknown age and sex. The original provenience of the remains is unknown. The condition of the cranial bones indicates antiquity, and etched lines are consistent with those seen on culturally modified human remains from Oneota tradition sites. The remains are presumed to be Native American.

Introduction

On October 14, 2020, a private citizen reported to the Woodbury County Sheriff's Office that he had found part of a human skull in the Little Sioux River in the vicinity of Little Sioux County Park, south of Correctionville, Iowa (Figure 1). The cranial fragment was turned over to the sheriff's department on October 19 and was assigned Woodbury County case #S20-11682. On October 22, the cranial fragment was transferred to the Iowa Office of the State Medical Examiner, where it was determined not to be of forensic significance. The fragment was then transferred to Office of the State Archaeologist, Bioarchaeology Program Director Lara Noldner on November 9. The findspot was designated site number 13WD232 (UI, OSA 2020).

The original provenience of the human remains is unknown. Multiple large Oneota tradition sites have been reported in the vicinity of the discovery, though most are downstream from the sandbar where the cranial fragment was found. One possible origin location is 13WD7, an Oneota tradition burial site approximately 1.7 km upstream from the findspot. This poorly documented site was largely destroyed by gravel quarrying in the early twentieth century, and it is unknown whether or not it extended as far east as the river. Ancient Native American remains have been recovered on several occasions in the stretch of the Little Sioux River between Correctionville and Oto, sometimes in association with artifacts. Human cranial remains were discovered at two locations in this area in 2013 (UI, OSA 2013a and b), but the recently recovered fragment does not refit with the previously recovered remains.

Osteological Analysis

The cranial fragment consists of most of a left parietal. Only a small portion of the coronal suture is present, close to but not including bregma. All of the sagittal suture is present, excluding bregma. The anterior half of the temporal suture is present, as is the superior two-thirds of the lambdoidal suture. The dark brown coloring, particularly on the endocranial surface, is consistent with human remains that have been recovered from an aquatic environment. The ectocranial surface is abraded, likely from movement along the river bottom. The thin ectocranial surface at the locations of three arachnoid foveae near bregma has been worn away postmortem, turning the foveae into perforations.

Age and sex cannot be determined from these remains. The cranial sutures appear to have been mostly closed endocranially and only minimally closed ectocranially, indicating the individual was likely an adult but not an old adult. No pathological bone was observed. The biological affinity of the individual cannot be determined osteologically, but the individual is presumed to be Native American. The condition of the remains is consistent with those recovered from precontact Native American sites in Iowa.

Two parallel scratches, one a straight line and one with a forked anterior end, are present just superior to the anterior portion of the left temporal suture. These lines appear etched rather than simply being taphonomic damage, and the dark color of the bone at the base of the incised lines demonstrates that these marks are not recent in origin. The two lines are etched more deeply at posterior end (wider, u-shaped profile) and more shallowly (with a v-shaped profile) at the anterior end. The lines are both 17.3 mm long. Not quite parallel, they are 3 mm apart on the posterior end and 1.6 mm apart on the anterior end. The superiormost of the two lines forks beginning 6 mm from the posterior end. The fork, which is more faintly incised, spreads superiorly and anteriorly and terminates 4.1 mm superior to the anterior end of the main etched line. These lines could represent incidental cut marks that occurred during defleshing or could reflect the Oneota tradition of cultural modification of human cranial bones, observed at other sites in the area.

Summary

An adult individual of unknown age and sex is represented by a human cranial fragment recovered from a sandbar in the Little Sioux River in Woodbury County, Iowa. The original context of the human remains is unknown. The condition of the remains is consistent with those recovered from precontact Native American sites in Iowa. The discovery location amidst numerous village and burial sites and the possible intentional cultural modification of the parietal both lend strength to the assumption of Native American origin. Cultural affiliation cannot be determined.

References Cited

Lillie, Robin M., and Shirley J. Schermer

2015 Design Motifs and Other Modifications of Human Bone from Iowa Late Prehistoric Oneota Sites. In *Transforming the Dead: Culturally Modified Bone in the Prehistoric Midwest*, edited by Eve A. Hargrave, Shirley J. Schermer, Kristin M. Hedman, and Robin M. Lillie. University of Alabama Press, Tuscaloosa, Alabama.

University of Iowa, Office of the State Archaeologist (UI, OSA)

2013a Burial Project 2960. On file, Office of the State Archaeologist, University of Iowa, Iowa City.

2013b Burial Project 2971. On file, Office of the State Archaeologist, University of Iowa, Iowa City.

2020 Burial Project 3544. On file, Office of the State Archaeologist, University of Iowa, Iowa City.

Human Remains of Unknown Provenience Transferred to Bioarchaeology Program in 2016

Jennifer E. Mack

Human remains of unknown provenience transferred to the Bioarchaeology Program by a private citizen represent a minimum of two individuals, including a middle adult male and a young adult of indeterminate sex. Dental morphology and attrition suggest these remains are ancient Native American. Two additional elements are unrelated anatomical specimens representing at least one adult individual of indeterminate sex.

Introduction

On March 14, 2016, a private citizen from Des Moines County, Iowa, contacted the OSA Bioarchaeology Program (OSA-BP) about turning over human remains he had inherited from a deceased relative. He did not know the origin of the remains, but he believed they had been in his family's possession since sometime around 1900 to the 1950s. Most of the remains were stored in two cigar boxes produced by Harkert & Finch, a cigar company based in Davenport, Iowa. According to a periodical about the tobacco industry, Harkert Cigar Company was incorporated in January 1906, replacing the former Harkert & Finch Company (*The Tobacco World* 1906), which was previously known as Harkert & Rhodes Co. (*Quad-City Times* 1922). The boxes, then, date to sometime between 1893 and 1905. However, the age of the boxes may not be related to the time period when the remains were discovered/excavated.

The human remains transferred to the OSA-BP clearly originated from two separate proveniences. All of the cranial and dental remains contained in the two cigar boxes are consistent in coloring and preservation, and are consistent in appearance with ancient human remains excavated from sites in Iowa. The donor believed these remains were likely Native American. Two additional elements, which were stored separately, are clean and exhibit no postmortem damage, suggesting they did not originate from a burial context. The glossy, ivory-like texture of some portions is consistent with that of prepared anatomical specimens.

Osteological Analysis

ANCIENT HUMAN REMAINS

The cigar boxes contained numerous cranial vault fragments, two refitting halves of a mandible, and an assortment of teeth with most of the enamel broken off postmortem. At least two individuals are represented by the cranial remains and two are represented by the teeth. The total MNI is two, though it is possible that additional duplicate teeth are present but are rendered unrecognizable by taphonomic damage. The designation Individual 1 was assigned to the more complete set of cranial remains, while Individual 2 consists of duplicated elements.

Individual 1

Individual 1 is represented by most of the left frontal (including the orbit), the anterior half of the left parietal, left temporal, and portions of the occipital including lambda, part of the left lambdoidal suture, and the cruciform eminence, with the external occipital protuberance heavily eroded by taphonomic processes. A small portion of the right parietal is present along the right lambdoid suture. The mandible is not definitively associated, but more likely belongs to Individual 1 than Individual 2, based on postmortem erosion observed on the occipital and posterior parietal of Individual 1 and on the posterior rami of the mandible. Additionally, the level of dental wear is consistent with the age estimate for Individual 1, while Individual 2 appears younger.

Based on cranial suture closure, Individual 1 was estimated to be a middle adult. The individual was possibly male, based on a blunt left supraorbital margin and somewhat prominent glabella. The square chin of the mandible is consistent with a male, which further supports the association of that element with Individual 1.

Ancestry could not be confidently determined for Individual 1 based on the cranial portions present, as facial and dental morphology was unobservable, and cranial metrics were not possible. The level of dentine exposure, which suggests the individual ate unprocessed foods, is consistent with that of prehistoric Native Americans. Two severely worn maxillary incisors from the cigar boxes have remnants of pronounced shoveling. Though the association of the maxillary teeth with this individual could not be ascertained, all of the cigar box remains likely originated from the same location, based on coloring and preservation. Thus, evidence of Native American ancestry for any of the remains most likely applies to all of the represented individuals.

Twelve teeth are present in the mandible or could be reassociated with it, and three teeth were missing postmortem or rendered unrecognizable among the commingled remains (listed below) by postmortem damage. See Tables 1 and 2 for mandibular dental inventory and metrics. All teeth are heavily worn, with large dentine exposures. Few morphological observations were possible, due to the level of attrition. The mandibular left M2 socket exhibits an abscess with significant pressure resorption of the buccal alveolar surface. Based on the rounded margins, it appears this abscess was in the process of healing, so the M2 may have been lost shortly before death. The left M1 socket may have been affected by the infection, too, though postmortem damage leaves this observation uncertain. The mandibular right M2 has a deep carious lesion on the distal interproximal surface of the root.

No pathology was observed on the cranial fragments.

Individual 2

Two duplicate landmarks—lambda and the left temporal suture—distinguish Individual 2 from Individual 1. The remains designated Individual 2 consist of a fragment of right parietal including a portion of the coronal suture, a fragment of left parietal including a portion of temporal suture, and the superior third of the occipital including lambda and the nuchal crest. These fragments are consistent in preservation, coloring, robusticity, and extent of suture closure, indicating that a single individual is represented, though the fragments do not refit.

Sex and ancestry cannot be determined from the remains present. The sutures are largely open, with closure just beginning on the endocranial surface at the time of death, suggesting this individual might have been a young adult. No pathology was observed.

Commingled Dental Remains

Twenty-four teeth from the cigar boxes could not be assigned to either individual (Table 3). Some of the dental remains are severely worn with just an enamel rim remaining. One such grouping of teeth includes a maxillary right central incisor, both lateral incisors (with remnants of shoveling near CEJ), and a right canine. Other teeth are unworn, with cusps barely blunted. Teeth with much of the enamel missing

appear to fall in between the two extremes, with small dentin exposures on remaining enamel. At least two individuals, one older and one younger, are represented by the commingled dental remains, consistent with Individuals 1 and 2. It is possible that additional individuals are represented by the partially worn teeth, but these cannot be distinguished with certainty, as many teeth were rendered unidentifiable by postmortem damage.

ANATOMICAL SPECIMENS

The two anatomical specimens included in the donated collection are a complete sacrum and a complete second lumbar vertebra. The clean and undamaged condition of both specimens suggests they did not originate from a burial context. Additionally, the glossy, ivory-like texture observed on some portions of the sacrum is consistent with that of prepared anatomical specimens.

Though the minimum number of individuals represented by these two elements is one, it is possible the remains originated from two individuals. The lumbar vertebra appears too gracile to belong to a column articulating with the sacrum. Additionally, the coloring of the two elements is slightly different, with the vertebra grayer and the sacrum more yellow. The possibility that both elements derived from the same individual cannot be entirely ruled out, though degenerative joint disease (DJD) is more pronounced on the sacrum than on the lumbar vertebra.

The lumbar vertebra has slight lipping on both superior articular processes. The left inferior articular process has very sight lipping, and the right inferior process has significant lipping which has changed the shape of the facet, expanding it inferiorly and posteriorly. The sacrum exhibits slight lipping on the superior articular facets. Much more significant osteophyte formation is present on the margins of the S1 body, forming an elevated rim on the lateral and anterior margins. The rim is more exaggerated on the left side. Both auricular surfaces also exhibit lipping, especially the left side, where the anterosuperior margin has been expanded by osteophyte formation. The lower border of the right auricular surface has an anteriorly-projecting osteophyte finger.

Summary

In 2016, human remains of unknown provenience were transferred to the OSA-BP by a private citizen who believed the remains had been collected by a relative during the first half of the twentieth century. Based on preservation, the cranial and dental remains were determined to be likely ancient, while separately stored vertebral elements were prepared anatomical specimens. At least two individuals, including a middle adult male and a young adult of indeterminate sex, are represented by the ancient remains. Dental morphology and attrition suggest these remains are ancient Native American. The two anatomical specimens represent at least one adult individual—possibly two—of indeterminate sex with moderate degenerative joint disease.

References Cited

University of Iowa, Office of the State Archaeologist (UI, OSA)
2016 Burial Project 3184. On file, Office of the State Archaeologist, University of Iowa, Iowa City.

The Tobacco World
1906 "Recent Incorporations, Etc." *The Tobacco World,* Vol. XXVI, No. 1. 3 January:7.

Quad-City Times
1922 "Hans Harkert Succumbs, Was 69 Years Old." 7 May:13.

Table 1. Dental Inventory, Burial Project 3184, Individual 1

Tooth	Presence	Attrition:	Attrition- molars:			
		I, C, P	Mes-buc	Mes-ling	Dis-ling	Dis-buc
MANDIBLE:						
LM3	2		4	4	5	5
LM2	4		0	0	0	0
LM1	5		0	0	0	0
LP2	2	4				
LP1	2	6				
LC	2	6				
LI2	2	6				
LI1	2	5				
RM3	2		6	6	6	6
RM2	2		7	4	7	7
RM1	2		4	6	6	4
RP2	2	4				
RP1	2	4				
RC	2	5				
RI2	5	9				
RI1	5	9				

Dental Inventory Key:

Presence

1 Present but not in occlusion
2 Present, development completed, in occlusion
3 Missing, with no associated alveolar bone
4 Missing, with alveolus resorbing or fully resorbed: antemortem loss
5 Missing, with no alveolar resorption: postmortem loss
6 Missing, congenital absence
7 Present, damage renders measurements impossible
8 Present but unobservable (e.g. teeth in crypts)
9 Unobservable

Attrition (I, C, PM)

1 Unworn or small facets
2 Point or hairline of dentin
3 Dentin line of distinct thickness
4 Moderate dentin exposure, not resembling a line
5 Large dentin area with rim complete (two areas on premolars)
6 Large dentin area with enamel rim lost on one side (two areas coalesced on premolars)
7 Enamel rim lost on two sides (at least one side lost on premolars)
8 Complete loss of crown, no enamel remaining
9 Unobservable

Attrition (molars)

0 Unobservable
1 Wear facets invisible or very small
2 Wear facets large, but cusps and surface features still evident
3 Any cusp in quadrant is rounded, but not flat
4 Quadrant is worn flat, but no dentin is exposed (except pinprick-sized)
5 Quadrant is flat, dentin exposed on ¼ of quadrant
6 More than ¼ of dentin is exposed, with enamel ring still complete
7 Enamel is found on only two sides of quadrant
8 Enamel on only one side of quadrant, but enamel is still thick
9 Enamel on only one side of quadrant and it is very thin
10 No enamel remaining. Wear extends below the cervicoenamel junction onto the root

Table 2. Dental Metrics (mm) Burial Project 3184, Individual 1

Tooth	Mesiodistal	Buccolingual	CEJ mesiodistal	CEJ buccolingual
MANDIBLE:				
LM3			9.2	
LM2				
LM1				
LP2			5.2	6.6
LP1			5.5	
LC			6.0	7.3
LI2				
LI1				
RM3			9.1	
RM2			8.8	
RM1			9.1	
RP2			5.3	
RP1			5.8	6.8
RC				7.1
RI2				
RI1				

Table 3. Commingled Dental Remains, Burial Project 3184

	# Left	# Right	# Unsided
Maxilla:			
C	1	1	1
I2	1	1	
I1		1	
Mandible:			
M3		1	
M1	1		
P2		1	
C	1		
I2		1	
Unidenfied teeth			13

A Human Tooth Discovered at the Sanford Museum in Cherokee County, Iowa

Jennifer E. Mack

A human tooth discovered in a desk drawer at the Sanford Museum represents an adult of unknown age and sex. Possible Native American ancestry is presumed from the context of discovery.

A human molar was discovered in a desk drawer at the Sanford Museum in Cherokee, Cherokee County, Iowa. The drawer also contained papers related to the Northwest Chapter of the Iowa Archaeological Society. Based on this association, and the fact that ancient human remains have been transferred to the OSA from museum's collections on several previous occasions, the origin from an archaeological context—potentially a Native American site—is considered likely (UI, OSA 2017).

The tooth appears to be a maxillary right third molar. Wear facets are present, but no dentin is exposed, suggesting that the individual was neither a very young nor very old adult. Age cannot be estimated any more precisely than older young adult to middle adult. Sex is unknown. A large carious lesion is present, affecting the cervical half of the distal root surfaces and part of the distal crown surface, obliterating the CEJ and exposing the pulp cavity. A portion of the lingual crown surface has broken off postmortem.

References Cited

University of Iowa, Office of the State Archaeologist (UI, OSA)
2017 Burial Project 3246. On file, Office of the State Archaeologist, University of Iowa, Iowa City.

Probable Native American Cranium from an Anatomical Collection, University of Iowa, Office of the State Archaeologist

Jennifer E. Mack

A human cranium that was part of the University of Iowa Office of the State Archaeologist's Bioarchaeology Program comparative collection was re-examined in 2018. Discriminant function analysis determined that the individual was likely Native American, though no distinctive morphological features were observed. Based on dental work, the individual is believed to have lived in the nineteenth or early twentieth century. The identity of the individual and provenience of the remains is unknown.

Introduction

The human cranium and mandible designated specimen 147 have been part of the University of Iowa Office of the State Archaeologist's comparative osteological collection for an undetermined period of time, likely several decades. Though the skull was clearly prepared as an anatomical specimen, no documentation exists providing details about the living individual or how the human remains came to be part of the university's collection. A previous review of the comparative collection for potential NAGPRA reporting did not identify the individual as Native American. In 2018, during student training in the use of the FORDISC discriminant function program, the individual was identified as likely Native American based on cranial metrics. The cranium and mandible were then removed from the collection for analysis in preparation for consultation in accordance with NAGPRA (UI, OSA 2018).

Osteological Analysis

The excellent condition of the cranium indicates that it was prepared as an anatomical specimen. The lack of traces of soil and the preservation of fragile portions such as the nasal conchae demonstrate that the remains were probably not removed from a burial context. Though grayish-beige rather than white, the cranial bone has an ivory-like texture typical of medical specimens, with a slight sheen that may be due to the application of a thin layer of preservative. The right mastoid process has green staining similar to that resulting from contact with copper salts either in a burial context or in improper storage conditions. Holes have been drilled through the temporomandibular joints and the mandibular condyles to allow for attachment of the mandible to the cranium. A hole drilled through bregma would have allowed the cranium to be mounted or suspended, but the lack of wear around this perforation suggests that it was never used for these purposes. One round and two linear depressions in the frontal have rounded edges but do not appear to be healed antemortem trauma. The bases of the two long depressions have a slightly porous appearance, as if most of the outer cortical bone was gouged away postmortem. The rounded edges, then, are likely due to handling over the years. Other signs of handling include breakage and enamel loss (or complete crown loss) from four maxillary teeth and six mandibular teeth, and the postmortem loss of the upper left lateral incisor. Glue was heavily applied to both the maxilla and the mandible in the past to prevent

further postmortem tooth loss. Numerous pencil marks and the specimen number 147 are also found on the cranium and mandible.

The skull has a prominent and rugose nuchal crest and a moderately prominent mental eminence, suggesting the individual was possibly male, though the mastoid processes, orbital margins, and glabella are all intermediate. Cranial suture closure suggests an age of between 31 and 60+ years. However, the lack of wear on the third molars suggests the individual was not an old adult. The anterior teeth exhibit significantly more wear than the molars. Though this pattern may be due to the use of teeth for habitual activities, the severity of anterior wear indicates the individual was not a young adult. Age is estimated at middle adult (35-50 years).

Based on cranial morphology, ancestry was initially believed to be European/White. The zygomatics are not particularly prominent or projecting, though there is a small malar tubercle. The palate shape is parabolic rather than rounded. Dental morphology could not be observed due to antemortem wear and postmortem breakage. However, results obtained using the FORDISC 3.1 discriminant function software strongly indicated Native American ancestry. When the individual's cranial measurements (Table 1) were compared with those of twentieth century White and Native American males and females in the Forensic Databank, the individual was found to be closest to Native American males, with a cross-validation rate of 86.8% and a posterior probability of 0.892. The typicality probabilities were also high (between 0.870 and 0.981). When the individual's measurements were compared with those of nineteenth-century White and Arikara males and females, the individual was found to be closest to Arikara males, with a cross-validation rate of 90.5% and posterior probability of 0.974. The typicality probabilities ranged from 0.744 to 0.916.

Due to the previously mentioned wear and postmortem damage, most dental crown measurements were not possible. Measurements at the CEJ could not be performed due to the presence of glue between the teeth. See Tables 2 and 3 for dental inventory and available metrics. All teeth were present at the time of death. The maxillary left lateral incisor was lost postmortem and the crowns of the mandibular left first premolar and incisors and the right central incisor were all broken off postmortem. Moderately thick calculus accumulations are present, primarily on the lingual surface. The buccal surfaces may have acquired less calculus, but it is also possible that the buccal calculus was lost due to handling over time.

A 3.4 mm (mesiodistal) x 2.0 mm (buccolingual) perforation in the center of the occlusal surface of the maxillary right central incisor was created by drilling. Under strong lighting and magnification, silver-colored material is visible in longitudinal cracks within the void, with an additional small clump of material adhering to the internal surface. Parts of the internal surface are stained red. A wire inserted into the perforation demonstrated that the void extends 11 mm from the worn occlusal surface into the root of the tooth. As this type of drilling is consistent with a root canal procedure, dental x-rays were obtained. Cleaned root canals are usually filled with gutta percha before the perforated crown is filled or the tooth is capped. No trace of filling material was found within the root of the tooth. The silver-colored material noted in the crown was found to be the remnant of a mercury-based amalgam filling, which may have been subsequently drilled out. According to a consulting dentist, the lack of filling in the root canal itself would be consistent with a pulpotomy, a procedure which involves the opening of the pulp chamber and removal of pulp from the crown only, followed by the application of medication and the filling of the crown. This procedure is sometimes performed when severe occlusal wear and dentin exposure causes sensitivity and pain (Dr. Lori Fridrich, personal communication 2021). Why the filling would have later been removed is unknown. Amalgam dental fillings were first introduced to the United States in 1833 and continue to be used in the twenty-first century (Ramesh *et al.* 2010). The dental procedure and the filling material indicate that this individual died sometime in the nineteenth or twentieth centuries.

Three pathological abnormalities were observed on the cranium. The most immediately noticeable is the asymmetry of the occipital, which is slightly flattened on the left side. The posterior-most one-fifth of the left parietal is also slightly flattened. The deformity is mild and likely developmental rather than trauma-related. As a result of this asymmetry, the pronounced external occipital crest is slightly to the right of

midline. Additionally, the right occipital condyle is longer, while the left condyle is broader mediolaterally. The right condyle has slight lipping on the postero-lateral margin, which is absent on the left. The left styloid process is almost twice as long as the right.

A small oval-shaped button osteoma, with a maximum diameter of 5.8 mm, is located on the right parietal just lateral to obelion.

Periosteal bone apposition is present on the inferior surface of the petrous portions, especially around the carotid canals and at the base of the styloid processes. The woven appearance of the bone suggests the process was active at the time of death, though on the anterior portion of the petrous the apposition appears sclerotic. A small amount of woven bone is also present on both sides of the perpendicular plate of vomer, close to where the plate meets the alae. The anterior two-thirds of the maxillary palate exhibits porosity, but this may fall within the range of normal variation.

Summary

The individual represented by these unprovenienced cranial remains was possibly male and likely between the ages of 35 and 50 years. Though lacking facial structure recognizable as Native American, the individual's cranial metrics strongly suggest Native American ancestry. Modifications of the cranium and mandible indicate the skull was used as an anatomical study specimen. Though the severity of the anterior tooth wear and the green copper stain on the right mastoid initially suggested the remains may have been excavated from a prehistoric burial, the clean condition and excellent preservation of fragile bones (such as the nasal conchae) indicate that the specimen was prepared soon after death. The tooth wear, which is much more pronounced on the anterior teeth, may relate to use of the teeth for habitual activity, and the staining could have occurred through contact with copper in storage rather than in a grave. Lending support to the dating of this individual to the recent historic period is evidence of a pulpotomy procedure and subsequent amalgam filling in the maxillary right central incisor. It is possible that such a procedure might have been performed postmortem, for practice. However, the preponderance of evidence suggests this individual lived between the 1830s, when amalgam fillings were introduced to the United States, and the 1970s, when professor of dentistry and former Bioarchaeology Program director Alton K. Fisher began to work for the OSA and accumulate the comparative osteological collection.

References Cited

Ramesh, Bharti, Kulvinder Kaur Wadhwani, Aseem Prakash Tikku, and Anil Chandra
2010 Dental Amalgam: An Update. *Journal of Conservative Dentistry* 13(4):204-208.

University of Iowa, Office of the State Archaeologist (UI, OSA)
2018 Burial Project 3283. On file, Office of the State Archaeologist, University of Iowa, Iowa City.

Table 1. Cranial Metrics (mm), Burial Project 3283

Cranial metric	Individual 1
Maximum cranial length	186
Maximum cranial breadth	147
Bizygomatic diameter	143
Basion-bregma height	128
Cranial base length	102
Basion-prosthion length	100
Maxillo-Alveolar breadth	67
Maxillo-Alveolar length	59
Biauricular breadth	132.5
Upper facial height	76
Minimum frontal breadth	92
Upper facial breadth	106
Nasal height	54.5
Nasal breadth	25
Orbital breadth L	42
Orbital breadth R	43
Orbital height L	35
Orbital height R	35
Biorbital breadth	101
Interorbital breadth	18
Frontal chord	112
Parietal chord	110
Occipital chord	92
Foramen magnum length	34
Foramen magnum breadth	28
Mastoid length L	24
Mastoid length R	25
Chin height	38
Mandibular height L	36
Mandibular height R	34
Bigonial width	108.5
Bicondylar breadth	123.5
Minimum ramus breadth L	37
Minimum ramus breadth R	40
Maximum ramus breadth L	47
Maximum ramus breadth R	48
Ramus height L	67
Ramus height R	67
Mandibular length	89
Mandibular angle	116

Table 2. Dental Inventory, Burial Project 3283

Tooth	Presence	Attrition:	Attrition- molars:			
		I, C, P	Mes-buc	Mes-ling	Dis-ling	Dis-buc
MAXILLA:						
RM3	2		1	2	2	1
RM2	7		3	3	3	3
RM1	2		5	6	5	5
RP2	7	5				
RP1	2	5				
RC	2	5				
RI2	7	9				
RI1	2	5				
LM3	2		1	1	1	1
LM2	2		3	3	3	3
LM1	2		5	6	5	5
LP2	2	5				
LP1	2	5				
LC	7	5				
LI2	5	9				
LI1	2	5				
MANDIBLE:						
LM3	2		3	2	2	3
LM2	2		5	3	3	4
LM1	2		6	6	5	7
LP2	2	4				
LP1	7	9				
LC	7	9				
LI2	7	9				
LI1	7	9				
RM3	2		3	2	2	3
RM2	2		5	3	3	4
RM1	2		6	5	5	6
RP2	2	4				
RP1	2	6				
RC	2	5				
RI2	7	5				
RI1	7	9				

Dental Inventory Key:

Presence

1 Present but not in occlusion
2 Present, development completed, in occlusion
3 Missing, with no associated alveolar bone
4 Missing, with alveolus resorbing or fully resorbed: antemortem loss
5 Missing, with no alveolar resorption: postmortem loss
6 Missing, congenital absence
7 Present, damage renders measurements impossible
8 Present but unobservable (e.g. teeth in crypts)
9 Unobservable

Attrition (I, C, PM)

1 Unworn or small facets
2 Point or hairline of dentin
3 Dentin line of distinct thickness
4 Moderate dentin exposure, not resembling a line
5 Large dentin area with rim complete (two areas on premolars)
6 Large dentin area with enamel rim lost on one side (two areas coalesced on premolars)
7 Enamel rim lost on two sides (at least one side lost on premolars)
8 Complete loss of crown, no enamel remaining
9 Unobservable

Attrition (molars)

0 Unobservable
1 Wear facets invisible or very small
2 Wear facets large, but cusps and surface features still evident
3 Any cusp in quadrant is rounded, but not flat
4 Quadrant is worn flat, but no dentin is exposed (except pinprick-sized)
5 Quadrant is flat, dentin exposed on ¼ of quadrant
6 More than ¼ of dentin is exposed, with enamel ring still complete
7 Enamel is found on only two sides of quadrant
8 Enamel on only one side of quadrant, but enamel is still thick
9 Enamel on only one side of quadrant and it is very thin
10 No enamel remaining. Wear extends below the cervicoenamel junction onto the root

Table 3. Dental Metrics (mm), Burial Project 3283

Tooth	Mesiodistal	Buccolingual
MAXILLA:		
RM3	9.4	10.9
LM3	9.5	11.0
LM2	10.0	12.5
MANDIBLE:		
LM3	11.0	10.2
LM2	11.2	11.0
LM1	12.1	11.4
LP2	7.1	8.2
RM3	10.7	10.2
RM2	11.5	10.9
RM1	12.0	11.4
RP2	7.1	8.6

Human Skeletal Remains from Iowa, Formerly in Kansas State University Collections

Jennifer E. Mack

At least eight individuals are represented by fragmented and commingled human remains transferred from the Department of Anthropology at Kansas State University to the Office of the State Archaeologist Bioarchaeology Program (OSA-BP) in 2018. Precise provenience of the remains is unknown, but oral history indicates that they were recovered from archaeological sites in Iowa. Dental wear and incisor shoveling suggest the remains are most likely Native American. Represented individuals include three adults, two young adults or adolescents, two subadults aged 1–4 years, and a fetal to newborn infant.

Introduction

In 2018, a professor in the Department of Anthropology at Kansas State University (KSU) contacted the University of Iowa Office of the State Archaeologist Bioarchaeology Program (OSA-BP) regarding a box of commingled human remains from Iowa. Sometime in the 1970s, archaeologists donated skeletal remains from an unknown location (or locations) in Iowa to Dr. Michael Finnegan at KSU for use in teaching. Upon retirement, Dr. Finnegan wanted the remains returned to Iowa. In January 2019, the remains were transferred to the OSA-BP (UI, OSA 2018). A general inventory of the remains (dated October 2001) was included in the box, and the remains had been separated by element.

Osteological Analysis

The collection of commingled remains consists of 270 elements, partial elements, and bone fragments and 32 teeth. Two maxillae and one mandible represent distinct adults (Individuals 1–3), a maxillary portion represents an adolescent or young adult (Individual 4), and three cranial fragments represent a distinct subadult (Individual 5). Three additional individuals—a second adolescent/young adult and two young subadults—are represented by duplicate elements present in the commingled remains. The condition of the bones, including fragmentation, root-etching, and general postmortem cortical erosion, is consistent with the narrative that the remains originated from archaeological contexts.

INDIVIDUAL 1

Individual 1 is represented by an incomplete maxilla with six teeth in situ (Tables 1–3). The right maxilla is represented by the complete alveolus and a portion of the palate. The left maxilla is represented by the alveolus from the first incisor to the second premolar (including one root socket of the first molar), the frontal process, and the anterior portion of the palate. The incisors, canines, and right second premolar were lost postmortem. Both first premolars and the right second molar are present and exhibit significant wear. The right second premolar and first and third molars are represented by roots only, the crowns having been completely destroyed by caries. The right first molar socket has postmortem damage but the socket

expansion associated with an abscess is still observable, and appears to have resulted in buccal perforation. The right second molar has a carious lesion on the distal interproximal surface. Purple staining most likely related to fungal colonization is present on the right premolars (Piepenbrink 1986).

Sex cannot be determined for this individual based on the portions preserved. Age is roughly estimated as middle to old adult based solely on dental wear (significant dentin exposure). Ancestry is presumed to be Native American based on information concerning the collection. The palate appears rounded, which supports the identification of the individual as Native American.

The preserved portions of the palate exhibit marked thinning and porosity, with at least one coalescence of pores perforating the floor of the nasal aperture. The incisive foramen and incisive canal appear enlarged. These alterations are likely due to inflammation related to the severe caries and the abscess.

Two teeth that cannot be definitively identified—a probable maxillary canine and maxillary molar—may also belong to this individual, though they were recorded as commingled remains. The canine was nearly worn down to the root before a carious lesion destroyed the occlusal surface. The molar has severe cup-shaped wear with an incomplete enamel rim and purple fungal staining.

Table 1. Dental Inventory, Burial Project 3402, Individual 1

Tooth	Presence	Attrition:	Attrition- molars:			
		I, C, P	Mes-buc	Mes-ling	Dis-ling	Dis-buc
MAXILLA:						
RM3	7		0	0	0	0
RM2	2		7	7	0	7
RM1	7		0	0	0	0
RP2	7	9				
RP1	2	5				
RC	5	9				
RI2	5	9				
RI1	5	9				
LM3	3		0	0	0	0
LM2	3		0	0	0	0
LM1	5		0	0	0	0
LP2	5	9				
LP1	2	5				
LC	5	9				
LI2	5	9				
LI1	5	9				

Dental Inventory Key:

Presence

1 Present but not in occlusion
2 Present, development completed, in occlusion
3 Missing, with no associated alveolar bone
4 Missing, with alveolus resorbing or fully resorbed: antemortem loss
5 Missing, with no alveolar resorption: postmortem loss
6 Missing, congenital absence
7 Present, damage renders measurements impossible
8 Present but unobservable (e.g. teeth in crypts)
9 Unobservable

Attrition (I, C, PM)

1 Unworn or small facets
2 Point or hairline of dentin
3 Dentin line of distinct thickness
4 Moderate dentin exposure, not resembling a line
5 Large dentin area with rim complete (two areas on premolars)
6 Large dentin area with enamel rim lost on one side (two areas coalesced on premolars)
7 Enamel rim lost on two sides (at least one side lost on premolars)
8 Complete loss of crown, no enamel remaining
9 Unobservable

Attrition (molars)

0 Unobservable
1 Wear facets invisible or very small
2 Wear facets large, but cusps and surface features still evident
3 Any cusp in quadrant is rounded, but not flat
4 Quadrant is worn flat, but no dentin is exposed (except pinprick-sized)
5 Quadrant is flat, dentin exposed on ¼ of quadrant
6 More than ¼ of dentin is exposed, with enamel ring still complete
7 Enamel is found on only two sides of quadrant
8 Enamel on only one side of quadrant, but enamel is still thick
9 Enamel on only one side of quadrant and it is very thin
10 No enamel remaining. Wear extends below the cervicoenamel junction onto the root

Table 2. Dental Metrics (mm), Burial Project 3402, Individual 1

Tooth	Mesiodistal	Buccolingual	CEJ mesiodistal	CEJ buccolingual
MAXILLA:				
RM2				10.64
RP1			5.30	8.46
LP1			5.62	8.55

Table 3. Dental Pathologies, Burial Project 3402, Individual 1

Tooth	Calculus:		Caries:		Abscess:
	Presence	Location	Number	Type	Type
MAXILLA:					
RM3			1	large	
RM2			1	distal inter-proximal	
RM1			1	large	Buccal perforation
RP2			1	large	

INDIVIDUAL 2

Individual 2 is represented by an incomplete maxilla with 12 teeth in situ (Tables 4 and 5). The four absent teeth, the right central incisor through left canine, were lost postmortem. The right maxilla is represented by the alveolus and teeth only, and the portion of alveolus distal to the third molar is absent. The left alveolus is complete except for the anterior portions of the incisor sockets. The posterior portion of the left zygomatic process is also present, as are the lower borders of the nasal aperture.

Dental health appears good. No carious lesions or other pathologies are present. A small amount of calculus accumulation was observed on the left first and third molars. Calculus may have been present on other teeth during life but lost during excavation, cleaning, or storage, as a good bit of dental enamel has been chipped off postmortem.

Dental wear is significant, though not quite as severe as that seen in Individual 1. This wear suggests the individual was not a young adult, though may not have been an old adult (>50 years) either, depending on the diet of this population. Sex cannot be determined. Most dental morphology observations that might be used to evaluate biological affinity are not possible due to wear and the loss of anterior teeth. The palate shape is not particularly rounded, but the individual was determined to be likely Native American based on observations of the collection as a whole.

Table 4. Dental Inventory, Burial Projects 3402, Individual 2

Tooth	Presence	Attrition:	Attrition- molars:			
		I, C, P	Mes-buc	Mes-ling	Dis-ling	Dis-buc
MAXILLA:						
RM3	2		0	7	7	0
RM2	2		0	0	0	0
RM1	2		7	0	7	7
RP2	2	6				
RP1	2	5				
RC	2	5				
RI2	2	5				
RI1	5	9				
LM3	2		0	7	7	5
LM2	2		6	7	7	5
LM1	2		7	0	7	7
LP2	2	6				
LP1	2	5				
LC	5	9				
LI2	5	9				
LI1	5	9				

Dental Inventory Key:

Presence

1 Present but not in occlusion
2 Present, development completed, in occlusion
3 Missing, with no associated alveolar bone
4 Missing, with alveolus resorbing or fully resorbed: antemortem loss
5 Missing, with no alveolar resorption: postmortem loss
6 Missing, congenital absence
7 Present, damage renders measurements impossible
8 Present but unobservable (e.g. teeth in crypts)
9 Unobservable

Attrition (I, C, PM)

1 Unworn or small facets
2 Point or hairline of dentin
3 Dentin line of distinct thickness
4 Moderate dentin exposure, not resembling a line
5 Large dentin area with rim complete (two areas on premolars)
6 Large dentin area with enamel rim lost on one side (two areas coalesced on premolars)
7 Enamel rim lost on two sides (at least one side lost on premolars)
8 Complete loss of crown, no enamel remaining
9 Unobservable

Attrition (molars)

0 Unobservable
1 Wear facets invisible or very small
2 Wear facets large, but cusps and surface features still evident
3 Any cusp in quadrant is rounded, but not flat
4 Quadrant is worn flat, but no dentin is exposed (except pinprick-sized)
5 Quadrant is flat, dentin exposed on ¼ of quadrant
6 More than ¼ of dentin is exposed, with enamel ring still complete
7 Enamel is found on only two sides of quadrant
8 Enamel on only one side of quadrant, but enamel is still thick
9 Enamel on only one side of quadrant and it is very thin
10 No enamel remaining. Wear extends below the cervicoenamel junction onto the root

Table 5. Dental Metrics (mm) Burial Project 3402, Individual 2

Tooth	Mesiodistal	Buccolingual	CEJ mesiodistal	CEJ buccolingual
MAXILLA:				
RM3			7.3	9.8
RM1			8.0	11.4
RP2			4.4	
RP1			4.7	
RC			6.2	7.8
RI2			5.3	
LM3			7.6	9.9
LM2			7.8	10.8
LM1			7.7	
LP2			5.0	7.8
LP1			5.1	

INDIVIDUAL 3

Individual 3 is represented by an incomplete mandible with 10 teeth in situ (Tables 6 and 7). The portion of left ramus distal to the mesial margin of the first molar is absent. The left first molar was lost postmortem, as were the left canine and incisors; all of the right teeth are present. No carious lesions or calculus is present.

The extremely pronounced mental eminence and everted chin suggest the individual was male, though sex estimation based on a single morphological feature is tenuous. Gonial eversion is unobservable since that portion of the right vertical ramus is absent. Based on dental wear—with significant dentin exposure on all teeth—the individual is likely a middle or old adult. Some of the dental wear may be related to habitual activity rather than age. The incisors exhibit greater wear than the rest of the teeth, with no crowns remaining, and the wear angles downward anteriorly. Meanwhile, the premolars and canine appear to have more than half of the crown height remaining.

This mandible does not properly occlude with either of the maxillae designated Individuals 1 and 2, and therefore represents a distinct individual.

INDIVIDUAL 4

Individual 4 is represented by a small portion of the right maxilla with the right lateral incisor, canine, and first premolar in situ (Tables 8 and 9). The central incisor and second premolar were lost postmortem. Almost no dental wear is evident on the three teeth present, but the individual was not a child, as the first premolar is fully erupted and the appearance of the socket for second premolar suggests full eruption as well. Thus, the individual was likely 12 years old or older. Sex is indeterminate. Shoveling on the lateral incisor suggests Native American ancestry. No pathology was noted.

These dental remains may or may not belong to one of the two young adult/adolescent individuals represented by commingled cranial remains (described in the commingled section below).

INDIVIDUAL 5

Individual 5 is represented by an unsided parietal fragment, an unidentified cranial vault fragment, and a fragment of the pars squama of the temporal. The size and morphology of the fragments, particularly the thin cross-section of the parietal, indicates the represented individual was fetal or newborn. Sex and ancestry are indeterminate. No other elements present in the collection represent an individual of this age.

Table 6. Dental Inventory, Burial Project 3402, Individual 3

Tooth	Presence	Attrition:	Attrition- molars:			
		I, C, P	Mes-buc	Mes-ling	Dis-ling	Dis-buc
MANDIBLE:						
LM3	3		0	0	0	0
LM2	3		0	0	0	0
LM1	5		0	0	0	0
LP2	2		6			
LP1	7		6			
LC	5		9			
LI2	5		9			
LI1	5		9			
RM3	2		7	7	7	7
RM2	2		8	7	7	8
RM1	2		7	7	7	7
RP2	2	6				
RP1	2	6				
RC	2	6				
RI2	2	8				
RI1	2	8				

Dental Inventory Key:
Presence
1 Present but not in occlusion
2 Present, development completed, in occlusion
3 Missing, with no associated alveolar bone
4 Missing, with alveolus resorbing or fully resorbed: antemortem loss
5 Missing, with no alveolar resorption: postmortem loss
6 Missing, congenital absence
7 Present, damage renders measurements impossible
8 Present but unobservable (e.g. teeth in crypts)
9 Unobservable
Attrition (I, C, PM)
1 Unworn or small facets
2 Point or hairline of dentin
3 Dentin line of distinct thickness
4 Moderate dentin exposure, not resembling a line
5 Large dentin area with rim complete (two areas on premolars)
6 Large dentin area with enamel rim lost on one side (two areas coalesced on premolars)
7 Enamel rim lost on two sides (at least one side lost on premolars)
8 Complete loss of crown, no enamel remaining
9 Unobservable
Attrition (molars)
0 Unobservable
1 Wear facets invisible or very small
2 Wear facets large, but cusps and surface features still evident
3 Any cusp in quadrant is rounded, but not flat
4 Quadrant is worn flat, but no dentin is exposed (except pinprick-sized)
5 Quadrant is flat, dentin exposed on ¼ of quadrant
6 More than ¼ of dentin is exposed, with enamel ring still complete
7 Enamel is found on only two sides of quadrant
8 Enamel on only one side of quadrant, but enamel is still thick
9 Enamel on only one side of quadrant and it is very thin
10 No enamel remaining. Wear extends below the cervicoenamel junction onto the root

Table 7. Dental Metrics (mm), Burial Project 3402, Individual 3

Tooth	Mesiodistal	Buccolingual	CEJ mesiodistal	CEJ buccolingual
MANDIBLE:				
LP2			5.2	7.3
LP1				7.3
RM3			8.6	8.5
RM2			9.9	
RM1			9.7	9.4
RP2			5.4	7.9
RP1			5.1	7.5
RC			5.5	7.7

Table 8. Dental Inventory, Burial Project 3402, Individual 4

Tooth	Presence	Attrition:	Attrition- molars:			
		I, C, P	Mes-buc	Mes-ling	Dis-ling	Dis-buc
MAXILLA:						
RM3	3		0	0	0	0
RM2	3		0	0	0	0
RM1	3		0	0	0	0
RP2	5	9				
RP1	2	1				
RC	2	1				
RI2	2	1				
RI1	5	9				

Table 9. Dental Metrics (mm), Burial Project 3402, Individual 4

Tooth	Mesiodistal	Buccolingual	CEJ mesiodistal	CEJ buccolingual
MAXILLA:				
RP1	8.1	10.8	5.4	9.1
RC	8.9	9.4	6.9	8.7
RI2	8.3	6.4	6.1	6.0

COMMINGLED REMAINS

Adult Commingled Remains

For the majority of the commingled cranial and postcranial remains (222 fragments, see Table 10), sex could not be determined, and age could not be estimated beyond the category of adult (>20 years). The minimum number of individuals (MNI) represented by these commingled remains, three, is consistent with the three distinct individuals represented by the dental remains (described above). It is unknown, however, whether there is any correspondence between the designated three individuals and the postcranial remains.

At least two adult individuals are represented by the commingled cranial remains, based on non-matching right and left mastoid processes, two non-matching fragments of right mandibular ramus, left and right non-matching fragments of orbital wall of the frontal, and two left external auditory meatus. Two individuals are also represented by two left scapulae, two left radii, and two left ulnae. At least three individuals are represented by two right femora and three left femora (no identifiable matching pairs), and three left fibulae.

There are also three left tibiae and three right tibiae, with two matching pairs. The remaining two tibiae are complete enough to exclude matching, bringing the MNI represented by tibiae to 4. However, since both of the non-matching tibiae consist of shafts only, with no epiphyseal ends, either specimen could represent an adolescent. Therefore, these tibiae do not increase the overall MNI of three indeterminate adults for the collection.

Some pathological bone was observed on the commingled adult remains. Periosteal new bone formation is seen on two right tibiae and a metatarsal shaft. The shaft of the unidentified metatarsal is covered circumferentially with periosteal new bone formation, with expansion and malformation of the shaft. On three sides the new bone is sclerotic. On the dorsal surface, the bone is woven and was active at the time of death.

One right tibia has a small amount of periosteal new bone formation on the lateral diaphyseal surface of near midshaft. The patch measures 46 mm superoinferiorly x 17 mm anteroposteriorly. The bone appears woven and is elevated above the normal cortical surface. The medullary cavity is choked with very fine trabecular bone with a net-like appearance. The second pathological right tibia has a large amount of well-healed/resorbed periosteal new bone present circumferentially and covering the entire shaft portion present (middle 3/4 of shaft). Apposition is most pronounced on the medial surface, which has a rounded, almost puffy appearance. Porosity and striae are still visible, but the new bone appears well-incorporated into the surface. Platey trabecular bone has been deposited on the surfaces of the medullary cavity along the length of the shaft present, suggestive of osteomyelitis.

Young Adult/Adolescent Remains

Of the commingled fragments, 29 could be identified as belonging to adolescents or young adults aged 14 to 23 years (Table 11). This identification was made when the size and general morphology of elements/fragments were consistent with adult remains, but features such as open cranial sutures or unfused or fusing epiphyseal surfaces were observed. The MNI for this age range is two, including the dental remains designated Individual 4 and at least one additional individual. The presence of the second individual is indicated by duplicate elements, two left temporals and two left zygomatics. Other elements in this age range include fragments of a left os coxa with unfused iliac crest and fusing ischial tuberosity, an adult-sized left humerus with an unfused head, lumbar vertebral fragments with unfused and partially fused annular rings, an adult-sized right femur with unfused lesser trochanter, an unfused femoral condyle, and an adult-sized left proximal tibia shaft with unfused epiphysis.

No pathology was observed on the commingled adolescent/young adult cranial or postcranial remains.

Subadult Commingled Remains

Few younger subadult remains were included in this collection. Eleven cranial fragments and a left first metacarpal represent two individuals aged 1–4 years. Age is based on fusion of the petromastoid and squamotympanic parts and partial growth of the anterior and posterior tympanic tubercles on a right temporal fragment. Consistent with this age is a left orbit with an unfused metopic suture (too robust for a newborn), the general size of a left orbital fragment (consistent with the remains of a 2.5–3.5-year-old) and the general thickness of several cranial vault fragments. MNI is based on duplication of the left orbit.

A fragment that appears to be from the greater wing of the sphenoid exhibits porosity and irregular texture on the ectocranial surface, with some pores perforating through the endocranial surface. The endocranial surface has a porous and slightly puffy appearance, suggesting abnormal bone apposition. These changes are more irregular than those related to normal subadult bone growth.

Table 10. Commingled Adult Remains, Burial Project 3402

Element	Number of Fragments/ Specimens	MNE Left	MNE Right	MNE Midline	MNE Unsided
Cranium/mandible	49			2 adult	
Atlas	3			2	
Thoracic vertebrae	4			2	
Lumbar vertebrae	8			4	
Unidentified vertebrae	5				
Sacrum	1			1	
Rib 1	1	1			
Ribs 2-12	31	5	4		1
Scapula	6	2	1		
Humerus	3		2		1
Radius	5	2	1		
Ulna	4	2			
Metacarpals	1				
Hand phalanges	2				2
Os coxa	10	1	1		1
Femur	5	3	2		
Tibia	12	3	3		
Fibula	7	3	1		
Talus	1		1		
Calcaneus	5	2	2		
Tarsals	2	1			
Metatarsals	2	1			1
Foot phalanges	2				
Indeterminate fragments	53				

Table 11. Subadult Commingled Remains, Burial Project 3402

Element	Number of Fragments/ Specimens	MNE Left	MNE Right	MNE Midline	MNE Unsided	Age Range
Cranium/mandible	11			2		1-4 yr
Cranium/mandible	17			2		adolescent-young adult
Lumbar vertebrae	6				4	14-23 yr
Humerus	1	1				14-21 yr
Metacarpals	1	1				1-4 yr
Os coxa	2	1				16-18 yr
Femur	2		1			14-19 yr
Tibia	1	1				14-20 yr
Indeterminate fragments	1					

Summary

In January 2019, a box of human skeletal remains previously used for teaching was transferred from the Department of Anthropology at Kansas State University to the OSA-BP. The condition of the remains is consistent with the narrative that they originated from ancient archaeological sites in Iowa, though precise provenience is unknown. Based on consistent preservation and coloring, all of the remains may have originated from the same site.

At least eight individuals are represented by the fragmented and commingled remains, including three adults, two young adults or adolescents, two subadults aged 1–4 years, and a fetal to newborn infant. Pathological bone formation was observed on three adult elements and one subadult cranial fragment, indicating both periosteal bone deposition and osteomyelitis. The dental remains of three adults are severely worn, and the unworn lateral incisor of an adolescent or young adult displays marked shoveling. Based on this evidence all individuals represented in this collection are likely Native American.

References Cited

Piepenbrink, Hermann
1986 Two Examples of Biogenous Dead Bone Decomposition and Their Consequences for Taphonomic Interpretation. *Journal of Archaeological Science* 13:417-430.

University of Iowa, Office of the State Archaeologist (UI, OSA)
2018 Burial Project 3402. On file, Office of the State Archaeologist, University of Iowa, Iowa City.

A Human Cranium from the Library Archives of Des Moines University, Polk County, Iowa

Jennifer E. Mack

A human cranium with no provenience information was discovered in the Library Archives of Des Moines University in Polk County, Iowa. The cranium was transferred to the OSA Bioarchaeology Program to determine whether or not the remains represented an individual of Native American ancestry. The individual was determined to be a young to middle adult male from an ancestral group not represented in the reference data, and therefore not Native American.

Introduction

In 2019, a forensic anthropologist employed by Des Moines University reported that the university's library archives collections included a human cranium which she believed might be Native American. On May 4, 2019, the cranium was transferred to the OSA Bioarchaeology Program for evaluation of ancestry and NAGPRA processing, if appropriate (UI, OSA 2019). Des Moines University has no information concerning the provenience of the human remains or how the cranium came to be stored in the library archives. A small tag attached to the zygomatic reads "ARC 00658."

Osteological Analysis

The remains consist of a complete cranium missing the mandible and several maxillary teeth. The cranium is in excellent condition, though some type of lacquer or preservative was applied in the past, giving the ectocranial surface a polished, mahogany-colored finish. Portions of the bone without this application (the cranial base, the nasal cavity, etc.) are dark in color, rather than the white or ivory expected from bones prepared as anatomical specimens from fresh cadavers. This coloring, along with speckled staining on the endocranial surface, suggests the remains originated from a burial/mortuary context, though no soil was present on the cranium aside from an accumulation of dust and cobwebs inside the cranial vault.

Two sexually dimorphic features of the skull—large mastoid processes and the prominence of glabella—suggest the individual was male, though the nuchal crest and supraorbital margins have intermediate morphology, and the mental eminence is not present. Cranial suture closure provides a broad age range of approximately 30 to 60 years. The small amount of dentin exposure and the antemortem loss of only one tooth suggests the individual was likely at the lower end of the range, a young to middle adult. However, since dental attrition rates are population specific, and this individual's origin is unknown, the age range cannot be determined with certainty.

The morphological features of the skull are not particularly suggestive of Native American ancestry. The palate is somewhere between parabolic and elliptical. The zygomatics project very slightly. The inferior three-quarters of the nasal bones were lost postmortem, but the root is narrow and relatively low. The nasal spine is broken off and the lower nasal border is unobservable on the right side, while slight guttering is visible on the left. The nasal aperture is relatively narrow. No wormian bones are present.

Cranial measurements (Table 1) were entered into the FORDISC computer program and compared with those of numerous reference populations. Ancestry could not be identified, but the results appear to exclude Native American ancestry. When all groups were included (both from the Forensic Data Bank and Howells' data), Native American groups were ranked at or near the bottom of the lists, having the greatest distance from the unknown individual. Regardless of the options chosen for stepwise selection of measurements, the results consistently showed the unknown individual as closest to Whites or one of Howells' European groups. However, the typicality probabilities were not significant, i.e. the individual was closest to Whites, but did not have measurements close to the group mean. From these results, it was concluded that European ancestry was unlikely for this individual. When American Whites and Europeans were removed from the comparison list and the data were processed again, the unknown individual was found to be closest to Black males, North Japanese males, or Hispanic males, depending on the stepwise method selected and the comparative dataset used. The cross-validation rates for these calculations were low (<70%) and the typicality figures were not significant. The closest ancestry assignment was attained by using Howell's data and eliminating both European and African groups from the calculations. The individual was found closest to North Japanese males, with a cross-validation rate of 70.4%, posterior probability of 0.832, and a chi typicality of 0.049. However, the distance from the centroid for North Japanese is quite large (37.8) and is not significantly smaller than the four groups ranked immediately below. These poor results suggest that the individual belongs to a group not represented in the reference data. Given the somewhat elliptical palate shape, it is likely that the individual belongs to an Asian group, perhaps from the South Asian region (including India, Pakistan, Bangladesh, Sri Lanka, Nepal, Bhutan, Maldives, or Afghanistan), as these populations are not included in Howells' data or the Forensic Data Bank.

Eight maxillary teeth are present in the alveolus and seven were lost postmortem (see Tables 2 and 3 for inventory and metrics). The maxillary right third molar was lost antemortem. This loss occurred close to the time of death, as the socket had not begun to heal. Recession of the alveolus on the buccal surface of the socket, which also affected the adjacent second molar socket, suggests an abscess. No carious lesions were observed on the teeth present. Very slight calculus was observed on the buccal and lingual surfaces of all eight teeth. Enamel hypoplasias in the form of two horizontal grooves were observed on the only anterior tooth present, the maxillary left canine. As the apical half of the canine crown was lost postmortem, it is possible that additional hypoplasias were originally present. The two grooves observed are located 2.7 mm and 3.8 mm from the cemento-enamel junction, respectively. This individual exhibits Carabelli's cusps on both maxillary first molars (without free apices) and parastyles on the both second molars and the left third molar.

The cranium exhibits a fairly severe but well-healed depression fracture on the right parietal, tangent to the sagittal suture, approximately midway between bregma and lambda. The oval-shaped defect, which measures 13 mm anteroposteriorly and 15 mm transversely, has a sharp anterior margin indicating that the outer table of bone fractured and was compressed into the diploë. The posterior margin of the depression is rounded and less clearly defined. Because the cranial vault is complete, it is difficult to visualize the endocranial surface. However, the endocranial surface appears to be irregular at this location, exhibiting at least two depressions. The margins of the endocranial depressions are indistinct except for a lip of bone along the medial margin of one depression, corresponding to the location of the sagittal suture. On the ectocranial surface, four very small (<1 mm) finger-like extensions of bone are present along the healed anterior fracture margin. Slight porosity is visible along the sagittal suture on the right parietal. The pores are more numerous and widely spread on the left parietal, with concentrations along the sagittal suture and the posterior half of the parietal, extending laterally to the superior temporal line. This porosity may represent well-healed periosteal reaction to soft tissue inflammation or infection associated with the fracture, but observations are hampered by the application of lacquer/preservative. A second, smaller and shallower

defect is present on the left parietal immediately superior to the superior temporal line, on the posterior half of the parietal. This circular defect has a diameter of 10.2 mm and can be visualized primarily using oblique lighting. The floor of the defect has a slightly rougher texture than the surrounding bone. The defect may be a second depression fracture or may simply be post-mortem damage masked by the application of lacquer.

Summary

A young to middle adult male is represented by the cranium found in the library archives of Des Moines University in 2019. Dental health was good, except for the antemortem loss of one third molar due to abscess. The individual suffered a traumatic injury to the right parietal, but the fracture was well healed at the time of death. Facial morphology and cranial metrics indicate this individual is not Native American. Ancestry could not be determined, but results obtained from the FORDISC computer program suggest the individual originated from a group not represented by the reference samples. The elliptical palate shape suggests the individual belongs to an Asian group, perhaps from the South Asian region—India, Pakistan, Bangladesh, Sri Lanka, Nepal, Bhutan, Maldives, and Afghanistan—which is not represented in Howells' data or the Forensic Data Bank. Since the nineteenth century, India has been one of the world's leading sources of human bone specimens for medical study (Cumback 2018). The presence of a cranium from India in the collections of a medical school like Des Moines University, which was founded in 1898, would not be unusual.

References Cited

Cumback, Kylie
2018 A Bone to Pick with International Law: The Ghoulish Trade in Human Remains. *Michigan State International Law Review* 26(2):335-371.

University of Iowa, Office of the State Archaeologist (UI, OSA)
2019 Burial Project 3432. On file, Office of the State Archaeologist, University of Iowa, Iowa City.

Table 1. Cranial Metrics (mm) Burial Project 3432, Des Moines University cranium

Cranial metric	Individual 1
Maximum cranial length	184
Maximum cranial breadth	144
Bizygomatic diameter	127
Basion-bregma height	132
Cranial base length	103
Basion-prosthion length	96*
Maxillo-Alveolar breadth	62
Maxillo-Alveolar length	52*
Biauricular breadth	118
Upper facial height	71*
Minimum frontal breadth	100
Upper facial breadth	107.5
Nasal height	52
Nasal breadth	23
Orbital breadth L	41
Orbital breadth R	41
Orbital height L	34
Orbital height R	35
Biorbital breadth	101.5
Interorbital breadth	26
Frontal chord	115
Parietal chord	105
Occipital chord	99
Foramen magnum length	36
Foramen magnum breadth	31
Mastoid length L	27
Mastoid length R	25
*Indicates estimated measurement	

Table 2. Dental Inventory, Burial Project 3432, Des Moines University cranium

Tooth	Presence	Attrition:	Attrition- molars:			
		I, C, P	Mes-buc	Mes-ling	Dis-ling	Dis-buc
MAXILLA:						
RM3	4		0	0	0	0
RM2	2		2	3	3	2
RM1	2		3	5	4	3
RP2	5					
RP1	5					
RC	5					
RI2	5					
RI1	5					
LM3	2		1	2	2	1
LM2	2		2	2	2	2
LM1	2		5	5	0	5
LP2	2	2				
LP1	2	2				
LC	7	9				
LI2	5					
LI1	5					

Dental Inventory Key:

Presence

1 Present but not in occlusion
2 Present, development completed, in occlusion
3 Missing, with no associated alveolar bone
4 Missing, with alveolus resorbing or fully resorbed: antemortem loss
5 Missing, with no alveolar resorption: postmortem loss
6 Missing, congenital absence
7 Present, damage renders measurements impossible
8 Present but unobservable (e.g. teeth in crypts)
9 Unobservable

Attrition (I, C, PM)

1 Unworn or small facets
2 Point or hairline of dentin
3 Dentin line of distinct thickness
4 Moderate dentin exposure, not resembling a line
5 Large dentin area with rim complete (two areas on premolars)
6 Large dentin area with enamel rim lost on one side (two areas coalesced on premolars)
7 Enamel rim lost on two sides (at least one side lost on premolars)
8 Complete loss of crown, no enamel remaining
9 Unobservable

Attrition (molars)

0 Unobservable
1 Wear facets invisible or very small
2 Wear facets large, but cusps and surface features still evident
3 Any cusp in quadrant is rounded, but not flat
4 Quadrant is worn flat, but no dentin is exposed (except pinprick-sized)
5 Quadrant is flat, dentin exposed on ¼ of quadrant
6 More than ¼ of dentin is exposed, with enamel ring still complete
7 Enamel is found on only two sides of quadrant
8 Enamel on only one side of quadrant, but enamel is still thick
9 Enamel on only one side of quadrant and it is very thin
10 No enamel remaining. Wear extends below the cervicoenamel junction onto the root

Table 3. Dental Metrics (mm), Burial Project 3432, Des Moines University cranium

Tooth	Mesiodistal	Buccolingual	CEJ mesiodistal	CEJ buccolingual
MAXILLA:				
RM2	9.4	12.0	8.1	10.2
RM1	12.0	11.9	9.9	11.9
LM3	9.0	10.7	7.9	11.2
LM2	9.3	11.3		11.2
LM1		11.9		11.7
LP2	6.2	9.8		9.0
LP1	5.6	8.5		8.3

Human Skeletal Remains from Unknown Archaeological Context, Donated by Sidney High School, Fremont County, Iowa

Jennifer E. Mack

Human remains from an unknown buried context were transferred to the Office of the State Archaeologist from Sidney High School in Fremont County, Iowa. At least one individual, a young or middle adult of unknown sex, is represented. The few observable morphological features suggest Native American ancestry.

Introduction

In June 2019, the University of Iowa Office of the State Archaeologist Bioarchaeology Program accepted the transfer of two boxes of human remains from Sidney High School in Fremont County, Iowa. The remains had previously been part of the school's teaching collection, though the administration could find no information regarding the origin or acquisition of the collection. Most of the materials were prepared anatomical specimens (UI, OSA 2019a). However, the condition of two elements indicates that they originated from an archaeological context (UI, OSA 2019b).

Osteological Analysis

The human remains consist of a fairly complete maxilla (right and left halves with articulating nasal bones) and a second or third lumbar vertebra. Both elements are grayish-beige in color with traces of adhering soil remaining, and both have sustained postmortem damage. The edges of the transverse and articular processes of the vertebra have broken off, exposing trabecular bone, and the cortex of the anterior surface of the centrum has eroded postmortem. The maxillary portion has broken away from a cranium, with fracture edges on the zygomatic processes; separation from the palatines and frontal occurred along open suture lines. Damage resembling chopping marks on the inferior margins of the orbits and the left margin of the nasal aperture has the same coloring as the undamaged cortex but does not appear to be perimortem. The fracture angles are sharp, suggesting the damage occurred in the postmortem period, though not recently enough to have different coloring (i.e., not during excavation or in the lab).

The color and condition of the two elements is very similar, suggesting that they may have originated from the same location. Whether the two elements represent a single individual could not be determined. Overall size, age, and preservation are consistent. The MNI is one, as there is no evidence to prove or exclude association of the two elements.

Sex cannot be determined for the individual from the observable cranial features. Age appears to be adult. The incisive suture is obliterated, and the anterior median palatine suture is completely closed and almost obliterated. However, the nasofrontal, nasomaxillary, and maxillo-frontal sutures were largely open at the time of death, and none of the observable alveolar sockets were resorbed, suggesting this was a young or middle adult, rather than an old adult.

Ancestry cannot be determined with certainty from the remains present. However, morphological features suggest possible Native American ancestry. The maxillary palate is rounded and broad. The nasal aperture is moderately wide, with a sharp, flat lower border (no sill). The nasal root is narrow, but the overall nasal area is tented (Asian) rather than steepled (European).

No dental remains are present, as the maxillary incisors, canines, premolars, and first molars were all lost postmortem, and the alveolar sockets for the second and third molars are absent. Little pathology was observed on these remains. A strong left lateral bend in the anterior area of articulation for vomer suggests a possible deviated septum. Very slight lipping was observed on the superior and inferior articular processes of the vertebra.

Summary

At least one individual is represented by the remains removed from an unknown burial context. Sex cannot be determined, but the individual was an adult and displays some morphological features consistent with Native American ancestry. The donation of incidentally discovered ancient human remains to local museums and educational institutions was common in Iowa in the nineteenth and twentieth centuries. Therefore, the remains from Sidney High School may represent a Native American buried in Iowa.

References Cited

University of Iowa, Office of the State Archaeologist (UI, OSA)

2019a Burial Project 3435. On file, Office of the State Archaeologist, University of Iowa, Iowa City.

2019b Burial Project 3445. On file, Office of the State Archaeologist, University of Iowa, Iowa City.

Fragmentary Human Skeletal Remains from Richardson and Nance Counties, Nebraska

Jennifer E. Mack

Fragmentary cranial remains recovered by a private collector from sites in two counties in Nebraska (Richardson and Nance Counties) represent a minimum of two adult individuals. The remains were stored with artifacts from precontact Native American sites, and bone preservation is consistent with that of ancient Native American remains. Age and sex are indeterminate, though one individual was likely a middle or old adult.

Introduction

A private citizen who collected artifacts from Native American sites in Nebraska also recovered human remains from unknown locations in or near Rulo, Richardson County, and Genoa, Nance County, Nebraska. After the citizen's death, his collection passed to an avocational archaeologist in Iowa, who recognized the human elements and notified the University of Iowa Office of the State Archaeologist Bioarchaeology Program (OSA-BP). The remains were transferred to the OSA-BP on August 12, 2019 (UI, OSA 2019). Though the provenience of the remains is unknown, they are believed to represent ancient Native Americans, based on the artifacts that were stored with the human bones.

Osteological Analysis

The remains from the vicinity of Rulo consist of a single maxillary fragment. The individual is represented by the left maxillary alveolus with the left lower border of the nasal aperture and part of the left half of the maxillary palate present. Alveolar sockets for the left central incisor through the left third molar are present, but all of these teeth were lost postmortem. Purple staining on the buccal surface of the alveolus and on the surface of the palate likely relates to fungal activity (Cole and Waldron 2016). Full eruption of the third molar indicates the individual had reached adulthood, but age cannot be determined any more precisely. Sex is indeterminate.

The remains from vicinity of Genoa consist of three cranial fragments including a nearly complete right orbital margin; a cranial vault section consisting of incomplete left and right parietals and a small portion of frontal; and an unsided parietal fragment. The smaller parietal fragment appears inconsistent with the joined parietals as it has much thinner cortical bone. However, the endocranial surface of this smaller fragment has experienced greater weathering, so it is possible that the dissimilar appearance is due to different preservation. The zygomatic process of the right orbit is unfused, while the joined parietals are fully fused and the portion of coronial suture present is almost obliterated. This more advanced stage of cranial fusion suggests the presence of a middle or old adult. The supraorbital margin is relatively sharp, but sex cannot be determined from a single feature.

The cranial vault section exhibits abnormal or pathological bone in the form of possible apposition combined with resorption. The cortical bone of both the endocranial and ectocranial surfaces appears thick (1.1 mm) and dense, particularly on the freshly broken posterior edges of the parietals. It is possible that

this thickness falls within the normal range of human variation. The accompanying antemortem bone loss is more pronounced. The diploe appears narrow, with most of the calvaria measuring between 4.8 and 5.7 mm in width, including both cortical and trabecular bone. Vessel impressions on the endocranial surface have perforated the cortex, revealing channel-like voids in the diploe which are wider at the base than on the endocranial surface. The profile of one such channel is visible in the posterior broken edge of the left parietal fragment, measuring 66 mm long. The maximum depth of the void is 2 mm. The width would have been at least 1.5 mm, but cannot be measured due to the missing portion of parietal. Additionally, large, deep pores are present on the endocranial surface along the sagittal crest, the largest measuring 2.1 mm in diameter. The left parietal foramina is patent, penetrating through the inner table of bone. The etiology of these bone changes is unknown, but the bone loss may suggest some type of marrow hypoplasia.

The preservation and condition of the remains appears consistent with archaeologically recovered bone from historic and prehistoric sites.

Summary

Based on two separate proveniences—near Rulo and Genoa, Nebraska—the human remains transferred to the OSA from a private collection represent a minimum of two individuals. Dental eruption and cranial suture closure indicate that at least two of the fragments represent adults, including one middle or old adult. Sex is indeterminate for these individuals. One cranial vault portion exhibits resorption of the diploe and possible thickening of the cortex. Though the precise recovery locations are unknown, the remains are believed to represent ancient Native Americans based on the artifacts that were stored with the human bones. Preservation of the remains is consistent with bone recovered from archaeological sites.

References Cited

Cole, Garrard and Tony Waldron
2016 Purple Staining of Archaeological Human Bone: An Investigation of Probable Cause and Implications for Other Tissues and Artifacts. *Journal of Anthropology* 2016:1-11.

University of Iowa, Office of the State Archaeologist (UI, OSA)
2019 Burial Project 3451. On file, Office of the State Archaeologist, University of Iowa, Iowa City.

A Human Femoral Fragment from St. Augustine, Florida

Jennifer E. Mack

An isolated femoral fragment from a teaching collection at Sidney High School, Fremont County, Iowa, represents an adult of unknown age and sex. Labeling on the element indicates that it originated from an archaeological context in St. Augustine, Florida, and that the represented individual was European.

In June 2019, the University of Iowa Office of the State Archaeologist Bioarchaeology Program accepted the transfer of two boxes of human remains from Sidney High School in Fremont County, Iowa. The remains had previously been part of the school's teaching collection, though the administration could find no information regarding the origin or acquisition of the collection. Most of the materials were prepared anatomical specimens (UI, OSA 2019a). However, the condition of one femoral fragment indicates that it originated from an archaeological context (UI, OSA 2019b).

The surface of the element is heavily damaged, with most of the cortex taphonomically eroded off the femoral head and the posterior surface. The remaining cortex on the neck and anterior surface of the proximal femur is chalky. On the posterior surface of the neck, hand-printed in ink, is the following inscription: "Hip bone of/ Spaniard/___ up at/ St. Augustine/ Fla./ ___ __/ About/ 1600." The orientation of the writing is upside-down, relative to anatomical position.

The portion of left femur present includes the head, the neck, and the area of the trochanters. Most of the greater trochanter has broken off, and the lesser trochanter is absent, along with the rest of the cortical bone on the posterior surface. Based on size and the fusion of the femoral head, this individual appears to be an adult, though the element is somewhat gracile.

References Cited

University of Iowa, Office of the State Archaeologist (UI, OSA)

2019a Burial Project 3435. On file, Office of the State Archaeologist, University of Iowa, Iowa City.

2019b Burial Project 3444. On file, Office of the State Archaeologist, University of Iowa, Iowa City.

Two Anatomical Specimens from Norway, Benton County, Iowa

Jennifer E. Mack

Two crania transferred to the Office of the State Archaeologist by a private citizen appear to be prepared anatomical specimens. One young adult female of African ancestry and one possibly female middle adult are represented by the remains. Though a previous owner of the collection lived in Norway, Benton County, Iowa, the origin of the remains is unknown.

Introduction

In May 2020, a private citizen in Minnesota transferred two sets of cranial remains to the Office of the State Archaeologist (OSA). The remains had belonged to a relative who was previously a teacher at the Norway Union Street High School in Norway, Benton County, Iowa. A student at the high school gave the remains to the teacher some time in the 1970s. No other information is available concerning the origin of the human remains (UI, OSA 2020).

Osteological Analysis

CRANIUM 1

Cranium 1 consists of the cranial vault only. The facial skeleton is represented only by the supraorbital margins. Both temporals are absent. The only portion of the sphenoid present is the superoposterior corner of the right greater wing, which is attached to the right parietal. The basilar portion of the occipital is absent, except for the posterior margin of the foramen magnum; this portion is missing due to both recent and older postmortem fracturing.

An aborted saw mark and at least five false starts/blade skips are present in the left temple area of the frontal, with the deepest saw mark crossing the temporal line. This saw mark does not fully perforate the cranial vault. Based on the coloring of the edges, the cutting occurred around the same time that the cranium was initially processed. Though no other clear signs of anatomization are present, the cranium appears to be a prepared anatomical specimen rather than remains removed from a buried context. This origin is evidenced by the lack of dirt in the frontal sinuses and endocranial vessel impressions, lack of root etching, the ivory coloring of the endocranial surface, and the smooth, dense texture of the ectocranial surface. Some endocranial staining on the occipital and the orbits, in both dark brown and white, has a rougher, chalky texture, which may be related to chemical damage during the cleaning process.

Based on the smooth glabella and sharp orbital margins, the individual may be female. The nuchal crest is somewhat pronounced, but this feature may be related to the presence of an Inca bone and associated occipital bunning. Cranial suture closure of the vault suggests an age of 28 to 44 years (middle adult).

Ancestry estimation was attempted using FORDISC discriminant function software, but too few cranial measurements were possible for a reliable result. For cranial metrics, see Table 1.

Capillary impressions are visible in the superolateral corners of both orbits. These impressions are small and likely normal variation, rather than pathological, as they do not resemble the porosity of healed cribra orbitalia. Their appearance is made more visible by the aforementioned staining.

Nonmetric features of note include epipteric and asterionic bones on the right side, a large ossicle at bregma, and an Inca bone with an open transverse suture and occipital bunning.

CRANIUM 2

Cranium 2 consists of a complete cranial base and facial skeleton, with most of the cranial vault absent. The superior portions of the frontal and occipital, and most of the parietals were removed with a circumferential saw cut. The inexpert cut angles more inferiorly on the left side than on the right. At the occipital, just superior to the cruciform eminence, the saw did not fully perforate the cranial vault, and when the calotte was removed, a spall of endocranial bone was left projecting superiorly from the saw cut. The coloring of the saw-cut bone is the same as the rest of the bone surface, indicating that the cranium was cut at the time of the initial cleaning and processing. The ectocranial and endocranial cortical surfaces are smooth and dense, though there are a few white spots with rougher texture, as with Cranium 1, which might be related to cleaning damage. No soil is present, indicating this cranium is also an anatomical specimen.

All observable features indicate female sex. The nuchal crest and glabella both appear smooth, the mastoid processes are small, and the orbital margins are sharp. The individual appears to be a young adult. The maxillary left third molar had erupted by the time of death, but all of the observable cranial sutures were largely open endocranially as well as ectocranially. The small portion of left parietal present is loose along the temporal suture. The incisive suture of the palate shows significant closure but is still visible.

Observable facial morphology indicates African ancestry. The nasal root is low and rounded, the nasal bridge is low, the nasal spine is small, the aperture is wide, and the lower border is guttered. The maxilla appears prognathic. Damage to the alveolus makes it difficult to determine, but the maxillary palate appears more rounded than hyperbolic.

In this case, it was possible to estimate ancestry using the FORDISC program, as many cranial measurements were collected (Table 1). When these measurements were compared against those of Black and White females in the Forensic Data Bank (using stepwise forward Wilk's variable selection), the individual was found to be closest to Black females, with a cross-validation rate of 89.2% and posterior probability of 1.0, though the typicality probabilities were low. When the measurements were compared with Howell's data for nineteenth century Black and White males and females, the individual was again found to be closest to Black females, with a cross-validation rate of 70.2% and a posterior probability of 0.718. Again, typicality probabilities were relatively low (0.340-0.309), suggesting this individual's cranial proportions are not typical when compared with others in this demographic.

No pathology was observed other than possible evidence of infection in the maxilla. The right second molar appears to have been lost antemortem, as active woven bone is present in the alveolar socket and there appears to be some antemortem bone loss on the buccal surface of the alveolus. The left second molar may also have been lost antemortem, but postmortem damage to the alveolus makes it difficult to be certain.

Nonmetric features of note include infraorbital sutures (bilateral), multiple infraorbital foramina on the left side, accessory palatine foramina (bilateral), and flexure of the superior sagittal sulcus to the left.

Summary

Both of the crania transferred to the OSA in May 2020 are prepared anatomical specimens representing adult females. Cranium 1 was a middle adult of unknown ancestry, while Cranium 2 was a young adult of African ancestry. No further information can be determined concerning the origins of these individuals.

References Cited

University of Iowa, Office of the State Archaeologist (UI, OSA)
2020 Burial Project 3504. On file, Office of the State Archaeologist, University of Iowa, Iowa City.

Table 1. Cranial Metrics (mm), Burial Project 3504, Crania 1 and 2

Cranial metric	Cranium 1	Cranium 2
Maximum cranial length	192	
Cranial base length		93
Basion-prosthion length		104
Maxillo-Alveolar breadth		60
Maxillo-Alveolar length		57
Biauricular breadth		121
Upper facial height		67
Minimum frontal breadth	95	94
Upper facial breadth	104	104
Nasal height		46
Nasal breadth		27
Orbital breadth L		37
Orbital breadth R		37
Orbital height L		32.5
Orbital height R		32.5
Biorbital breadth		95
Interorbital breadth		27
Frontal chord	114	
Parietal chord	114	
Occipital chord	107	
Foramen magnum length		36
Foramen magnum breadth		28
Mastoid length L		21
Mastoid length R		23

Cranial Remains of a Purported Homicide Victim from Newton, Jasper County, Iowa

Jennifer E. Mack

Incomplete cranial remains purportedly belonging to an early twentieth century homicide victim were transferred to the OSA in 2021. These remains do not exhibit evidence of biological affinity or trauma matching the victim, David Jones. A middle-aged male of likely European ancestry is represented by the cranium, which was dissected and preserved as an anatomical specimen.

Introduction

In January 2021, the Sanford Museum in Cherokee, Cherokee County, Iowa, transferred to the OSA human cranial remains that purportedly belonged to a homicide victim. The remains were donated to the museum in 1973 by a doctor who was originally from the town of Newton, Jasper County, Iowa, and later relocated to Cherokee. At the time of donation, the doctor stated that the remains belonged to an African American man known as "Red Hos" Jones, who had been killed by a bullet in the head outside a bar in Newton sometime around 1922. The body had been sent to the University of Iowa's Department of Anatomy for examination. The doctor claimed that he had prepared the skull and testified at the trial, then kept the remains for comparative study. Though the doctor was deceased by the time the remains were transferred to the OSA, the museum director who originally accepted the donation, Duane Anderson, confirmed that the cranium sent to the OSA was in fact the cranium donated by the doctor (UI, OSA 2021).

Though some details provided by the doctor were incorrect, records concerning the death of David "Red Horse" Jones were located. Jones was killed on November 8, 1919, around 11:15 pm in the cook shack in the Rock Island freight yard in Newton, Iowa. According to witnesses, Jones threatened a man named Owen Watkins with a knife and demanded money. Watkins, an African American barber from Des Moines, claimed he shot Jones in self-defense. Jones had been in town for about two months, working on a paving crew, and had previously lived in Washington state (*Newton Daily News* 1919a). Since Jones had no family in the area, the body went unclaimed. The death certificate, which estimates his age to be around 40 years, confirms that his remains were sent to the "State Medical Department" in Iowa City on November 14, 1919 (UI, OSA 2021). A month later, the Grand Jury determined that the killing had been done in self-defense and no indictment was returned. Watkins was released from jail (*Newton Daily News* 1919b).

The doctor who donated the cranium to the Sanford Museum is not mentioned in any of the historic documents. The physician who attended to Mr. Jones on the scene, W. E. Lyon, stated that "a bullet had entered his head just in front of the left ear." Jones died before medical help arrived (*Newton Daily News* 1919a).

Osteological Analysis

CONDITION OF THE CRANIUM

The cranium transferred to the OSA was clearly cleaned and prepared as an anatomical specimen, rather than originating from a burial context. The intact portions of the ectocranial surface are uniformly a warm grayish beige except for darker brown staining on the frontal and along the sagittal crest, perhaps related to the cleaning process. The cranial base is darker in color due to dust accumulation in storage. This dust is easily removed with a damp brush. The cranium is incomplete, with the right zygomatic and most of the maxilla missing. The mandible is not present. Saw cuts relating to autopsy or dissection are present along with tool marks possibly related to defleshing. Additional postmortem damage appears intentional but not related to normal dissection practices. Postmortem breakage also occurred.

Autopsy/Dissection Evidence

The calotte was removed from the cranium using a type of saw that resulted in the loss of a swath of bone measuring approximately 4 mm wide. This removal appears to have been performed inexpertly, as the cut passes more superiorly on the right side of the cranium than the left and there are places where the saw "jumped," leaving a very slight step. The cut edges appear slightly polished and striated, and are the same color as the ectocranial surface, indicating the cutting was done at the time the cranium was defleshed and prepared. Striae which are perhaps related to false starts are found both superior and inferior to the cut line circumferentially. However, substantially more striae, of a shallower type with many more parallel lines, are found on the frontal, extending up to 45 mm superior to the cut. The space between individual lines measures 1 mm or less. One line of striae (9 mm wide) extends up midline on the frontal for 65 mm superior to the cut; these incised lines are 3 mm apart. The striae found on the frontal may be the result of the saw skipping off the bone or could be related to defleshing using a serrated tool. These striae are the same color as the rest of the ectocranial surface, and therefore occurred at the time the cranium was prepared.

The inferior-most portion of the right nasal bone may have been broken off during this processing, as the fracture edge exhibits this same coloring. The anterior margin of the left TMJ has some trabecular bone exposed, again with the same coloring. Viewed superiorly, there appears to be a nick or tool mark, again likely related to processing.

Later Postmortem Alterations

The right zygomatic and maxilla appear to have been intentionally removed at a time after the original cleaning and preparation of the cranium, as lighter-colored bone is visible on the cut edge of the zygomatic process of the right temporal, and on the fracture edges of the fragment of right zygomatic still present on the frontozygomatic suture; the fragment of right maxilla present on the frontomaxillary suture; the incomplete left nasal; the styloid processes; and the thin bony plates of the right frontal sinus and vomer. The oblique angle of the frontozygomatic fracture suggests the that the bone may have still been somewhat fresh at the time of breakage. The edges of these fractures do not appear as sharp or light-colored as the more recent damage (described in the Postmortem Breakage below).

Three additional areas of bone removal also display lighter colored bone, but tool marks are visible in these alterations. On the left frontal, close to midline, a section of ectocranial bone has been removed to expose the frontal sinus. This exposure measures 27 mm mediolaterally and 24 mm superoinferiorly. The cut-away area has the shape of an irregular circle and comes within a few millimeters of the frontonasal suture inferiorly and the dissection cut line superiorly. Bone on the superomedial surface of the left orbit was chipped away during this process (an area measuring approximately 23 mm x 15 mm). The medial and superior edges of the frontal defect exhibit polishing and striae, while the lateral edge has a chipped appearance, perhaps from a chiseling action.

Immediately inferior to the infraorbital foramen of the left maxilla, an anterior-facing portion of bone was removed, exposing the maxillary sinus. This removal measures approximately 17 mm mediolaterally. The lateral margin of the defect appears chipped or chiseled. The inferior fracture edge resulting from the removal of the maxillary alveolus, does not exhibit any tool marks.

Similar chipping is also present on the left temporal where the mastoid process was removed, exposing the auditory meatus. The exposed area measures approximately 28 mm anteroposteriorly and 23 mm superoinferiorly. Polishing and chipping are visible on the superior margin of the defect, at the base of the zygomatic process. A few linear cuts are visible in the exposed surface along the posterior margin of the defect. The remainder of the damaged area exhibits no clear tool marks, but the fracture margins are rounded rather than the sharp edges that might result from accidental breakage.

This group of postmortem alterations may have been performed to expose the underlying anatomical features, since the doctor who donated the remains was an otolaryngologist, or for other reasons.

Postmortem Breakage

The calotte exhibits a postmortem fracture running transversely midway between bregma and obelion. The light color and rough texture of the fracture edge suggest recent postmortem breakage. The fracture was easily repaired (glued) by the analyst, but a portion is missing from the posterior portion of the left parietal. This roughly triangular missing portion measures approximately 65 mm anterolaterally-posteromedially and 45 mm superoinferiorly.

SEX, AGE, AND ANCESTRY

Based on morphological features, sex could not be determined. The nuchal crest is present, but not strongly prominent or rugose. The left mastoid is fairly large, but the supraorbital margins are somewhat sharp. The right half of glabella is moderately prominent. Ultimately, the determination that the individual was possibly male relied on discriminant function analysis using FORDISC (below).

Age was determined through cranial suture closure, using only the vault score. All portions for this score were observable except for pterion. Substituting a range of 1-3 (minimal, significant, or complete closure) for the pterion score resulted in a vault score of 16-18, indicating an age range of 35 to 60 years, or middle to old age adult. No dental remains or postcranial elements were present to confirm this age range.

As most of the facial skeleton is missing, determination of ancestry could not rely on morphological features. However, the nasal root is narrow and the bridge is high, both characteristics which are consistent with European ancestry. The cranial vault was reconstructed with putty to fill in the missing 4mm width of bone removed by the saw, and cranial measurements were collected (Table 1). All cranial measurements were entered into FORDISC. When the measurements were compared with twentieth century Black and White males and females in the Forensic Databank (FDB), the individual was found to be closest to White males, with a cross-validation of 68.2% and posterior probability of 0.499. However, the typicality probabilities were not strong (Table 2). In case these results were due to inexpert cranial reconstruction, all measurements that relied on the reconstruction were removed and the comparison was run again. Again, the individual was found to be closest to White males. When all the measurements were run against nineteenth century Black and White males and females from Howells' data, the individual was found to be closest to White males. When this comparison was run without the reconstructed measurements, the results again placed the individual closest to White males. The weak results (low cross-validation rates, moderate typicality) may be due to the amateur cranial reconstruction, the small number of measurements available without reconstruction, and/or possible mixed ancestry.

PATHOLOGY

No pathology was observed. All observed alterations are due to dissection in the early postmortem period, intentional alterations after the bone was cleaned and processed, and accidental breakage of dry bone. No defect was observed that would be consistent with the 1919 newspaper report that Mr. Jones had been shot, and "a bullet had entered his head just in front of the left ear." Consultation with forensic anthropologist Dr. Heather Garvin-Elling (Des Moines University) and Andrew Wilson, F-ABMDI (Iowa Office of the State Medical Examiner) confirmed that no evidence of such perimortem trauma was present.

Summary

The narrative given to the Sanford Museum in 1973 indicated that the donated cranium belonged to an African American murder victim. After the human remains were transferred to the OSA, background research located a precise account of the 1919 incident and the injury inflicted on the deceased. Analysis of the cranial remains found no perimortem trauma matching the described injury. Furthermore, though most of the facial skeleton is missing, discriminant function analysis of the cranial measurements found that the individual's proportions are closer to those of White males than Black males. Therefore, the cranial remains are not those of David "Red Horse" Jones, but of a middle-aged to old adult male of probable European ancestry.

References Cited

Newton Daily News

1919a "'Red Horse" Jones Killed in a Negro Fracas Over Money Saturday Night." 10 November:1. Newton, Iowa.

1919b "Negro Who Shot Jones Turned Loose." 9 December:1. Newton, Iowa.

University of Iowa, Office of the State Archaeologist (UI, OSA)

2021 Burial Project 3556. On file, Office of the State Archaeologist, University of Iowa, Iowa City.

Table 1. Cranial Metrics (mm), Burial Project 3556

Cranial metric	Individual 1	Estimated?
Maximum cranial length	180	yes
Maximum cranial breadth	146	
Basion-bregma height	137	yes
Cranial base length	96	
Minimum frontal breadth	97	
Upper facial breadth	103.5	
Orbital breadth L	40	
Orbital height L	35	
Frontal chord	118	yes
Parietal chord	118	yes
Occipital chord	92	
Foramen magnum length	37	
Foramen magnum breadth	36	

Table 2. FORDISC results, Burial Project 3556

Comparative datasets	Closest to:	Cross-valid. %	Posterior prob.	Typicality F	Typicality Chi	Typicality R
20th cent. Black and White males and females (FDB)	White males	68.2	0.499	0.565	0.547	0.463
20th cent. Black and White males and females (FDB), no estimated measurements	White males	66.5	0.430	0.471	0.459	0.481
19th cent. Black and White males and females (Howells)	White males	60.8	0.638	0.649	0.627	0.720
19th cent. Black and White males and females (Howells), no estimated measurements	White males	58.3	0.578	0.609	0.585	0.660